Library
National Institutes of Health
Bethesda 14, Maryland

.51
4
12, Fasc. 40
9

LIBRARY
JAN 30 1959
NATIONAL INSTITUTES OF HEALTH

TRANSPLANTABLE AND TRANSMISSIBLE TUMORS OF ANIMALS

Harold L. Stewart, M. D.
Katharine C. Snell, M. D.
Lucia J. Dunham, M. D.
Samuel M. Schlyen, M. D.

ARMED FORCES INSTITUTE OF PATHOLOGY

TRANSPLANTABLE AND TRANSMISSIBLE TUMORS OF ANIMALS

Harold L. Stewart, M. D.
Katharine C. Snell, M. D.
Lucia J. Dunham, M. D.
Samuel M. Schlyen, M. D.

ARMED FORCES INSTITUTE OF PATHOLOGY

ATLAS OF TUMOR PATHOLOGY

Section XII—Fascicle 40

TRANSPLANTABLE AND TRANSMISSIBLE TUMORS OF ANIMALS

by

Harold L. Stewart, M. D.
Katharine C. Snell, M. D.
Lucia J. Dunham, M. D.
Samuel M. Schlyen, M. D.

Laboratory of Pathology, National Cancer Institute
National Institutes of Health, Bethesda, Maryland

Published by the
ARMED FORCES INSTITUTE OF PATHOLOGY
Under the Auspices of the
SUBCOMMITTEE ON ONCOLOGY
of the
COMMITTEE ON PATHOLOGY
of the
DIVISION OF MEDICAL SCIENCES
of the
NATIONAL ACADEMY OF SCIENCES—NATIONAL RESEARCH COUNCIL
Washington, D. C.
1959

Accepted for Publication October 1956

For sale by the American Registry of Pathology
Armed Forces Institute of Pathology
Washington 25, D. C. - Price — $3.50

ATLAS OF TUMOR PATHOLOGY

Sponsored and Supported

by

AMERICAN CANCER SOCIETY

ANNA FULLER FUND

ARMED FORCES INSTITUTE OF PATHOLOGY

JANE COFFIN CHILDS MEMORIAL FUND FOR MEDICAL RESEARCH

NATIONAL CANCER INSTITUTE, U.S. PUBLIC HEALTH SERVICE

UNITED STATES VETERANS ADMINISTRATION

ACKNOWLEDGMENTS

Our cooperative effort in preparing this fascicle was generously aided by many investigators in different laboratories throughout the country, and we gratefully acknowledge their help. The names of those who contributed tumor-bearing animals, pathologic material, and data that have been incorporated in specific sections of the manuscript are mentioned in the text and legends.

Others who made major contributions and to whom we are also indebted include several members of the Laboratory of Pathology of the National Cancer Institute. Dr. Thelma B. Dunn, Dr. Ross C. MacCardle, and Dr. Leslie Foulds gave valuable editorial and scientific criticism of the manuscript. Mr. Hoyte N. Deese assisted with the animal inoculations, necropsies, and preservation of pathologic material. Mr. Joseph M. Albrecht and his staff prepared the histologic sections. Mr. Gebhard Gsell took the photographs. A few contributions in these categories that were made by other individuals have been acknowledged in the body of the fascicle. The manuscript was typed by Mrs. Nettie Saeger.

Our thanks are due to Dr. Mary R. Oldt, Dr. Paul E. Steiner, Dr. C. Chester Stock, and Dr. T. C. Jones who acted as special critics, and to Dr. Howard T. Karsner, Dr. Arthur Purdy Stout, Dr. Fred W. Stewart, and Dr. Lauren V. Ackerman, members of the Subcommittee on Oncology of the National Academy of Sciences—National Research Council, who reviewed the manuscript.

Dr. Helen M. Scoville and her associates at the Armed Forces Institute of Pathology gave us excellent editorial assistance.

Harold L. Stewart
Katharine C. Snell
Lucia J. Dunham
Samuel M. Schlyen

TRANSPLANTABLE AND TRANSMISSIBLE TUMORS OF ANIMALS

TABLE OF CONTENTS

	Page No.
INTRODUCTION	11
Historical Review	11
Sources of Transplantable Tumors	16
Technics of Transplantation	19
Results of Transplantation	20
Materials and Methods	23
Contents of Fascicle	24
References	24
TUMORS OF THE SKIN	30
Shope Papilloma. Rabbit	30
Figs. 1–6	
Myxomatosis	32
Fibromatosis	33
References	33
V2 Carcinoma. Rabbit	38
Figs. 7–10	
References	42
TUMORS OF MELANIN-FORMING TISSUE	43
Cloudman Melanoma S91. Mouse	43
Figs. 11–15; Pl. I–A	
Amelanotic Melanoma S91A or C91AA	44
Fig. 16	
References	45
Harding-Passey Melanoma. Mouse	51
Figs. 17–20; Pl. I–B	
References	56
TUMORS OF SUBCUTANEOUS TISSUES	57
Earle L Fibrosarcoma. Mouse	57
Figs. 21–24	
References	62
Myofibrosarcoma HS–6. Hamster	62
Figs. 25–28	
References	65
Liposarcoma D4888. Guinea Pig	65
Figs. 29–36	

TUMORS OF SUBCUTANEOUS TISSUES—Continued Page No.
References 69
Rous Sarcoma. Chicken 74
Figs. 37–42; Pl. II
References 77
TUMORS OF MUSCLE 83
Rhabdomyosarcoma H6668. Mouse 83
Figs. 43–50
TUMORS OF BONE 92
Osteogenic Sarcoma EM2. Mouse 92
Figs. 51–60
References 100
TUMORS OF HEMATOPOIETIC TISSUES 101
Granulocytic Leukemia 101
Chloroleukemia 123, Shay. Rat 101
Figs. 61–66
References 103
Lymphocytic Leukemia 103
Leukemia Line I (MacDowell). Mouse 103
Figs. 67–75
References 113
Murphy-Sturm Lymphosarcoma. Rat 113
Figs. 76, 77
References 121
Lymphoid Tumor RPL–16. Chicken 121
Figs. 78–81
Lymphomatosis 126
References 130
Reticulum-cell Sarcoma 131
Reticulum-cell Sarcoma 8469. Mouse 131
Figs. 82–89
References 133
TUMORS OF THE LUNG 139
Pulmonary Adenocarcinoma C4461. Mouse 139
Figs. 90–93
References 142
TUMORS OF THE ALIMENTARY TRACT 143
Tumors of the Salivary Glands 143
Myoepithelioma HD. Mouse 143
Figs. 94–104
References 145

TUMORS OF THE ALIMENTARY TRACT—Continued
Tumors of the Salivary Glands—Continued — Page No.
Parotid Gland Tumor L7205. Mouse 145
Figs. 105–114
References 160
Tumors of the Forestomach 161
Squamous-cell Carcinoma G8755. Mouse 161
Figs. 115–120
References 166
Tumors of the Glandular Stomach 167
Gastric Adenocarcinoma 303. Mouse 167
Figs. 121–124
References 171
Gastric Adenocarcinoma 328. Mouse 171
Figs. 125–133
References 178
Gastric Carcinoma 342. Rat 179
Figs. 134–140
References 186
Osteogenic Sarcoma 344. Rat 187
Figs. 141–157
References 189
Tumors of the Liver 200
Hepatoma 98/15. Mouse 200
Figs. 158–163
Transplantation of Other Hepatomas 206
References 206
TUMORS OF THE KIDNEY 208
Renal Adenocarcinoma. Frog 208
Figs. 164–169; Pl. III
Virus Etiology and Transplantation Studies 209
References 212
TUMORS OF THE REPRODUCTIVE ORGANS 218
Tumors of the Testis 218
Leydig-cell Tumor (Furth). Mouse 218
Figs. 170–173
References 222
Tumors of the Ovary 222
Granulosa-cell Tumor XIV. Mouse 222
Figs. 174–177
References 223
Luteoma IX. Mouse 226
Figs. 178, 179
References 227

TUMORS OF THE REPRODUCTIVE ORGANS—Continued
Tumors of the Ovary—Continued — Page No.
Teratoma E6496. Mouse 230
Figs. 180–183
References 237
TUMORS OF THE MAMMARY GLAND 238
Mammary Adenocarcinoma C3HBA. Mouse 238
Figs. 184–186
References 239
Bashford Carcinoma 63. Mouse 239
Figs. 187–189
References 243
Sarcoma 37. Mouse 243
Figs. 190–194
Technic of Transplantation 247
References 248
Mammary Fibroadenoma R2737. Rat 249
Figs. 195–200
Characteristics of Mammary Fibroadenomas 254
References 255
Mammary Adenocarcinoma R2426. Rat 260
Figs. 201–203
References 261
Walker Carcinosarcoma 256. Rat 261
Fig. 204
Carcinomatous Variant 265
Figs. 205–207
Sarcomatous Variant 265
Figs. 208, 209
References 271
TUMORS OF THE ENDOCRINE GLANDS 272
Tumors of the Adrenal Glands 272
Adrenal Cortical Carcinoma WK1546. Mouse 272
Figs. 210–215
Adrenal Gland Tumors and Castration 274
References 275
Tumors of the Pituitary Gland 275
Furth Pituitary Tumor. Mouse 275
Figs. 216–224; Pl. IV
References 285
Tumors of the Thyroid Gland 293
Carcinoma #1. Dog 293
Figs. 225–230
References 300

Page No.

TUMORS OF THE BLOOD VASCULAR SYSTEM 301
Hemangioendothelioma H6221. Mouse 301
Figs. 231–236
References 303
TUMORS OF NEURAL TISSUE 308
Tumors of the Brain 308
Astrocytoma C3H(18). Mouse 308
Figs. 237–240
References 309
Ependymoma A(22). Mouse 312
Figs. 241–244
References 316
TUMORS OF UNDETERMINED SITE OF ORIGIN AND UNDIFFERENTIATED HISTOLOGIC PATTERN 317
Ehrlich Tumor (Solid and Ascites Forms). Mouse 317
Figs. 245–248
References 321
Crocker Tumor 180. Mouse 324
Figs. 249–252
References 325
Krebs 2 Tumor (Solid and Ascites Forms). Mouse 330
Figs. 253–258
References 336
Tumor C–1300. Mouse 336
Figs. 259–262
References 340
Flexner-Jobling Carcinosarcoma. Rat 341
Figs. 263–268
References 343
Jensen Sarcoma. Rat 348
Figs. 269–271
References 349
Yoshida Tumor (Solid and Ascites Forms). Rat 352
Figs. 272–276
References 355
Brown-Pearce Tumor. Rabbit 355
Figs. 277–280
References 361
Venereal Tumor. Dog 364
Figs. 281–287
References 368

Page No.

SUPPLEMENTARY CLASSIFICATIONS 374

Classification of Tumors of Animals According to Site of Origin and Histology 374

Classification of Tumors According to Animal Host 377

TRANSPLANTABLE AND TRANSMISSIBLE TUMORS OF ANIMALS

INTRODUCTION

Historical Review

Nearly two hundred years ago, in 1773, Peyrilhe performed perhaps the first experiment on the transplantation of tumors, "To form such inquiries on the causes of cancerous virus, as may lead us to ascertain its nature and effects, and the best methods of obviating it" (Preface, p. III). He injected material from the cancerous lesion of a human breast by syringe under the skin of a dog. Five days after the injection, "The whole skin, from the head to the tail, was completely emphysematous:—A little ichorous, blackish matter flowed from the wound.—The eyes of the animal were vivid, and he seemed to have great thirst: in this state the poor creature was perpetually howling . . . At length my maid, disgusted by the stench of the ulcer, and softened by the cries of the animal, put an end to his life, and thus prevented my observing the ultimate effects of this disease" (p. 46).

Many other attempts were made to transplant tumors from man to animals, but they consistently failed. Leidy, in 1851, transplanted human tumors under the skin of frogs. The grafts became vascularized and in one case tumor cells persisted at the site of inoculation, but no progressively growing tumors developed. A long period of time was to elapse between these early experiments on heterologous transplantation of human cancer and those of more recent date, in which human cancer has been successfully transplanted into laboratory animals. Peyrilhe would have been less discouraged over the outcome of his abortive attempt to transplant human cancer could he have foreseen the difficult problems his successors had to overcome in searching for our present knowledge of the transplantability of tumors.

The acquisition of knowledge of the histologic appearance of various malignant tumors in man, begun by Schwann and by Müller in the eighteen thirties and greatly advanced by the application of Virchow's principles of cellular pathology, gradually replaced the theory of humoral pathology that had dominated medicine for many centuries. Upon this new foundation was built the concept that small emboli are carried in lymph and blood vessels from the site of the primary cancer to distant organs, where they lodge and form metastatic tumors having the same histologic pattern as the primary tumor. The fact that cancer cells can be transferred from one site to another and then proliferate to form a tumor at the new site was made clearer by Cornil, who in 1891 described the successful experimental autotransplantation of human cancer from one breast to the other.

Advance beyond this point depended upon the recognition, of fundamental importance to the experimental study of cancer, that tumors occur in animals. Until 1858, when Leblanc called attention to the frequent occurrence of tumors in domestic animals, it was widely believed that cancer is a disease peculiar to man. Leblanc reviewed and appraised case reports of tumors in the horse, mule, donkey, cow, dog, cat, and pig and emphasized the importance of histologic examination in the diagnosis of tumors. McFadyean, in 1890, and Sticker, in 1902, published extensive data on tumors in animals. About this time the British Imperial Cancer Research Fund began an investigation of the distribution of tumors in the animal kingdom, and by 1904 Bashford and Murray could state definitely that cancer occurs in wild as well as in domestic animals. They believed that the disease in animals was essentially the same as it is in man and would probably be found to occur throughout the vertebrate phyla.

Attempts at transplantation concerned first spontaneous and then deliberately induced tumors of animals. Nowinsky, in 1876, described the transplantation of the venereal tumor of the dog. In nature, this tumor is passed from animal to animal during copulation, apparently by the implantation of tumor cells. It is the only instance outside the laboratory in which tumor cells are known to be passed from one animal to another.

In 1889 Hanau transplanted a squamous cell carcinoma from the region of the vulva of an old rat into other old rats of the same stock and carried the tumor for 2 transplant generations. He expressed the opinion that he had transplanted proliferating cells and not an infectious lesion. Von Eiselsberg, in 1890, and Firket, in 1892, were able to transplant sarcomas of the rat. In 1894 Morau carried a spontaneous mammary tumor of a mouse through several transplant generations, and in some cases he used hosts obtained by brother to sister matings. These transplantations received little notice. A review by Sailer, in 1900, lists some successes and many failures in the transplantation of tumors within animal species. Microscopic confirmation of the diagnosis of tumor was lacking in many cases, and uncertainty persisted as to whether cells or an infectious agent, variously suspected of being an animal parasite, a bacterium, or a mold, was transferred and gave rise to the new tumor. However, during the years 1901 to 1907, Loeb, Jensen, Borrel, Bashford and Murray, and Flexner and Jobling, made histologic studies and supplied convincing evidence that the transplantation of a tumor in experimental animals is dependent upon the continued multiplication of neoplastic cells from the original tumor. They demonstrated that tumor cells may reproduce indefinitely when transplanted serially under favorable conditions. The tumor cells of the Jensen Rat Sarcoma, growing today in host rats in many laboratories of the world, are the direct descendants of the cells of the original tumor which Jensen transplanted in 1908.

In the early experiments on transplantation it was customary to inoculate a spontaneous tumor into a large number of animals. The hosts as a rule were not related to the original animal that bore the tumor, and so the subsequent growth of the transplant was unpredictable. The tumor tissue might grow in none of the hosts or in only a few. Rarely did it grow in all the hosts into which it was transplanted. A large number of the tumors regressed spontaneously. As a result of the systematic charting of tumor growth, it was recognized about 1904 that mice in which transplanted tumors had regressed were immune to subsequent transplants of the same line of tumor and often to other tumors as well. According to Clowes, this discovery was principally responsible for the expansion of cancer research throughout the world.

Although Nowinsky, Hanau, and Morau had a vague notion that transplanted tumors grew better in kindred animals, it remained for later investigators to prove the importance of a close blood relationship between donor and host animals. In 1903 Jensen transplanted a cancer that originated in a white mouse to other white mice and to gray mice. The tumor grew in 40 to 50 percent of the white hosts for 19 generations. However, it grew in fewer gray mice, and the rate of growth was slower. In 1904 Loeb transplanted a submaxillary gland tumor of a Japanese waltzing mouse to other Japanese waltzing mice for 2 generations, but he terminated the experiment because it was difficult to procure a sufficient number of the Japanese mice. Loeb drew attention to the variations existing among individuals or families of the same species that may influence the growth of tumors.

Between 1909 and 1916 Tyzzer and Little attempted to identify factors responsible for the differences in susceptibility and resistance to transplantable tumors with respect to the genetic constitution of inbred, hybrid, and backcross mice. The development of inbred strains began with Little's brother to sister mating of dilute brown mice and the inbreeding of other races of mice by Bagg and by Strong. This early work has been reviewed by Strong and also by Heston. Nearly 100 inbred strains of mice are now in existence. Inbreeding reduces to a minimum the variations that are present among individuals of a heterogeneous population and thereby facilitates the transplantation of tumors. In 1924 Little and Strong formulated a genetic theory of transplantation. Briefly, the outcome of transplantation depends upon the degree of genetic similarity between the grafted tissue and the host. A cancer originating in one member of an inbred strain usually grows readily when transplanted to other members of the strain or to first generation hybrids. Tumors originating in these hybrids usually cannot be grown in the parent strain, since neither contains all the genetic factors present in the hybrids. The rate of growth of a transplanted tumor, its spread, its physiologic effects on the host, and its killing time generally show little fluctuation in inbred animals. Moreover, the pattern of spontaneous cancer in each inbred strain of animal is in general specific for age and sex as well as for site and histologic type.

Some transplantable tumors will grow in heterozygous animals or in unrelated inbred strains of the same species, despite genetic differences between donor and host. All the well known transplantable tumor lines developed during the first two decades of this century are, in fact, lines capable of transplantation in heterozygous hosts. The Brown-Pearce Tumor of the rabbit, for example, has been transplanted in strains of rabbits in which brother to sister mating has not been practiced. Under these conditions the success of transplantation is often variable and regressions may be frequent. Sarcoma 37, which arose in a non-inbred mouse, was for years transplanted to market and stock mice. However, this tumor may grow better in mice of some inbred strains than of others. With time, Sarcoma 37 may become so well adapted to a given inbred strain that the percentage of successful transplants is much higher than in strains into which the tumor is transplanted for the first time.

In general, transplantation is successful only within the species in which the tumor originated (homotransplantation), although certain measures have been devised whereby a tumor can be made to grow in alien species (heterotransplantation). In 1912 Murphy found that the cells of certain tumors of the mouse and rat would grow when explanted to the chorioallantoic membrane of the chick embryo, and that these tumor cells could be maintained by continuous passage from egg to egg. Since that time, tumors from chickens, ducks, mice, rats, rabbits, guinea pigs, and man have been explanted to the fertile egg by the use of the chorioallantoic membrane or the yolk sac, or by the injection of tumor cells into the blood stream or into the substance of the embryo. The developing chick embryo shows little or no resistance to the growth of heterologous tumor tissue and will supply blood vessels and connective tissue for its support. Since some tumors can be carried by continuous passage in the chick embryo, it is possible after a few egg passages to obtain a pure strain of tumor cells devoid of stroma from the original tumor. This procedure has been found useful for immunological studies. Tumors of the mouse, rat, chicken, and man growing in the egg are being used to assay the tumor-inhibiting activity of various agents.

Embryonic, immature, and newborn animals in which immunity has not reached its fullest development have been used to accomplish heterologous transplantation. Bullock, in 1915, described the successful transfer of one sarcoma and two carcinomas of mice to newborn rats. Putnoky (1938) and DeBalogh (1940) propagated virulent strains of the Ehrlich Carcinoma of the mouse in young rats and found that the tumor killed approximately 60 percent of the animals within two weeks. In 1950 Patti and Moore grew Sarcoma 180 of the mouse by transplanting it intraperitoneally to newborn rats. The rats died in about a week with widespread intra-abdominal tumor and pulmonary metastases.

Partial abrogation of resistance to heterologous tumor transplants has been achieved by producing acquired tolerance following the methods of

Billingham and associates. The inoculation of whole blood and leukocyte fractions from donor mice of different strains into embryo mice altered the response of the injected mice so that the survival of skin grafts from the donor mice was greatly prolonged. Application of the principle of acquired tolerance has led to the adaptation of strain or species specific tumors to grow in hitherto insusceptible hosts (Koprowski et al.). For example, Swiss mice were made tolerant to the strain-specific 6C3HED Ascites Tumor by prenatal inoculation of blood from C3H mice or of cells of the 6C3HED tumor itself. In the latter instance, the tumor grew in the fetus and continued to grow in the Swiss mouse after birth; subsequently this tumor was readily transplantable in adult untreated Swiss mice. A similar technic was applied to the DBA Mouse Lymphoma and the AH130 Rat Hepatoma. The tumors that grew in the baby Swiss mice after inoculation of tumor cells in utero were not readily transplantable to Swiss mice in the ascites form, but after several intracerebral passages in baby Swiss mice, they grew progressively as ascites tumors in untreated adult mice of this strain. In this way, several lines of the 6C3HED DBA and AH130 tumors were adapted to grow in Swiss mice. The adapted lines resembled the original tumor in immunological properties, but the cell volume, the DNA and RNA content, and the chromosome modality were increased. The original tumors were insusceptible to the action of several oncolytic viruses, while the adapted lines were readily destroyed by infection with these agents.

The resistance of adult animals to transplantable tumors may be diminished by blockage of the reticuloendothelial system with particulate matter, by exposure to roentgen rays, and by treatment with cortisone. Toolan, in 1951, reported that she had been able to grow human tumors and some normal tissues in previously irradiated rats. The transplants regressed, however, after the rats recovered from the effect of irradiation. In 1952 Green and Whiteley succeeded in transplanting a pulmonary carcinoma from man into the subcutaneous tissue of five cortisone-treated mice. That same year Sommers and associates published a series of papers in which they described the successful transplantation of human cancer in the subcutaneous tissues of the irradiated rat, in the cheek pouch of the untreated hamster, and on the chorioallantoic membrane of the chick embryo. In 1953 Toolan propagated human tumors in the subcutaneous tissue of cortisone-treated rats and in the cheek pouch of cortisone-treated hamsters. Some tumors were thus maintained in serial transplantation for more than two years. The cheek pouch was first utilized as a site for tumor transplantation by Lutz and associates.

The brain and the eye are not much affected by the immune response of the host, and hence heterologous transplant tumors will often grow in these sites in untreated adult animals. In 1938 Greene reported progressive growth for more than 80 days of human mammary carcinoma transplanted into the anterior chamber of the eye of the rabbit, and he later showed that heterolo-

gous embryonic tissue could also be successfully transplanted to the same site. Greene has also found the brain to be a suitable location for the growth of heterologous tumors, as have Eichwald and associates, who reported growth of Sarcoma 37 in the subdural space of the guinea pig. Growth of human tumors following transplantation to the brain of animals has been less successful than the growth of tumors originating in various animal species. Geissler, in 1891, inoculated human cancer intracerebrally into rabbits and found that while the tumor fragments remained within the brain, the cells did not proliferate. More recent studies such as those by Chesterman and by Lumb have indicated that while human tumors transplanted into the brains of mice may persist, they rarely show progressive growth.

Sources of Transplantable Tumors

The early work on tumor transplantation in laboratory animals was carried out entirely with lines derived from spontaneous tumors found by chance. As experimentally induced tumors became available, they also were studied by transplantation. Clunet, the first to induce tumors experimentally in animals, transplanted a sarcoma that he had induced in a rat by exposure to roentgen rays. In 1 of 8 host rats a nodule developed at the site of inoculation but regressed within three months and was not examined microscopically. Yamagiwa and Ichikawa, in 1914, and other investigators in the next few years applied tar to the skin of rabbits and mice and thereby induced tumors, the first of which was successfully transplanted by Fibiger and Bang in 1920. Since these early experiments, many induced tumors have been found to be transplantable, and their behavior appears to be similar to that of transplanted spontaneous tumors. Perhaps the most commonly induced tumors to be studied in transplantation are squamous cell carcinomas of the skin and sarcomas of different types or of mixed types arising in the subcutaneous region following the application of a carcinogen. An example of a transplantable induced liposarcoma of the guinea pig is described in the section on Tumors of the Subcutaneous Tissues.

The tissue culture technic, introduced by Harrison in 1907, was employed by Carrel and Burrows in 1910 to grow the cells of the Rous Sarcoma, and by Lambert and Hanes in 1911 to culture transplantable sarcomas of the mouse and rat. Fischer found that the cells of the Ehrlich Carcinoma grown in vitro retained their neoplastic properties upon reinstatement in vivo in the mouse, after having resided in tissue culture. Murray and Stout and others have used tissue culture as a technic to cause morphologic differentiation of tumors, thus revealing their site of origin. As shown by Gey and by Earle and Nettleship, previously normal cells that have acquired malignant neoplastic properties during their growth in tissue culture may form progressively growing tumors when pieces of the explant are inoculated into suitable host animals. Thus, the cells of Earle's L Sarcoma, today commonly maintained

in host transplantation from mouse to mouse, are the descendants of the cultured cells of normal subcutaneous tissue (fibroblasts?) excised from a mouse in 1940. These experiments revealed the impressive fact that the malignant state of protoplasm once established is inheritable indefinitely from cell to cell in mitosis.

The transplantation of tumors so far described consists in the transference of living cells; the new tumors develop solely from the implanted cells. Some other tumors, however, in addition to being transplantable in this way are transmissible by material containing no living intact tumor cells. Ellermann and Bang, in 1908, discovered that spontaneous leukemia of the chicken could be transmitted by injecting a cell-free filtrate of the tumor into a normal chicken, where it produced identical leukemia. This was the first evidence to support the hypothesis of Borrel and others that a virus may be concerned in the production of cancer. In 1910 Rous transplanted a sarcoma found in the pectoral muscles of a Plymouth Rock hen and later showed that this tumor was transmissible by cell-free filtrates. Many other filterable chicken sarcomas were subsequently found that could be accurately reproduced by the inoculation of a cell-free filtrate, the new tumor developing promptly at the site of injection.

Up to now no other tumors have been found that are transmissible like the fowl tumors and leukemias in the sense of being exactly and promptly reproduced by cell-free filtrates, although there are several others in which the etiologic importance of viruses is known or suspected. The cutaneous rabbit papilloma of Shope is certainly virus-induced. The disease is contagious, being passed from rabbit to rabbit in the wild state. It can be experimentally transmitted to domestic rabbits by inoculating them with cell-free filtrates of a papilloma from a wild rabbit. As a rule the papillomas in domestic rabbits are not further transmissible by filtrates, and they are not transplantable. Many, however, eventually undergo malignant change. The resulting epidermal carcinoma, although it yields no virus and is not transmissible by cell-free extracts, yet is transferable from rabbit to rabbit by the inoculation of intact tumor cells.

Other tumors associated with virus-like agents are also not strictly classifiable as transmissible tumors in the sense in which the term is applied to certain tumors of fowls. A virus-like agent is concerned in the etiology of mammary tumors of mice, but its exact role remains controversial. In 1918 Lathrop and Loeb found that the offspring of hybrid mice of certain strains showed a higher incidence of mammary tumors if their mothers belonged to a strain of high mammary tumor incidence. The staff of the Jackson Memorial Laboratory (1933) established more decisively the importance of a maternal factor, which they described as extrachromosomal inheritance, and in 1936 Bittner gave convincing evidence for the transmission of an "influence" in the

milk. The milk agent, acquired by mice of suitable genetic constitution by suckling or by injection in early life, determines the development of mammary cancer in adult life, provided there is adequate hormonal stimulation.

In 1942 Andervont developed a line of $C3H_f$ mice (formerly called $C3H_b$) presumably free of the mammary tumor agent. In the development of this line of mice, the offspring were removed from the C3H milk-agent-bearing mothers by Caesarean operation, and then foster nursed on C57BL mice, free of the milk agent. The mice of the $C3H_f$ line thus developed were bred brother to sister, and the offspring, which were born normally, nursed their own mothers. Only 3 percent of the females of this $C3H_f$ line developed mammary tumors at an average age of 22 months as compared with an incidence of 91 percent at 8.5 months in the milk-agent-bearing C3H mice.

Experiments like Andervont's also indicate that not all mammary tumors of mice are due to the milk agent. Mammary tumors, whether they arise in mice with or without the milk agent, can be transplanted from mouse to mouse within inbred strains by the inoculation of intact tumor cells and do not depend upon the presence of the milk agent for their transplantability. The agent is recoverable from the tumors that have developed in the agent-bearing mice as well as from non-neoplastic tissues of such mice. It is agreed that the milk agent is an important etiologic factor in mammary cancer in high-incidence strains of inbred mice, but whereas some regard it as the all important carcinogenic or initiating factor, others attribute to it a secondary adjuvant or accelerating role.

The reports of Gross have stimulated renewed interest in the possibility that mouse leukemia is transmissible by a virus and that the same virus or another associated virus contained in the same filtrate may induce other tumors as well. In 1951 Gross reported that he had induced leukemia in strain C3H mice by inoculating them when newborn with cell-free extracts of leukemic tissue from strain AK/n mice. That same year Stewart observed tumors of the parotid and adrenal glands in mice similarly treated with cell-free material. She found that these tumors could be transplanted to untreated adult host mice by the inoculation of intact tumor cells but that the tumors were not transmissible by cell-free material. Similar observations on salivary gland tumors were made by Gross. The report by Friend of the isolation of a virus causing a neoplastic disease of the hematopoietic system in adult Swiss mice awaits confirmation.

The term "transplantable tumor" as used in this fascicle denotes those tumors that can be transferred from animal to animal by the inoculation of living tumor cells. Transmissible tumors are those that can be transplanted by the inoculation of living tumor cells and in addition can be transferred by the injection of a cell-free filtrate into the host animal. The conditions for such passage are often highly specialized. It is recognized that some of the tumors to be described cannot be classified with certainty at the present time; they

are included without prejudice to future decisions about their nature and etiology.

Technics of Transplantation

Although tumors may be transplanted into various sites in the body, they are most commonly transplanted into the subcutaneous or muscular tissues. Transplantation to sites such as the eye and the brain require special procedures (Greene). Snell has discussed various factors that may influence the growth of a transplanted tumor. In the present fascicle special methods and the results of transplanting leukemia and ascites tumors are described. The early investigators felt it necessary to use large numbers of tumor cells to transplant tumors. However, in 1937 Furth and Kahn discovered that a leukemia of a mouse could be transplanted by the inoculation of a single cell. The single cell inoculation technic has also been used by Ishabashi to transplant the Yoshida Tumor and by Hauschka to transplant the Ehrlich and the Krebs 2 tumors.

It is advisable to retransplant tumors while they are still small, because large rapidly growing tumors in the subcutaneous tissue or muscle are likely to become hemorrhagic, necrotic, ulcerated, and infected. Tumors that have become infected can sometimes be freed of the infecting organism by inoculating them intravenously or intraperitoneally, by employing host mice previously immunized to the organism, by using minimal amounts of tumor tissue for transfer, or with the help of antibiotics. Viable tumor tissue from living or recently killed animals should be selected and transplanted under aseptic precautions. However, since tumor tissue even from animals that have died and show autolysis may sometimes grow when transplanted, it is never safe to assume that a tumor will not grow until an attempt has been made to transplant it. Histologic preparations should be obtained from any tumor that is transplanted in order to verify the diagnosis. There are many reasons why one should not rely solely upon the gross appearance of a transplanted tumor. A spontaneous tumor of the host may by chance arise near the site of inoculation of the transplant. An organized abscess of bacterial origin or a chronic granuloma due to a fungus may also be mistaken for a growing transplanted tumor. The nature of such lesions is often disclosed only upon histologic examination.

The most generally useful method of transplantation is by trocar and cannula. The portion of tumor tissue to be transplanted is placed in a Petri dish and snipped into small pieces that easily fit the bore of a 10 or 12 gauge trocar. The Solid Tumor Screening Group at the Sloan-Kettering Institute for Cancer Research transplants tumors by trocar into a thousand or more mice each week. Stock has told us that in the past seven or eight years probably 375,000 tumors have been transplanted by the trocar method. When large

numbers of animals are to be inoculated and especially when the dose of tumor cells is to be measured, it is often convenient to prepare a mash or brei of tumor tissue to be transplanted. The tumor tissue may be homogenized, minced, or squeezed through a tissue press. Details of this procedure are given in the section on Sarcoma 37.

Results of Transplantation

An animal inoculated with tumor tissue should be observed at regular intervals to determine the fate of the transplant. Some transplanted tumors have a short latent period before they become palpable at the site of inoculation, then grow rapidly and kill the animal in a matter of days. Other tumors do not become palpable for many months after inoculation and grow slowly thereafter. The tumor can be measured with calipers and thus an estimation of the rate of growth as well as any indication of regression can be recorded.

The development of a progressively growing tumor at the site of inoculation after a variable latent period is spoken of in this fascicle as a "successful transplantation." Some investigators use the term "take" to describe successful establishment and initial growth of the implant, irrespective of its ultimate fate. Progressively growing tumors ultimately kill the host. Interval histologic studies of the tumor inoculum in the subcutaneous tissue of mice reveal that while many of the inoculated tumor cells die, those that survive gain support and nutrition for their growth from the adjacent proliferating connective tissue and blood vessels of the host. If the tumor-bearing host survives for a sufficiently long period of time, the growing transplanted tumor may spread locally and may metastasize to various tissues and organs. It is not uncommon to find that a transplanted tumor of a mouse has metastasized to an internal organ such as the lungs or the liver, while no tumor cells can be demonstrated as having been arrested in the regional lymph nodes. Not all transplantable tumors, however, metastasize, and even closely related tumors may differ in this respect. For example, the Harding-Passey Melanoma of the mouse generally remains localized at the site of inoculation, whereas the Cloudman Melanoma S91 frequently metastasizes to the lungs. Certain tumors may fail to grow progressively at the local site of inoculation but may appear in the tissue of an internal organ of the inoculated host. For example, Reticulum-cell Sarcoma 8469 occasionally fails to grow subcutaneously at the site of inoculation, while massive growths of this tumor almost always develop in the liver remote from the inoculation site. The tumor tissue in the liver grows progressively and kills the host.

Even though a tumor may not grow at the site of inoculation, the cells of the inoculum may survive there in situ and still retain their capacity to form a progressively growing tumor when transferred to a more favorable environment. Tumor cells adapted to one strain of animal may survive but not

proliferate when transplanted into an animal of another strain. The persistence of viability of such tumor cells is occasionally demonstrable by retransplantation of the inoculum into an animal of the susceptible strain. Sometimes tumor cells fail to grow at the site of inoculation for lack of suitable stroma, or because they have all died as a result of some factor such as infection. Transplanted tumor cells may grow for a limited period of time to form a palpable tumor that later regresses. The animal is then usually resistant to the growth of the same tumor and often to the growth of another tumor as well. Transplants of the Brown-Pearce Tumor of the rabbit frequently regress and provoke in the host an immune response that inhibits the growth of subsequent transplants of this tumor.

Transplanted tumors may continue to reproduce the histologic pattern of the parent tumor throughout many transplant generations, as has Pulmonary Adenocarcinoma C4461. In its 150th transplant generation this tumor has still retained the papillary adenomatous structure of the primary alveologenic carcinoma from which it was derived. Most transplanted tumors, however, lose at least some of their functional capacity and undergo changes in histologic pattern in the direction of cellular anaplasia. Thus Osteogenic Sarcoma 344 ceased to produce bone after the 1st transplant generation. Sarcoma 37, a substrain of a carcinoma of the mammary gland discovered 50 years or so ago, has become so anaplastic and undifferentiated that it cannot now be classified strictly as a carcinoma or as a sarcoma but must be placed in the category of undifferentiated tumors. Both the alveologenic carcinoma of the lung and the adenocarcinoma of the mammary gland of mice may become transformed into fibrosarcoma during transplantation. This structural alteration may be seen in the 1st generation or it may develop gradually during several generations. The question has never been satisfactorily answered as to whether the carcinoma cell becomes the sarcoma cell or whether the change in pattern is brought about in some other way.

Some mixed tumors when transplanted may continue to reproduce their several tissue components, as does Teratoma E6496. Other mixed tumors may lose some of their tissue components as in the case of Parotid Gland Tumor L7205. A collision tumor, consisting of both carcinomatous and sarcomatous tissue elements, generally loses its epithelial tissue upon transplantation. Gastric Carcinoma 342, however, is an exception, since the neoplastic connective tissue element of this carcinosarcoma has disappeared on transplantation, while the epithelial element has persisted. The Walker 256 is a rare example of a transplanted tumor that continues to grow as a carcinosarcoma.

In the section on Tumors of the Blood Vascular System we describe an example of a transplantable spontaneous hemangioendothelioma of the mouse. This particular tumor has not become converted into the blood-filled neoplastic cyst so commonly seen by Andervont following serial transplantation of hem-

angioendotheliomas induced by the subcutaneous injection of o-aminoazotoluene in mice. The straplike cells of subcutaneously induced sarcomas that are thought to be rhabdomyosarcomas usually disappear upon serial transplantation. Thus tumors originally distinguished as rhabdomyosarcoma, leiomyosarcoma, and fibrosarcoma often lose their distinguishing characteristics on serial transplantation and revert to a common type of tumor composed of rapidly dividing spindle-shaped cells. The change in structural features with consequent loss of functional capacity is related to the progression or increased degree of malignancy, manifested clinically by an increase in percentage of successful transplants, a shortened latent period, more rapid growth, and fewer regressions of the transplanted tumor.

Hormones are important in the transplantation of tumors. Mammary fibroadenomas of the rat and certain testicular and pituitary gland tumors of the mouse are examples of transplantable tumors that are dependent to some extent upon the hormonal status of the host. Transplants of the pituitary gland tumors that arise in thyroidectomized mice may not grow unless the thyroid gland of the recipient host has been destroyed. Successful transplantation of the interstitial cell tumor of the testis requires pretreatment of the host mice with estrogen. A fibroadenoma of the rat was found by Heiman and Krehbiel to grow in 66 percent of female and 33 percent of male hosts, whereas in castrate animals it grew in 16 percent of the females and 60 percent of the males. This tumor grows faster during pregnancy and may secrete a milky fluid during lactation. These are all examples of the effects of hormones on the behavior of transplanted tumors.

Some transplanted tumors also produce hormones of their own in quantities sufficient to alter the physiologic status of the host or to bring about changes in anatomic structure. A transplanted, estrogen-secreting, granulosa-cell tumor of the ovary may induce a state of continuous estrus in female host mice and may stimulate the rudimentary mammary glands of males to develop an extensive duct system. A pituitary gland tumor that has become autonomous and can therefore be transplanted into intact mice may induce cancer of the thyroid gland in the host bearing the transplant. The induction of cancer of the thyroid gland under these circumstances has been attributed to some carcinogenic activity associated with the presence of excess thyroid stimulating hormone elaborated by the transplanted tumor of the pituitary gland.

It is often as difficult to assign the immediate cause of death of animals bearing transplanted tumors as it is to assign the immediate cause of death of human beings dying of cancer. We do know of a few rather specific reactions to certain transplanted tumors which certainly contribute to the death of the host. Examples are the hypervolemia accompanying the growth of Gastric Adenocarcinoma 328 and of Granulosa-cell Tumor XIV which may lead to death from congestive heart failure; and the extreme granulocytic leukemoid reaction of mice bearing Myoepithelioma HD which may well be a factor in the death

of the host animal. In some transplanted leukemias death has been ascribed to the crowding out of the normal bone marrow cells, since no toxic factor of the neoplastic cells has been demonstrated. The circulating blood is thus depleted of erythrocytes, normal leukocytes, and platelets to a point incompatible with life. Sometimes a transplanted tumor kills the host by producing obstruction of some vital organ. The mere size of the tumor may so impede the animal's movement that it is incapable of obtaining adequate food and water without assistance.

When tumors become necrotic, ulcerated, and infected, the products of necrosis and the toxic effects of the invading organisms undoubtedly affect adversely the health and length of life of the animal. Some studies show that particular transplanted tumors affect the metabolism of specific vital organs such as the liver and the adrenal gland. Often animals bearing large transplanted tumors become debilitated, and death is finally caused by a terminal disease such as pneumonia. Therefore, no general statement can be made as to the immediate cause of death of animals bearing transplanted tumors, and each neoplasm must be considered individually. It is probable that death is often due to a combination of factors.

Materials and Methods

Living tumor-bearing animals were in nearly every case available to the authors for examination. In a few cases (noted in the text) in which we were unable to secure living animals bearing a transplant of a particular tumor, we have examined fixed pathologic material of a recent transplant generation. When possible we have examined histologic slides from paraffin blocks or wet tissue of the primary tumor and intervening generations. We have also based our study upon reports in the literature and upon personal communications from investigators working with particular tumors.

Tissues were fixed routinely in Helly's formol-Zenker solution. Other fixatives occasionally used were formalin, acetone, alcohol, Regaud's fluid, and Cajal's uranium nitrate—formalin solution. The coloring methods used routinely were hematoxylin and eosin, the periodic acid—Schiff reaction of McManus with or without previous digestion with diastase, Wilder's silver oxide for reticulum, Mallory's aniline blue, Masson's trichrome, van Gieson's picrofuchsin, Mallory's phosphotungstic acid—hematoxylin, and Heidenhain's iron alum hematoxylin. Other methods employed in special cases were Altmann's anilin-fuchsin methyl green and Regaud's iron hematoxylin for mitochondria, Gomori's Prussian blue reaction for iron, the Krajian modification of Masson's silver method for melanin, Mayer's mucicarmine for mucus, Sudan IV for fat, Bodian's protargol for nerve fibers, Verhoeff's iodine ferric chloride hematoxylin for elastic tissue, Fontana's ammoniacal silver oxide for argentaffin granules, Foot's modification of Bielchowsky's silver for reticulum, Laidlaw's modification of Bloch's dopa reaction and Gomori's methods for the demon-

stration of acid and alkaline phosphatase, and the Giemsa and Wright differential stains for blood cells.

Contents of Fascicle

This fascicle contains the history and pathologic descriptions of 50 transplantable and transmissible tumors of animals. Thirty are of mice, 10 of rats, 3 of rabbits, 2 each of the dog and the chicken, and 1 each of the hamster, guinea pig, and frog. The authors have tried to select representative examples of the great variety of transplantable tumors that commonly occur spontaneously or that can be induced in different animal species. Thus, in the mouse for example, we have chosen Hepatoma 98/15, Pulmonary Adenocarcinoma C4461, and Leukemia Line I, because each of these tumors may be taken as a prototype of a large and important group. We have included Mammary Fibroadenoma R2737 because this represents a very common tumor of the rat, and the Renal Adenocarcinoma of the frog because this probably has been the most intensely studied tumor of cold-blooded animals. Myofibrosarcoma HS–6 of the hamster and Liposarcoma D4888 of the guinea pig also were induced in species in which relatively few tumors have been described and are examples of neoplasms most frequently induced in these particular animals.

Some tumors like the Bashford 63, Sarcoma 37, the Rous Sarcoma, the Flexner-Jobling Carcinosarcoma, the Jensen Sarcoma, and the Ehrlich Tumor are included because of their special significance in the history of cancer research coupled with the fact that they are still widely used today. Other tumors, some of comparatively recent origin, were selected to serve as examples of neoplasms that may occur in particular organs and to round out the picture of cancer as it occurs in laboratory animals and as it may have its counterpart in man.

The effects of hormones and the relation of the endocrine glands have of late been greatly emphasized and have been the subject of much experimental study. It was therefore decided to include various tumors of the endocrine and reproductive systems, such as the Furth Pituitary Tumor, Luteoma IX and Granulosa-cell Tumor XIV of the ovary, and Adrenal Cortical Carcinoma WK1546. It is felt that exact knowledge of the transplantation behavior and pathologic characteristics of a wide range of transplantable tumors should be available to other investigators in order that they may consider the relative merits of different tumors in making their selection for use in such fields as chemotherapy, tissue culture, or virology.

References

Andervont, H. B. Induction of hemangio-endotheliomas and sarcomas in mice with o-amino-azotoluene. J. Nat. Cancer Inst., 10:927–941, 1950.

———, and Dunn, T. B. Mammary tumors in mice presumably free of the mammary-tumor agent. J. Nat. Cancer Inst., 8:227–233, 1948.

Bashford, E. F. The application of experiment to the study of cancer. J. Comp. Path. & Therap., 21:14–35, 1908.

————, and Murray, J. A. The significance of the zoological distribution, the nature of the mitoses, and the transmissibility of cancer. Brit. M. J., 1:269–271, 1904.

Billingham, R. E., Brent, L., and Medawar, P. B. Quantitative studies on tissue transplantation immunity. III. Actively induced tolerance. Philos. Tr. R. Soc. London, 239:357–414, 1956.

Bittner, J. J. A review of genetic studies on the transplantation of tumours. J. Genetics, 31:471–487, 1935.

————. Some possible effects of nursing on the mammary gland tumor incidence in mice. Science, 84:162, 1936.

Borrel, A. Epithélioses infectieuses et Epithéliomas. Ann. Inst. Pasteur, 17:81–118, 1903.

Bullock, W. E. Heterologous transplantation: mouse tumours in rats. Lancet, 138:701–703, 1915.

Carrel, A., and Burrows, M. T. Cultivation of sarcoma outside of the body. J. A. M. A., 55:1554, 1910.

Chesterman, F. C. Intracranial heterotransplantation of human tumours. Brit. J. Cancer, 9:51–61, 1955.

Chute, R. N., Sommers, S. C., and Warren, S. Heterotransplantation of human cancer. II. Hamster cheek pouch. Cancer Research, 12:912–914, 1952.

Clemmesen, J. The Influence of X-radiation on the Development of Immunity to Heterologous Transplantation of Tumors. New York & London: Oxford University Press, 1938.

Clowes, G. H. A. Editorial: Cancer research fifty years ago and now. Cancer Research, 16:2–4, 1956.

Clunet, J. Recherches Expérimentales sur les Tumeurs Malignes. Paris: G. Steinheil, 1910.

Committee on Standardized Nomenclature for Inbred Strains of Mice: Standardized nomenclature for inbred strains of mice. Cancer Research, 12:602–613, 1952.

Cornil, M. V. Sur les greffes et inoculations de cancer. Semaine méd., 11:259, 1891.

DeBalogh, E. Investigations on a new heterologous tumor, "Budapest 1938," successfully propagated in Hungarian white rats. Am. J. Cancer, 39:45–55, 1940.

Dmochowski, L. The milk agent in the origin of mammary tumors in mice. In: Greenstein, J. P., and Haddow, A. (eds.). Advances in Cancer Research, pp. 103–172. Vol. I. New York: Academic Press, Inc., 1953.

Dunham, L. J., and Stewart, H. L. A survey of transplantable and transmissible animal tumors. J. Nat. Cancer Inst., 13:1299–1377, 1953.

Duran-Reynals, F. Virus-induced tumors and the virus theory of cancer. In: Homburger, F., and Fishman, W. H. (eds.). The Physiopathology of Cancer, pp. 298–337. New York: Paul B. Hoeber, Inc., 1953.

Earle, W. R. Production of malignancy in vitro. IV. The mouse fibroblast cultures and changes seen in the living cells. J. Nat. Cancer Inst., 4:165–212, 1943.

————, and Nettleship, A. Production of malignancy in vitro. V. Results of injections of cultures into mice. J. Nat. Cancer Inst., 4:213–227, 1943.

Eichwald, E. J., Goodman, G. J., and Chang, H. Y. Tumor transplantation to the subdural space of heterologous hosts. Proc. Soc. Exper. Biol. & Med., 78:72–74, 1951.

Ellermann, V., and Bang, O. Experimentelle Leukämie bei Hühnern. Centralbl. f. Bakt., 1. Abt., 46:595–609, 1908.

Engelbreth-Holm, J. Spontaneous and Experimental Leukaemia in Animals. (Translated by C. L. Heel.) Edinburgh & London: Oliver and Boyd, Ltd., 1942.

Fibiger, J. Recherches sur le carcinome spiroptérien de la souris blanche et sur sa transplantabilité. Compt. rend. Soc. de biol., 83:1160–1163, 1920.

Firket, Ch. De la réussité de greffes sarcomateuses en série. Note prélimaire. Bull. Acad. roy. de méd. de Belgique, 6:1147–1148, 1892.

Firor, W. M., and Gey, G. O. Observations on the conversion of normal into malignant cells. Ann. Surg., 121:700–703, 1945.

Fischer, A. Dauerzüchtung reiner Stämme von Carcinomzellen in vitro. Ztschr. f. Krebsforsch, 25: 89–96, 1927.

Flexner, S., and Jobling, J. W. Infiltrating and metastasising sarcoma of the rat. J. A. M. A. 48:420, 1907.

Foulds, L. The experimental study of tumor progression: a review. Cancer Research, 14:327–339, 1954.

Friend, C. The isolation of a virus causing a malignant disease of the hematopoietic system in adult Swiss mice. Proc. Am. Assoc. Cancer Research, 2:106, 1956.

Furth, J., and Kahn, M. C. The transmission of leukemia of mice with a single cell. Am. J. Cancer, 31:276–282, 1937.

Gardner, W. U. Hormonal aspects of experimental tumorigenesis. In: Greenstein, J. P., and Haddow, A. (eds.). Advances in Cancer Research, pp. 173–232. Vol. I. New York: Academic Press, Inc., 1953.

Geissler, T. Die Uebertragbarkeit des Carcinoms. In: von Bergmann, E. (ed.). Arbeiten aus der chirurgischen Klinik der Königlichen Universität Berlin, pp. 70–91. Pt. 8. Berlin: August Hirschwald, 1893.

Gey, G. O. Personal communication to Earle, W. R.; cited in: Earle, W. R. Production of malignancy in vitro. IV. The mouse fibroblast cultures and changes seen in the living cells. J. Nat. Cancer Inst., 4:165–212, 1943.

Grauer, R. C., and Robinson, G. H. Lactation in transplantable benign mammary adenomas in rats. Am. J. Cancer, 16:191–201, 1932.

Green, H. N., and Whiteley, H. J. Cortisone and tumour growth. Brit. M. J., 2:538–540, 1952.

Greene, H. S. N. Heterologous transplantation of mammalian tumors. I. The transfer of rabbit tumors to alien species. II. The transfer of human tumors to alien species. J. Exper. Med., 73: 461–474; 475–486, 1941.

———. The transplantation of tumors to the brains of heterologous species. Cancer Research, 11:529–534, 1951.

———. The significance of the heterologous transplantability of human cancer. Cancer, 5: 24–44, 1952.

Gross, L. "Spontaneous" leukemia developing in C3H mice following inoculation, in infancy, with AK-leukemic extracts, or AK-embryos. Proc. Soc. Exper. Biol. & Med., 76:27–32, 1951.

———. Induction of parotid carcinomas and/or subcutaneous sarcomas in C3H mice with normal C3H organ extracts. Proc. Soc. Exper. Biol. & Med., 88:362–368, 1955.

Hanau, A. Erfolgreiche experimentelle Uebertragung von Carcinom. Fortschr. d. Med., 7:321–339, 1889.

———. Demonstration von durch Ueberimpfung Künstlich erzeugten carcinomen. Verh. Kongr. f. inn. Med., 8 Kongr., 289–292, 1889.

Harrison, R. G. Observations on the living developing nerve fiber. Proc. Soc. Exper. Biol. & Med., 4:140–143, 1907.

Hauschka, T. S. Methods of conditioning the graft in tumor transplantation. J. Nat. Cancer Inst., 14:723–739, 1953.

Heiman, J., and Krehbiel, O. F. The influence of hormones on breast hyperplasia and tumor growths in white rats. Am. J. Cancer, 27:450–473, 1936.

Heston, W. E. Development of inbred strains in the mouse and their use in cancer research. Publ. of Roscoe B. Jackson Memorial Lab. 20th Commemoration, Bar Harbor Times, Bar Harbor, Me., 1949.

Ishibashi, K. Studies on the number of cells necessary for the transplantation of Yoshida sarcoma. Transmission of the tumor with a single cell. Gann, 41:1–14, 1950.

Jensen, C. O. Experimentelle Untersuchungen über Krebs bei Mäusen. Centralbl. f. Bakt., 1. Abt., 34:28–34; 122–143, 1903.

_____. Übertragbare Rattensarkome. Ztschr. f. Krebsforsch., 7:45–54, 1908.

Karnofsky, D. A., Ridgway, L. P., and Patterson, P. A. Tumor transplantation to the chick embryo. In: The Chick Embryo in Biological Research. Ann. New York Acad. Sc., 55 (art. 2):313–329, 1952.

Kaufman, N., Kinney, T. D., Mason, E. J., and Prieto, L. C., Jr. Maintenance of human neoplasm on the chick chorioallantoic membrane. Am. J. Path., 32:271–285, 1956.

Koprowski, H. Actively acquired tolerance to a mouse tumour. Nature, London, 175:1087–1088, 1955.

_____, Theis, G., and Love, R. Immunological tolerance in tumour studies. Adaptation of ascites tumours to homologous or heterologous hosts. Proc. Roy. Soc., London, s. B., 146:37–57, 1956.

Korteweg, R. On the manner in which the disposition to carcinoma of the mammary gland is inherited in mice. Genetica, 18:350–371, 1936.

Lambert, R. A., and Hanes, F. M. Growth in vitro of the transplantable sarcomas of rats and mice. J. A. M. A., 56:33–34, 1911.

Lathrop, A. E. C., and Loeb, L. Further investigations on the origin of tumors in mice. V. The tumor rate in hybrid strains. J. Exper. Med., 28:475–500, 1918.

Law, L. W. Genetic studies in experimental cancer. In: Greenstein, J. P., and Haddow, A. (eds.). Advances in Cancer Research, pp. 281–352. Vol. II. New York: Academic Press, Inc., 1954.

Leblanc, U. Recherches sur le cancer des animaux. Rec. méd. vét., 35:769–783; 902–916, 1858.

_____. Recherches sur le cancer des animaux. Rec. méd. vét., 36:25–41, 1859.

Leidy, J. Remarks on transplantation of animal tissue. Proc. Acad. Natur. Sc. Philadelphia, 5:201; 212, 1851.

Leighton, J., Kline, I., and Orr, H. G. Transformation of normal human fibroblasts into histologically malignant tissue in vitro. Science, 123:502–503, 1956.

Lewis, W. H. Dibenzanthracene mouse sarcomas. Histology. Am. J. Cancer, 37:521–530, 1939.

Little, C. C. The genetics of tumor transplantation. In: Snell, G. D. (ed.). Biology of the Laboratory Mouse, pp. 279–309. Philadelphia: Blakiston Co., 1941.

_____, and Strong, L. C. Genetic studies on the transplantation of two adenocarcinomata. J. Exper. Zool., 41:93–114, 1924.

_____, and Tyzzer, E. E. Further experimental studies on the inheritance of susceptibility to a transplantable tumor, carcinoma (j. w. a.) of the Japanese waltzing mouse. J. Med. Res., 33: 393–454, 1916.

Loeb, L. On transplantation of tumors. J. Med. Res., 6:28–38, 1901.

_____. Further investigations in transplantation of tumors. J. Med. Res., 8:44–73, 1902.

_____. On some conditions determining variations in the energy of tumor growth. Am. Med., 10:265–269, 1905.

Lumb, G. Transplantation of human tumours into mouse-brain. Brit. J. Cancer, 8:434–444, 1954.

Lutz, B. R., Fulton, G. P., Patt, D. I., and Handler, A. H. The growth rate of tumor transplants in the cheek pouch of the hamster (Mesocricetus auratus). Cancer Research, 10:231–232, 1950.

McFadyean, J. The occurrence of tumours in the domesticated animals. J. Comp. Path. & Therap., 3:35–45, 1890.

Morau, H. Recherches expérimentales sur la transmissibilité de certains néoplasmes. Arch. de méd. expér. et d'anat. path., 6:677–705, 1894.

Müller, J. Ueber den feineren Bau und die Formen der krankhaften Geschwülste. Berlin: Reimer, 1838.

Murphy, J. B. Transplantability of malignant tumors to the embryos of a foreign species. J. A. M. A. 59:874–875, 1912.

Murray, M. R., and Stout, A. P. The classification and diagnosis of human tumors by tissue culture methods. Tex. Rep. Biol. & Med., 12:898–915, 1954.

Nowinsky, M. Zur Frage über die Impfung der krebsigen Geschwülste. Centralbl. f. d. med. Wissensch., 14:790–791, 1876.

Oberling, C., and Guérin, M. Lesions tumorales en rapport avec la leucémie transmissible des poules. Bull. Assoc. franc. p. l'étude du cancer, 22:180–212, 1933.

———, and Guérin, M. Nouvelles recherches sur la production de tumeurs malignes avec le virus de la leucémie transmissible des poules. Bull. Assoc. franc. p. l'étude du cancer, 22:326–360, 1933.

———, and Guérin, M. The role of viruses in the production of cancer. In: Greenstein, J. P., and Haddow, A. (eds.). Advances in Cancer Research, pp. 353–423. Vol. II. New York: Academic Press, Inc., 1954.

Patti, J., and Moore, A. E. Heterologous growth of sarcoma 180 with progression to death of hosts. Cancer Research, 10:674–678, 1950.

Peyrilhe, B. A Dissertation on Cancerous Diseases, translated from the Latin, with notes. London: Printed for J. Wilkie, No. 71, St. Paul's Church-yard, 1777.

Putnoky, J. Über die heteroplastiche Transplantation des Ehrlichschen überimpfbaren Mäusecarcinoms. Ztschr. f. Krebsforsch., 32:520–525, 1930.

———. On the immunity reactions of a heterotransplantable mouse carcinoma propagated in rats for seven years. Am. J. Cancer, 32:35–49, 1938.

Rous, P. A transmissible avian neoplasm. (Sarcoma of the common fowl.) J. Exper. Med., 12:696–705, 1910.

———. A sarcoma of the fowl transmissible by an agent separable from the tumor cells. J. Exper. Med., 13:397–411, 1911.

———, and Murphy, J. B. Tumor implantations in the developing embryo. Experiments with a transmissible sarcoma of the fowl. J. A. M. A., 56:741–742, 1911.

Sailer, J. A critical summary of the literature. On the inoculability of carcinoma. Am. J. M. Sc., 120:190–202, 1900.

Schwann, T. Mikroskopische Untersuchungen über die Uebereinstimmung in der Struktur und dem Wachstum der Thiere und Pflanzen. Berlin: Reimer, 1839.

Shimkin, M. B., and Mider, G. B. Induction of tumors in guinea pigs with subcutaneously injected methylcholanthrene. J. Nat. Cancer Inst., 1:707–725, 1941.

Shope, R. E. A transmissible tumor-like condition in rabbits. J. Exper. Med., 56:793–802, 1932.

Snell, G. D. Transplantable tumors. In: Homburger, F., and Fishman, W. H. (eds.). The Physiopathology of Cancer, pp. 338–391. New York: Paul B. Hoeber, Inc., 1953.

Sommers, S. C., Chute, R. N., and Warren, S. Heterotransplantation of human cancer. I. Irradiated rats. Cancer Research, 12:909–911, 1952.

———, Sullivan, B. A., and Warren, S. Heterotransplantation of human cancer. III. Chorioallantoic membranes of embryonated eggs. Cancer Research, 12:915–917, 1952.

Staff of Roscoe B. Jackson Memorial Laboratory. The existence of non-chromosomal influence in the incidence of mammary tumors in mice. Science, 78:465–466, 1933.

Stewart, H. L. Tumors induced by subcutaneously injected carcinogens. In: Homburger, F., and Fishman, W. H. (eds.). The Physiopathology of Cancer, pp. 46–61. New York: Paul B. Hoeber, Inc., 1953.

Stewart, S. E. Neoplasms in mice inoculated with cell-free extracts or filtrates of leukemic mouse tissues. I. Neoplasms of the parotid and adrenal glands. J. Nat. Cancer Inst., 15:1391–1405, 1955.

Sticker, A. Ueber den Krebs der Thiere inbesondere über die Empfänglichkeit der verschiedenen Hausthierarten und über die unterschiede des Thier—und Menschenkrebses. Arch. f. klin. Chir., 65:616–696; 1023–1087, 1902.

Stock, C. C. Personal communication.

Strong, L. C. The origin of some inbred mice. Cancer Research, 2:531–539, 1942.

_____, Gardner, W. U., and Hill, R. T. Production of estrogenic hormone by a transplantable ovarian carcinoma. Endocrinology, 21:268–272, 1937.

Toolan, H. W. Successful subcutaneous growth and transplantation of human tumors in x-irradiated laboratory animals. Proc. Soc. Exper. Biol. & Med., 77:572–578, 1951.

_____. Transplantable human neoplasms maintained in cortisone-treated laboratory animals. Cancer Research, 14:660–666, 1954.

_____. Subcutaneous growth of normal and malignant human tissues in heterologous hosts. Tr. New York Acad. Sc., 17:589–593, 1955.

Tyzzer, E. E. A study of inheritance in mice with reference to their susceptibility to transplantable tumors. J. Med. Res., 21:519–573, 1909.

Virchow, R. Die Cellular-pathologie in ihrer Begrüngdung auf physiologische und pathologische Gewebelehre. Berlin: August Hirschwald, 1858.

von Eiselsberg, F. Ueber einen Fall von erfolgreicher Transplantation eines Fibrosarkoms bei Ratten. Wien. klin. Wchnschr., 3:927–928, 1890.

Woglom, W. H. Studies in Cancer and Allied Subjects. Vol. I. The Study of Experimental Cancer. A Review. New York: Columbia University Press, 1913.

_____. Immunity to transplantable tumours. Cancer Review, 4:129–214, 1929.

Yamagiwa, K., and Ichikawa, K. Über die künstliche Erzeugung von Karzinom. Tr. Soc. path. jap., 6:169–178, 1915.

TUMORS OF THE SKIN

Shope Papilloma. Rabbit

SYNONYMS: Rabbit papilloma, Shope; papillomatosis of the rabbit; transmissible warts.

DEFINITION. A virus-induced, naturally occurring cutaneous papilloma of the rabbit.

HISTORY OF NATURALLY OCCURRING DISEASE. For many years wild cottontail rabbits shot by hunters in states bordering the Mississippi River had commonly been observed to have cutaneous hornlike protuberances and were popularly referred to as "horned" or "warty" rabbits. In 1933 Shope proved these papillomatous growths to be due to a virus.

The virus is described as a homogeneous, large, macromolecular protein which, with few exceptions, can be demonstrated in this form only in tumors from wild rabbits. The Shope Papilloma virus, in common with other specific viruses that cause cutaneous papillomas in man, cattle, and dogs, is cell and species specific and exclusively dermotropic.

The naturally occurring disease in the rabbit is characterized by a cutaneous papilloma that measures 0.5 to 1.0 cm. or more in diameter and is elevated 1.0 to 1.5 cm. above the surface of the skin. The spontaneous lesions, usually 1 to 10 or more in number, exhibit a predilection for the inner aspects of the thighs, ventral abdomen, neck, and shoulders. The individual papilloma has a rough, irregular, or fissured surface. It is black or gray-black and so loosely attached to the underlying tissue that when traumatized it is easily dislodged, leaving a bleeding base. The cut surface of the papilloma is vertically striated and shows a fleshy white or pink-white center. The histologic characteristics of the naturally occurring and of the experimentally transmitted tumors are similar.

TRANSMISSION STUDIES. The Shope Papilloma may be transmitted by inoculating scarified skin of the wild rabbit with cell-free filtrates of the tumor or with a suspension of tumor cells. The experimental papilloma may be detected within 6 to 18 days after inoculation. A tumor also develops in an area of the skin that has been scarified following intravenous injection of virus at another site. The tumor is easily transmitted to domestic rabbits if source material from a lesion of the wild rabbit is employed for inoculation. Inoculation of tumor extracts from domestic rabbits into other domestic rabbits is occasionally successful if the skin of the recipient is rendered hyperplastic and more sensitive by treatment with such chemicals as 20-methylcholanthrene or a mixture of turpentine and acetone. Under these conditions the virus has not ordinarily been maintained beyond a second passage in domestic rabbits.

According to Syverton, the naturally occurring papillomas of the wild rabbit regress in about 20 percent of animals during the first six months following their appearance and in 36 percent of animals at a later period. Malignant transformation takes place in the papilloma of the wild rabbit in about 25 percent of cases, the process beginning about the twelfth month following onset of the disease. Virus is recoverable from the papilloma until the time the lesion exhibits evidence either of regression or of malignant transformation. This has led to the assumption that there is an effect on the masking of the virus influenced by the age of the papilloma in the wild rabbit. Virus can be recovered from benign papillomas of a rabbit that also has, elsewhere on the skin, cancers in which the virus is absent. However, the virus cannot be detected in all papillomas of cottontail rabbits, and less virus is recovered from the experimentally induced tumors than from the naturally occurring ones.

Syverton stated that 6 to 9 percent of experimentally induced papillomas disappeared within the first six months of their development. After the sixth month, none of the experimentally induced lesions underwent regression, whereas more than one third of the naturally occurring lesions disappeared. Kidd, however, has reported that in his experience 50 percent or more of the punctate papillomas induced by tattooing virus into small spots in the skin of domestic rabbits do regress abruptly within a few weeks following the inoculation of the virus.

Rous and Beard observed that many benign papillomas carried in domestic rabbits for 200 days or longer underwent a malignant change. It was from such a source that the transplanted V2 Carcinoma was derived. A virus-induced papilloma has been converted into a carcinoma in a period of 60 to 80 days by the prolonged application of chemical carcinogens to the papilloma. Transformation of a papilloma to carcinoma has also occurred in a few weeks' time following the intravenous injection of the virus into rabbits whose skin had previously been treated with chemical carcinogens.

Shope found that domestic rabbits as well as wild rabbits exhibited neutralizing and complement fixing antibodies for the papilloma virus when these animals developed warts on the scarified skin that had previously been inoculated with filtrate from the warts of wild rabbits. Animals so treated were relatively resistant to reinfection with the virus. Despite this immunologic evidence, only rarely has virus been recovered from tumors of the domestic rabbit, and then only in small amounts. The antigenicity of the causal agent of the papilloma induced in the domestic rabbit was also demonstrated by inoculating extracts of the wart intraperitoneally into normal rabbits. Some of the animals so inoculated developed complement-fixing and neutralizing antibodies against the virus, and an even larger number of animals, on challenge, showed resistance to reinfection by virus. Therefore, even though the virus is ordinarily not recoverable from the papilloma of the domestic rabbit, it is thought to be present in this lesion in what is called a masked form. How-

ever, in at least two experiments, papilloma virus has been carried through 10 serial passages in domestic rabbits.

DESCRIPTION OF CURRENT TUMOR. Glycerolated papilloma tissue from a cottontail rabbit was inoculated into an area of scarified skin, 5 cm. square, on the right flank of a New Zealand white rabbit. After one month, discrete and confluent papillomatous masses covered the entire inoculated area. At necropsy, 11 months later, ulcerated growth covered an area 10 cm. in diameter. Tissue taken for histologic study includes a firm pinkish gray papillomatous nodule and adjacent skin.

Microscopically, the Shope Papilloma consists of elongated rete-like structures composed of a central core of connective tissue covered by stratified squamous epithelium (fig. 1). The surface of the papilloma shows areas of erosion and crusting (fig. 3). The rete-like epithelial structures extend into the underlying connective tissue to a uniform depth over the width of the section. This stratified squamous epithelium has a layer of enlarged basal cells, many of which are perpendicular to the basement membrane, although others show lack of polarity (fig. 2). The prickle cell layer is edematous and consists of large cells, some of which measure from 50 to 75 microns in diameter and have either one lobate nucleus or several nuclei. The granular layer may be either absent or well developed, and the surface is covered with keratin, parakeratotic material, desquamated cells, and inflammatory cells. The prickle cells and flattened cells contain large numbers of periodic acid—Schiff-positive granules, which can be removed by diastase and are therefore presumably glycogen. All through this thickened epithelium are numerous small epithelial pearls. Tonofibrils are extremely prominent and numerous in phosphotungstic acid—hematoxylin preparations (fig. 4). Mitotic figures average one per high power field, are usually regular in the basal cell layer, and often large and bizarre in the prickle cell layer. Round red bodies of varying size that may be degenerating nuclear elements are occasionally observed.

The connective tissue of the corium below the papilloma is edematous and diffusely infiltrated with pseudoeosinophils, lymphocytes, and histiocytes (fig. 6). Hair follicles and sebaceous glands are absent. There are numerous dilated congested vessels, and perivascular fibrosis is seen. The elastic tissue is markedly altered so that instead of occurring in long threads it is chiefly in the form of rounded entangled masses of short frayed fibers (fig. 5).

OTHER PROLIFERATIVE VIRUS-INDUCED LESIONS IN THE RABBIT (MYXOMATOSIS AND FIBROMATOSIS). Although not genuinely neoplastic, two types of proliferative lesion of the rabbit occurring under natural conditions should be mentioned in connection with the Shope Papilloma. The first, **myxomatosis,** a highly contagious and an almost universally fatal disease of domestic rabbits, was first recognized by Sanarelli in 1898 in South America. This inflammatory lesion, with a myxomatous connective tissue response,

spreads widely in the subcutaneous tissue. Dissemination of the disease is by way of infective discharges from the body orifices. The disease is fatal in Angora rabbits, Belgian hares, and Flemish giants. The wild rabbit of Brazil and the cottontail and jack rabbits of the United States, although susceptible to the disease, rarely die of it.

The second type of proliferative lesion, **fibromatosis**, was described by Shope in 1932. Although related to myxomatosis, this disease is almost never fatal. The lesion of fibromatosis, which is more tumor-like than that of myxomatosis, appears in wild cottontail rabbits as one or more firm subcutaneous nodules from which virus can be recovered. This lesion is composed of spindle-shaped connective tissue cells with no inflammatory reaction. The disease can be transmitted to domestic rabbits. Following recovery from fibromatosis, animals are resistant to infection by the myxoma virus.

References

Beard, J. W., and Rous, P. A virus-induced mammalian growth with the characters of a tumor (the Shope rabbit papilloma). II. Experimental alterations of the growth on the skin: morphological considerations: the phenomena of retrogression. J. Exper. Med., 60:723–740, 1934.

Bryan, W. R., and Beard, J. W. Studies on the purification and properties of the rabbit-papilloma-virus-protein. J. Nat. Cancer Inst., 1:607–673, 1941.

Duran-Reynals, F. Virus-induced tumors and the virus theory of cancer. In: Homburger, F., and Fishman, W. H. (eds.). The Physiopathology of Cancer, pp. 298–337. New York: Paul B. Hoeber, Inc., 1953.

Ginder, D. R. Rabbit papillomas and the rabbit papilloma virus; a review. In: Viruses as Causative Agents in Cancer. Ann. New York Acad. Sc., 54 (art. 6):1120–1125, 1952.

Kidd, J. G. Personal communication.

Rous, P. The virus tumors and the tumor problem. Am. J. Cancer, 28:233–272, 1936.

———, and Beard, J. W. A virus-induced mammalian growth with the characters of a tumor (the Shope rabbit papilloma). I. The growth on implantation within favorable hosts. J. Exper. Med., 60:701–722, 1934.

———, and Beard, J. W. A virus-induced mammalian growth with the characters of a tumor (the Shope rabbit papilloma). III. Further characters of the growth: general discussion. J. Exper. Med., 60:741–766, 1934.

———, and Beard, J. W. The progression to carcinoma of virus-induced rabbit papillomas (Shope). J. Exper. Med., 62:523–548, 1935.

Sanarelli, G. Das myxomatogene Virus; Beitrag zum Studium der Krankheitserreger ausserhalb des Sichtbaren. Zentralbl. f. Bakt., I. Abt., 23:865–873, 1938.

Shope, R. E. A filtrable virus causing a tumor-like condition in rabbits and its relationship to virus myxomatosum. J. Exper. Med., 56:803–822, 1932.

———. Infectious papillomatosis of rabbits. With a note on the histopathology by E. W. Hurst. J. Exper. Med., 58:607–624, 1933.

———. Serial transmission of virus of infectious papillomatosis in domestic rabbits. Proc. Soc. Exper. Biol. & Med., 32:830–832, 1935.

Syverton, J. T. The pathogenesis of the rabbit papilloma-to-carcinoma sequence. In: Viruses as Causative Agents in Cancer. Ann. New York Acad. Sc., 54 (art. 6):1126–1140, 1952.

SHOPE PAPILLOMA. RABBIT

(Illustrations are taken from a lesion induced in a New Zealand white rabbit by inoculating its scarified skin with glycerolated tissue from a papilloma of a cottontail rabbit. Histologic sections courtesy of Dr. A. S. Symeonidis, Athens, Greece; formerly at the National Cancer Institute, Bethesda, Md.)

Figure 1. Section through the papilloma and adjacent skin. The thickened epithelium of the papilloma and the changes in the underlying connective tissue are shown in greater detail in the illustrations that follow. Note the pale character of the connective tissue stroma underlying the papilloma. Ball-like accumulations of elastic tissue are seen at the junction of the epithelium and the connective tissue at the right upper margin of the lesion. These are illustrated in higher magnification in figure 5. Elastica and van Gieson stain. X 7. N. C. I.* 8402; A. F. I. P.** Acc. No. 219934–1.

Figure 2. A higher power photomicrograph of the epithelial component of the papilloma. The epithelial-connective tissue junction may be seen at the bottom of the figure. This area illustrates a more extreme degree of cellular atypism of the epithelial cells than is generally present in the papilloma. Hematoxylin and eosin stain. X 260. N. C. I. 8418; A. F. I. P. Acc. No. 219934–2.

Figure 3. Photomicrograph showing the surface of the papilloma on the right and the base toward the left. Note hyperkeratosis, parakeratosis, inflammatory reaction, and erosion. Hematoxylin and eosin stain. X 50. N. C. I. 8407; A. F. I. P. Acc. No. 219934–3.

---

*With a few exceptions all photographs were taken at the National Cancer Institute; in this and the following legends N. C. I. stands for National Cancer Institute accession number.

**219934 is the Armed Forces Institute of Pathology accession number assigned to this fascicle.

Fig. 1

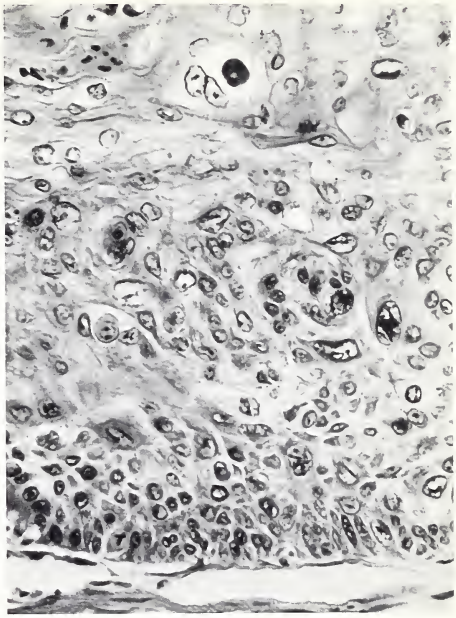

Fig. 2

Fig. 3

SHOPE PAPILLOMA. RABBIT

Figure 4. A high power photomicrograph of the thickened epithelium showing tonofibrils. Phosphotungstic acid—hematoxylin stain. X 530. N. C. I. 8431; A. F. I. P. Acc. No. 219934-4.

Figure 5. A low power photomicrograph of round, entangled masses of elastic fibers in the connective tissue beneath the papilloma illustrated in figure 1. Elastica and van Gieson stain. X 84. N. C. I. 8409; A. F. I. P. Acc. No. 219934-5.

Figure 6. Another low power photomicrograph of the connective tissue beneath the papilloma showing the edematous collagenous connective tissue, inflammatory reaction, and perivascular fibrosis. Hematoxylin and eosin stain. X 95. N. C. I. 8405; A. F. I. P. Acc. No. 219934-6.

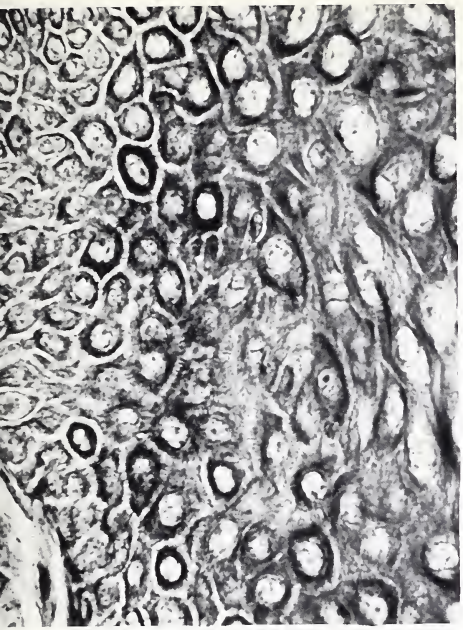

Fig. 4

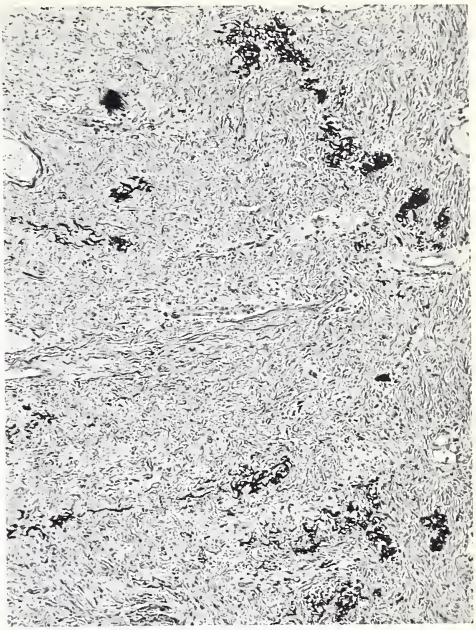

Fig. 5

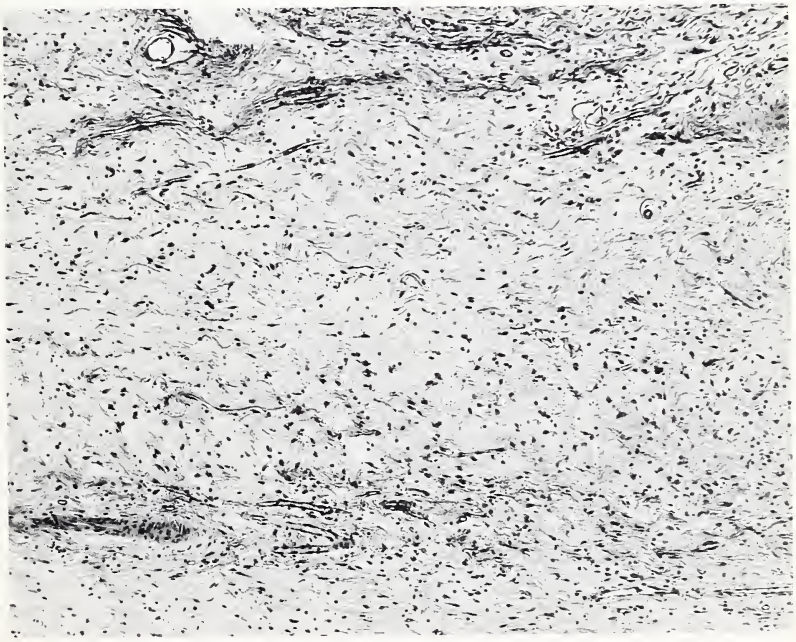

Fig. 6

V2 Carcinoma. Rabbit

SYNONYM: V x 2 Carcinoma.

DEFINITION. An anaplastic carcinoma that developed as a result of malignant alteration in the cells of a virus-induced papilloma (Shope) of a domestic rabbit.

HISTORY AND DESCRIPTION OF ORIGINAL TUMOR. The V2 Carcinoma was derived from a papilloma of a domestic rabbit inoculated with the Shope virus in 1937 by Kidd and Rous in the course of a study of the malignant transformation of such papillomas. Once before, a carcinoma that originated in a Shope Papilloma had been successfully transplanted, but it was lost after the second serial transfer. In the experiment that led to the development of the V2 Carcinoma, the Shope Papilloma virus was inoculated at eight sites into the scarified skin of a 7½-month-old Dutch belted male rabbit. Discrete and confluent papillomas developed at each site of inoculation. Nine to 11 months later, three of the papillomas were found to be ulcerated and had infiltrated the deeper tissue. One of these lesions had become a fleshy discoid mass, 7.5 cm. in diameter. An enlarged axillary lymph node of this animal measured 2.0 cm. in diameter and, on section, was found to be replaced by grayish pink tissue having areas of necrosis. This lymph node was minced and transplanted into the muscles of the forelegs and thighs of the same animal. The animal died 14 days later. At necropsy, the transplants exhibited evidence of growth. Moreover, the cutaneous papillary lesions at all eight sites inoculated with virus had undergone malignant change.

Kidd and Rous described the V2 Carcinoma as a squamous cell carcinoma that infiltrated adjacent tissue. The cells were arranged in sheets and blunt tongues that were separated by a large amount of newly formed connective tissue. Cystic areas containing debris and fluid were lined with papillary projections of tumor tissue. The tumor cell was large and possessed a correspondingly large nucleus that contained masses of chromatin concentrated near the nuclear membrane. Cells at the periphery of the tumor were the least differentiated. Mitotic figures were numerous and were often abnormal.

TRANSPLANTATION STUDIES. Two of the largest autotransplant tumor nodules in the foreleg of the host were minced and implanted into the muscles of the legs of 20 genetically related Dutch belted rabbits. Transplantation failed in 17 of these animals; in 2 others the transplant regressed after reaching a diameter of 4.0 mm. In the remaining animal, small growths developed at three of the transplantation sites. Just at the time that these growths had begun to exhibit signs of regression, they were transplanted to other rabbits of the same strain. In the next few generations, the tumor grew successfully in only an occasional rabbit. After the 5th generation, however, large tumors arose within a few weeks of inoculation and seldom regressed. During the course of serial transfers, the tumor became increasingly anaplastic in histo-

logic appearance. It often metastasized to lymph nodes and lung but rarely to other sites. Following an intravenous injection of a suspension of V2 Carcinoma cells, arrested emboli in the lungs frequently gave rise to tumors, but tumors elsewhere occurred in less than 5 percent of cases. In 1952 the V2 Carcinoma was in its 73rd transplant generation after 14 years of propagation.

Greene tested the transplantability of the V2 Carcinoma in the anterior chamber of the eye, in the brain, in the subcutaneous tissues, and in the testis of guinea pigs; and in the latter three sites in mice, hamsters, and rats. Transplantation was successful in the brain of all four species, in the eye of the guinea pig, and in the subcutaneous tissue and testis of the hamster and the mouse.

Other carcinomas arising from Shope Papillomas in a manner similar to the V2 Carcinoma have now been successfully transplanted by the use of newborn rabbits as hosts. These tumors have been extraordinarily malignant, metastasizing within a few weeks after transplantation.

IMMUNITY STUDIES. Kidd and Rous found that an antibody capable of neutralizing the Shope Papilloma virus in vitro appeared in the blood of every new host in which the transplanted V2 Carcinoma grew progressively. The antibody titer rose to a level comparable to that found in animals that had borne large Shope Papillomas for an appreciable period of time. This antibody was undetectable in the blood of normal rabbits and of rabbits in which the V2 Carcinoma failed to grow. Further experiments indicated that the antigenic component of the papilloma virus persisted in the cells of the V2 Carcinoma for 22 transplant generations, covering a span of five years. The blood of every one of 100 animals in which the cancer grew progressively contained the specific antibody for the papilloma virus. During World War II, tests for the antibody were discontinued and were not resumed until 1946, at which time the V2 Carcinoma was in its 46th transplant generation. At that time, it was found that the antibody for the papilloma virus was no longer present in the blood of rabbits that had long carried progressively enlarging V2 Carcinomas. The cells of these carcinomas did not appear to differ morphologically from those of the earlier tumor generations. It has not yet been determined whether the virus disappeared entirely from the V2 Carcinoma cells or still persisted in them in some nonantigenic and noninfective form.

DESCRIPTION OF CURRENT TUMOR. The tissue available for examination consists of a 17-day-old V2 Carcinoma transplant from the thigh of a New Zealand white rabbit and a solitary metastasis in an inguinal lymph node. The tumor from the thigh measures 4.0 cm. in greatest diameter and is not encapsulated. On section, friable pinkish white tissue forms the periphery of a thick-walled cystic structure filled with viscous fluid and grumous material.

The tumor invades the adjacent areolar tissue and skeletal muscle of the host, and both show the changes of chronic inflammation. The tumor cells form sheets, large and small nodules, and nests that are surrounded by reticu-

V2 CARCINOMA. RABBIT

(Histologic sections courtesy of Dr. R. R. Smith, National Cancer Institute, Bethesda, Md., and Dr. Charles Breedis, University of Pennsylvania, Philadelphia, Pa.)

Figure 7. Low power photomicrograph of transplant tumor showing a coarse nodular type of growth traversed by thin bands of stroma. In the host connective tissue there is a low grade chronic inflammatory reaction. Hematoxylin and eosin stain. X 67. N. C. I. 8414; A. F. I. P. Acc. No. 219934-7.

Figure 8. Another photomicrograph of transplant tumor. The tumor cells are growing in the form of sheets, nodules, and nests. Hematoxylin and eosin stain. X 235. N. C. I. 9304; A. F. I. P. Acc. No. 219934-8.

Figure 9. A higher power photomicrograph of transplant tumor. The tumor cells vary somewhat in size, shape, and staining capacity. Several mitotic figures are present in this field. Hematoxylin and eosin stain. X 500. N. C. I. 9288; A. F. I. P. Acc. No. 219934-9.

Figure 10. Section of inguinal lymph node. A solitary metastatic deposit occupies the central portion of the node. Hematoxylin and eosin stain. X 14. N. C. I. 8401; A. F. I. P. Acc. No. 219934-10.

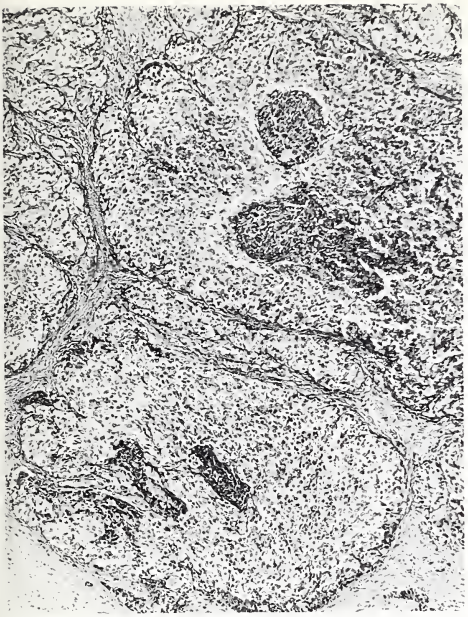

Fig. 7

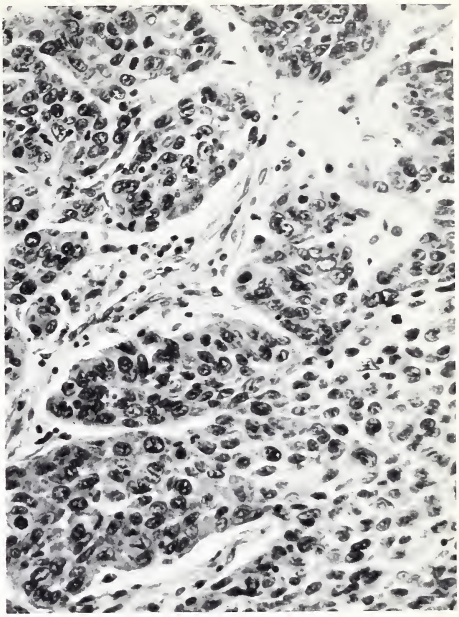

Fig. 8

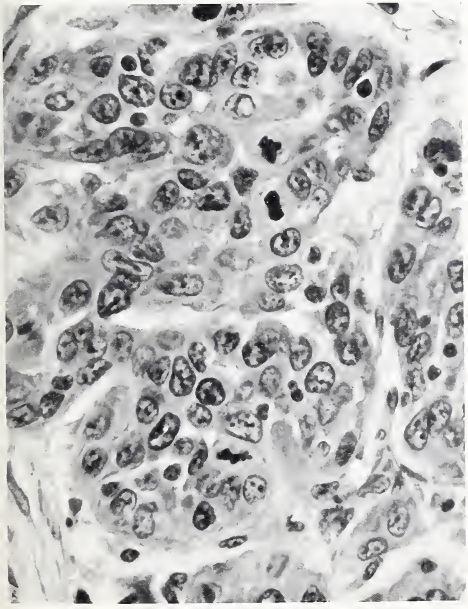

Fig. 9

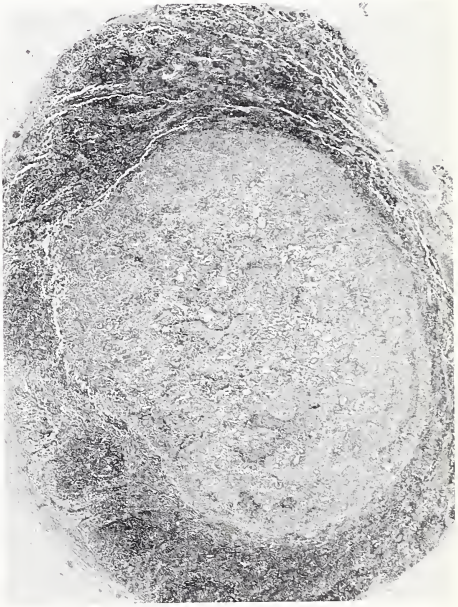

Fig. 10

lar fibers. The pattern is that of a carcinoma (figs. 7, 8). The tumor is further traversed by thin bands of stroma containing inflammatory cells and a few capillary-like blood vessels. Although about 20 percent of the tumor is necrotic, there is little or no hemorrhage. Small clumps of tumor cells are seen in vessels.

The tumor cells are polygonal and vary from 7 to 18 microns in diameter (fig. 9). The cytoplasm constitutes half of the volume of the cell and stains deeply with both eosin and hematoxylin. The periodic acid—Schiff reaction reveals a large amount of purplish red granular material in some of the tumor cells. This material is removed by diastase and is presumably glycogen. Tonofibrils are readily identifiable in the phosphotungstic acid—hematoxylin preparations. The nuclei are all of about the same size and all are hyperchromatic. However, they vary some in shape, being usually round, but sometimes oval or horseshoe-shaped. Very few multinucleated tumor cells can be found. The nuclear membrane is prominent, sometimes folded, and encloses fine chromatin material and one to several nucleoli, usually concentrated near the center of the nucleus. On the average, there is one mitotic figure per high power field, and some of these are abnormal in form. In areas near foci of necrosis, some of the cells have rounded eosinophilic inclusions. Epithelial pearls are not identified, but individual degenerated and necrotic cells may be deeply acidophilic, suggesting single cell keratinization.

The solitary metastatic tumor nodule occupying the central two thirds of the inguinal lymph node is sharply circumscribed, but not encapsulated. Small tonguelike projections of tumor cells extend into adjacent lymphatic sinuses (fig. 10). There is no evidence of pearl formation in this metastasis, although many tonofibrils are found. Single and multinucleated giant tumor cells are more numerous in this metastasis in the lymph node than in the intramuscular transplant, but otherwise the tumors are comparable.

References

Greene, H. S. N. The heterologous transplantation of the V–2 rabbit carcinoma. Cancer Research, 13:610–612, 1953.

Kidd, J. G. The rabbit papilloma virus (Shope) as a cause of cancer: facts and implications. Proc. 2nd National Cancer Congress, Vol. II, pp. 1372–1376, 1952.

_____, and Rous, P. A transplantable rabbit carcinoma originating in a virus-induced papilloma and containing the virus in masked or altered form. J. Exper. Med., 71:813–838, 1940.

Rous, P. The virus tumors and the tumor problem. Am. J. Cancer, 28:233–272, 1936.

_____, and Beard, J. W. The progression to carcinoma of virus-induced rabbit papillomas (Shope). J. Exper. Med., 62:523–548, 1935.

_____, Kidd, J. G., and Smith, W. E. Experiments on the cause of the rabbit carcinomas derived from virus-induced papillomas. II. Loss by the Vx2 carcinoma of the power to immunize hosts against the papilloma virus. J. Exper. Med., 96:159–174, 1952.

Smith, W. E., Kidd, J. G., and Rous, P. Experiments on the cause of the rabbit carcinomas derived from virus-induced papillomas. I. Propagation of several of the cancers in sucklings with etiological tests. J. Exper. Med., 95:299–318, 1952.

Zeidman, I., and Buss, J. M. Transpulmonary passage of tumor cell emboli. Cancer Research, 12:731–733, 1952.

TUMORS OF MELANIN-FORMING TISSUE

Cloudman Melanoma S91. Mouse

DEFINITION. A malignant melanoma that arose spontaneously at the base of the tail of a female DBA mouse.

HISTORY AND DESCRIPTION OF ORIGINAL TUMOR. Tumor S91 was found in 1937 at the base of the tail of a female DBA mouse by the late A. M. Cloudman at the Roscoe B. Jackson Memorial Laboratory, Bar Harbor, Maine. It was a firm, black, subcutaneous tumor, and the skin overlying it was devoid of hair. We have not found a histologic description of the primary tumor in the literature, and the sections are perhaps in Cloudman's personal slide collection if they were not destroyed in the fire at the Bar Harbor Laboratory in 1947.

TRANSPLANTATION STUDIES. Cloudman first transplanted this tumor on July 12, 1937, and it was not retransplanted until eight months later. In July 1954, it was in its 178th transplant generation at the Jackson Memorial Laboratory. The intramuscular transplant grows more aggressively and is not as completely encapsulated as the subcutaneous transplant. Subcutaneous transplants of the tumor reach a diameter of 2.5 cm. eight weeks after inoculation and kill the host within 9 to 12 weeks. The optimum transplantation interval is one month. According to Algire, S91 grows in from 80 to 100 percent of DBA mice inoculated. The tumor metastasizes frequently to the lungs, and occasionally to the liver, kidneys, adrenal glands, lymph nodes, and tissues of the orbital region. Metastatic growths appear as black or brown nodules 0.5 to 3.0 mm. in diameter and are generally multiple in any one organ. In addition to the metastases of tumor cells, groups of pigment-laden macrophages may be found in the regional lymph nodes, lung, and spleen.

DESCRIPTION OF THE CURRENT CLOUDMAN MELANOMA S91. The subcutaneously transplanted Cloudman Melanoma S91 is sharply circumscribed, ovoid, and reddish purple, black, or gray. Large transplanted tumors may be ulcerated.

Microscopically, the tumor is composed of spindle-shaped and polygonal cells arranged in sheets, whorls, and interlacing bundles interspersed with pigment-laden macrophages (fig. 11). The melanin may be regularly and diffusely scattered throughout the tumor or may vary in amount from area to area. In the macrophages, the melanin occurs in coarse granules that fill the cell to capacity (pl. I–A). These pigment-laden phagocytes are evenly

distributed throughout viable portions of the tumor, but they are concentrated in greatest numbers around the areas of necrosis. When the sections are bleached with potassium permanganate, the phagocytes are revealed to possess an abundant vacuolated cytoplasm and a single tiny nucleus that had been concealed by the melanin granules (figs. 12, 13).

In the neoplastic cells, the melanin granules of the cytoplasm vary from 0.3 to 1.0 microns in diameter. They may be concentrated near the cell membrane or at either pole of the cell, or they may be evenly distributed. Colorless cytoplasmic granules are also present. The nucleus constitutes about one-half the volume of the cell and is the same shape as the cell itself. The delicate nuclear membrane encloses dense clumps of chromatin and often two or more faintly acidophilic or deeply basophilic nucleoli. The nucleus contains no melanin. Three or four mitotic figures may be found in every high power field, and they are frequently abnormal in form. Fine melanin granules may be present in the cytoplasm of mitotically dividing tumor cells. Fibroglial fibers are demonstrable in some areas of the tumor that are composed of spindle-shaped tumor cells. Almost every cell of the tumor is surrounded by reticular fibers (fig. 14), although collagenic fibers and other formed elements of the connective tissue are not abundant.

Old transplanted tumors reveal necrosis of greater extent than do young transplanted tumors. The necrotic area is located in the center of the tumor in most cases, although small foci of necrotic tissue with associated hemorrhage may be found in the periphery of the tumor. Melanin granules are recognizable in necrotic tumor cells and in necrotic melanophores. The transplanted tumor is incompletely surrounded by a connective tissue capsule through which strands of neoplastic tissue invade the adjacent host tissues, including muscle, fat, and particularly perineural lymphatic vessels.

THE AMELANOTIC S91A TUMOR. The Cloudman Melanoma has always been carried in strain DBA mice. Algire also transplanted this tumor into albino mice of strain BALB/c (fig. 15). In the mice of both these strains portions of the subcutaneous transplants were often gray, being less pigmented than other portions which were black. The less pigmented portions of the tumor in mice of the BALB/c strain were dissected out and transplanted to other mice of the BALB/c strain. This selective transplantation resulted in a line of the tumor that was grossly amelanotic and which has been designated as **Amelanotic Melanoma S91A or C91AA** (fig. 16). This variant grew in from 50 to 70 percent of BALB/c mice and in from 80 to 100 percent of DBA mice. (The pigmented Cloudman S91 grew in from 80 to 100 percent of mice of both the BALB/c and DBA strains.) The S91A continued as a partially amelanotic tumor in strain BALB/c mice, but following successive transplantation into mice of strain DBA gradually regained its pigmented appearance.

Histologically, the partially amelanotic S91A, grown subcutaneously in host BALB/c mice, was composed chiefly of spindle-shaped cells with only a

few alveolar formations. There was considerably less melanin pigment than in the Cloudman S91. On the other hand, mitotic figures were more numerous. Metastatic growths of S91A in the lungs and in the medulla of the adrenal glands were often found to be more heavily pigmented than the tumor growing at the subcutaneous site of inoculation. When S91A was transplanted to DBA mice, the histologic pattern as well as the pigment content changed during the course of 10 transplant generations. From the pattern of spindle-shaped cells it became altered to form an alveolar pattern of polyhedral cells. The mitotic activity and the aggressiveness of the tumor remained unchanged.

DOPA REACTION OF THE MELANOTIC S91 AND AMELANOTIC S91A TUMORS. Loustalot and his associates found that they could distinguish the melanin-producing from the melanin-phagocytosing cells of the Cloudman Melanoma S91 by the dopa reaction. However, the amelanotic derivatives grown in strain BALB/c mice were characterized by an almost complete absence of dopa-positive cells. The amelanotic derivative of the tumor grown in DBA mice contained greater numbers of dopa-positive cells.

COMPARISON OF CLOUDMAN MELANOMA S91 AND THE HARDING-PASSEY MELANOMA. It is remarkable that the Harding-Passey Melanoma does not metastasize under ordinary circumstances, whereas the Cloudman Melanoma S91 almost invariably does metastasize. Thus, the Cloudman Melanoma may be said to be more malignant than the Harding-Passey Melanoma. The Cloudman Melanoma arose in a DBA strain mouse and generally grows poorly in mice of other strains aside from mice of the BALB/c strain. The Harding-Passey Melanoma, on the other hand, originated in a stock mouse and is not strain specific. There are additional differences of a structural nature that can be appreciated by comparing the photomicrographs and the histologic descriptions of the two tumors.

References

Algire, G. H. Growth and pathology of melanoma S91 in mice of strains dba, A, and C. J. Nat. Cancer Inst., 5:151–160, 1944.

Cloudman, A. M. The effect of an extra-chromosomal influence upon transplanted spontaneous tumors in mice. Science, 93:380–381, 1941.

———. Spontaneous neoplasms in mice. In: G. D. Snell (ed.). Biology of the Laboratory Mouse, by the staff of the Roscoe B. Jackson Memorial Laboratory, chap. 4. Philadelphia: Blakiston & Co., 1941.

Loustalot, P., Algire, G. H., Legallais, F. Y., and Anderson, B. F. Growth and histopathology of melanotic and amelanotic derivatives of the Cloudman melanoma S91. J. Nat. Cancer. Inst., 12:1079–1117, 1952.

Spangler, J. M., Murray, J. M., and Little, C. C. Genetics of the susceptibility of mice to a transplantable melanoma. J. Nat. Cancer Inst., 3:123–130, 1942.

Woods, M. W., DuBuy, H. G., Burk, D., and Hesselbach, M. L. Cytological studies on the nature of the cytoplasmic particulates in the Cloudman S91 mouse melanoma, the derived Algire S91A partially amelanotic melanoma, and the Harding-Passey mouse melanoma. J. Nat. Cancer Inst., 9:311–323, 1949.

CLOUDMAN MELANOMA S91. MOUSE

(Tumor-bearing animals courtesy of Dr. G. H. Algire, National Cancer Institute, Bethesda, Md.)

Figure 11. Photomicrograph of transplant tumor. This shows the arrangement of the tumor cells, the slitlike character of the blood vessels, and numerous macrophages heavily laden with pigment. The macrophages are fairly evenly distributed through this portion of the tumor. Hematoxylin and eosin stain. X 90. N. C. I. 7808; A. F. I. P. Acc. No. 219934–11.

Figure 12. Photomicrograph of transplant tumor. The pigment has been removed by bleaching with $KMnO_4$ and hence the appearance of the tumor cells is much more distinct than in figure 11. The histiocytes appear as large vacuolated cells, in some of which the nucleus is discernible. Hematoxylin and eosin stain of a section bleached with $KMnO_4$. X 100. N C. I. 7804; A. F. I. P. Acc. No. 219934–12.

Figure 13. Photomicrograph of transplant tumor. The distinction between the tumor cells and the large vacuolated phagocytes is best appreciated after removal of the melanin from the section. Hematoxylin and eosin stain of a section bleached with $KMnO_4$. X 570. N. C. I. 7825; A. F. I. P. Acc. No. 219934–13.

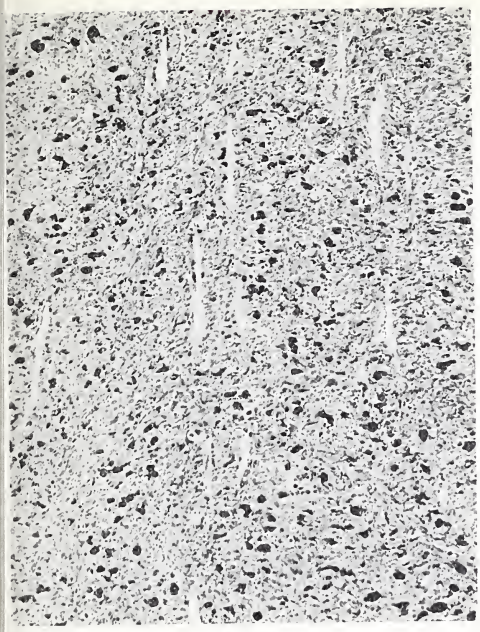

Fig. 11

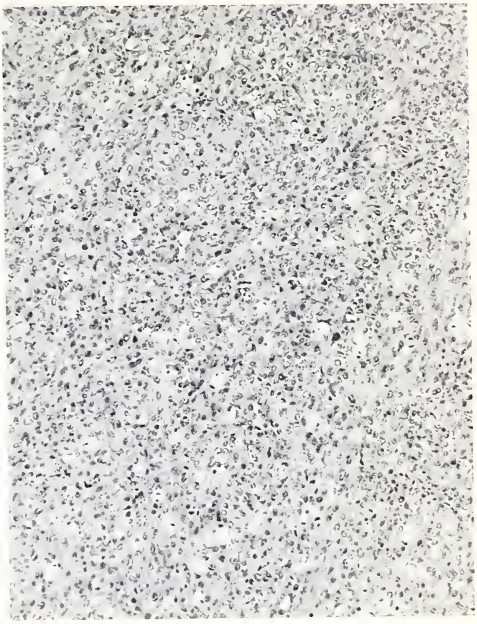

Fig. 12

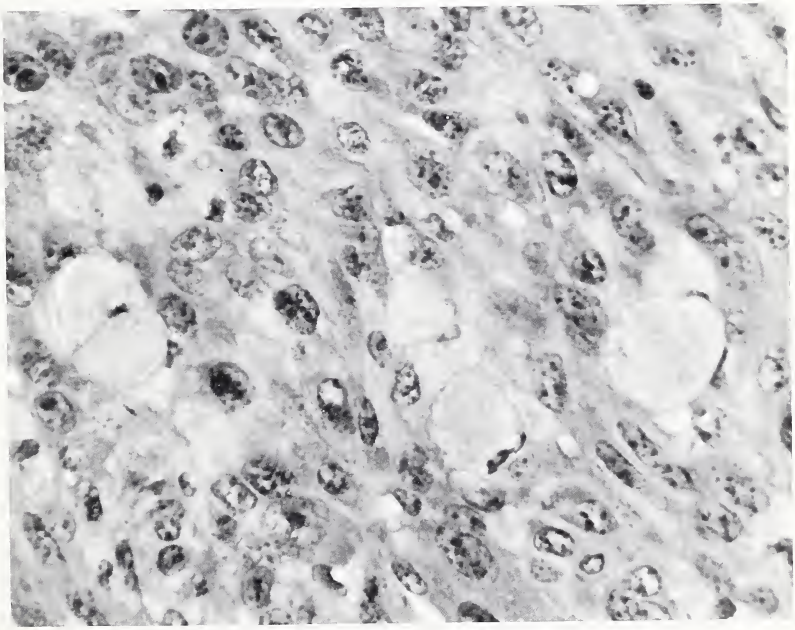

Fig. 13

CLOUDMAN MELANOMA S91. MOUSE

Figure 14. Photomicrograph of transplant tumor. The tumor cells are embedded in a coarse network of reticular fibers. Wilder's silver preparation. X 930. N. C. I. 7824; A. F. I. P. Acc. No. 219934–14.

Figure 15.* Gross photograph of subcutaneous transplant tumor of the pigmented S91 growing in a strain BALB/c mouse. N. C. I. 9731A; A. F. I. P. Acc. No. 219934–15.

Figure 16.* Gross photograph of a predominantly amelanotic S91 transplant tumor in a strain BALB/c mouse. This tumor was obtained by selecting the least pigmented areas of melanoma S91 for transfer. N. C. I. 9731B; A. F. I. P. Acc. No. 219934–16.

---

*From Loustalot, P., Algire, G. H., Legallais, F. Y., and Anderson, B. F. Growth and histopathology of melanotic and amelanotic derivatives of the Cloudman melanoma S–91. J. Nat. Cancer Inst., 12:1079–1117, 1952. Plate 109, figures 2 and 3 are our figures 15 and 16.

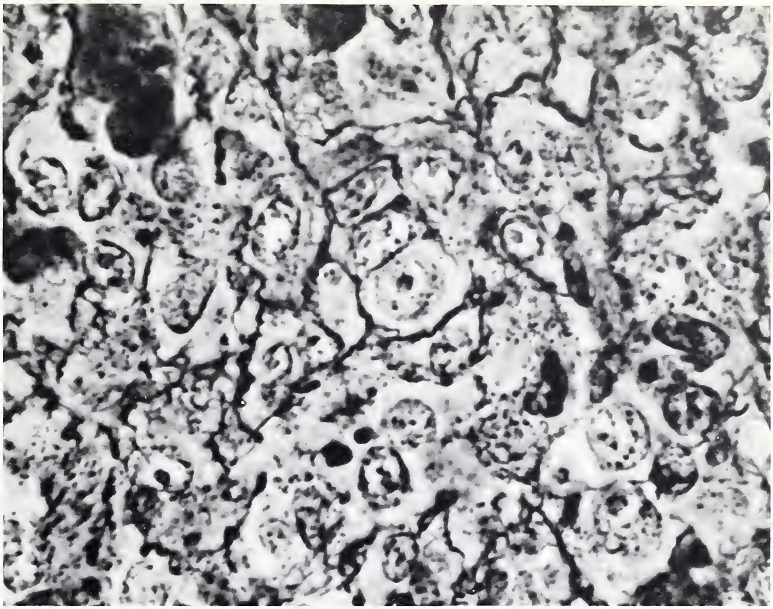

Fig. 14

Fig. 15

Fig. 16

PLATE I

CLOUDMAN MELANOMA S91. MOUSE

(Tumor-bearing animal courtesy of Dr. G. H. Algire, National Cancer Institute, Bethesda, Md.)

A. Photomicrograph of transplant tumor. In this area the tumor cells are polygonal and contain fine granules of melanin pigment. The macrophages in the field are filled to capacity with fine and coarse melanin granules. Note the single mitotic figure. Hematoxylin and eosin stain. X 900. N. C. I. 9724; A. F. I. P. Acc. No. 219934–293.

HARDING-PASSEY MELANOMA. MOUSE

(Tumor-bearing animal courtesy of Dr. G. H. Algire, National Cancer Institute, Bethesda, Md.)

B. Photomicrograph of transplant tumor. The cells are elongated and the cytoplasm of many of them is uniformly brown due to the content of melanin pigment. Hematoxylin and eosin stain. X 900. N. C. I. 7498; A. F. I. P. Acc. No. 219934–290.

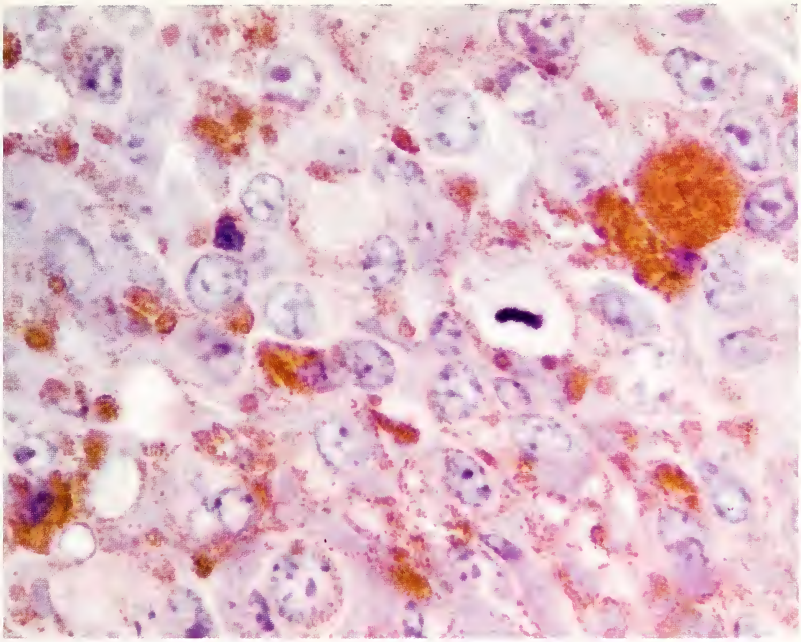

A

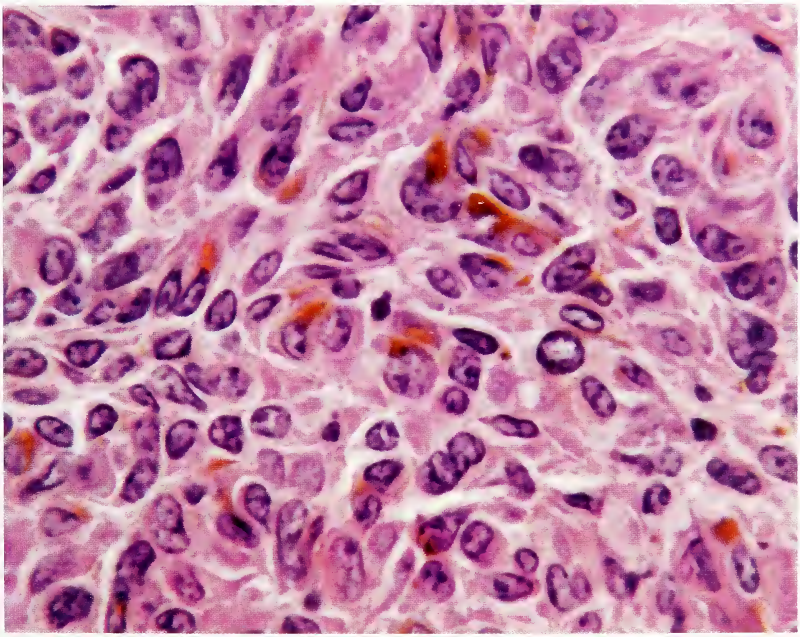

B

PLATE I

Harding-Passey Melanoma. Mouse

DEFINITION. A melanoma that arose spontaneously in a non-inbred mouse.

HISTORY AND DESCRIPTION OF ORIGINAL TUMOR. The Harding-Passey Melanoma was found on the left ear of a brown stock mouse in August 1925, in the laboratory of R. A. Passey of the Leeds University Medical School, Leeds, England. It appeared as a sessile, lobulated, black mass, somewhat smaller than a grain of wheat. About six weeks later, a biopsy of the lesion was transplanted elsewhere in the same mouse but failed to grow. The primary tumor continued to enlarge slowly until at necropsy, a year later, it had more than regained its original size. It had the color of a dark grape, and the overlying skin was taut, shiny, and transparent. The cut surface of the tumor was the color of India ink. There was an enlarged dark lymph node in the left cervical region. The only other abnormality revealed at necropsy was ascites, attributed to a large Cysticercus fasciolaris cyst of the liver.

Microscopically, the pigmented tumor occupied the subcutaneous tissue of virtually the entire pinna, and in one area it separated the cartilage plates. It did not, however, infiltrate cartilage or epidermis.

Two types of cell were present in the tumor, a neoplastic cell and a phagocyte. The neoplastic cell varied moderately in size and shape and had an average diameter of 10 microns. The cytoplasm was slightly basophilic and contained granules of pigment that were located in the peripheral portion of the cell. The large and clear nucleus was unobscured by the pigment. There were many mitotic figures. The connective tissue stroma of the tumor was not abundant.

The large phagocyte was round or polygonal, had an average diameter of 28 microns, and was more numerous than the neoplastic cell. The nucleus was round, rarely multiple, and smaller than that of the tumor cell. Phagocytic cells in mitosis were not observed. The cytoplasm was usually filled with fine, granular, dark brown pigment. The pigment, however, was not confined to the phagocytic and the neoplastic cells, but it was also present in the endothelium of the lymphatic and blood vessels. Extracellular pigment granules were present chiefly among the collagenic fibers of the stroma. Only cells containing pigment were said to be dopa positive. Histologic examination of the dark-colored cervical lymph node, thought at necropsy to contain a metastasis, revealed pigment-containing phagocytes but no tumor cells.

TRANSPLANTATION STUDIES. Harding and Passey used brown stock mice of mixed breed in their transplantation studies. The tumor was brought to New York City in 1928 by James B. Murphy of the Rockefeller Institute, and since then has been studied by a number of investigators in different laboratories in this country. It has been transplanted subcutaneously in albino mice of the Rockland, Bagg, Carworth Farms, Swiss, and Paris strains, as well as in the C57BL, DBA, C3H, and Agouti (New York) strains of mice.

Sugiura found that the tumor transplants grew successfully in 95 percent of 1,500 mice inoculated during 72 transplant generations, and only 3 percent of the transplants regressed. The tumor was transplanted subcutaneously every 30 days, usually by the trocar technic. It was found to be of palpable size three weeks following inoculation and reached an average diameter of 5 cm. at 16 weeks, at which time it was usually ulcerated. The tumor killed the host in about five months. Death was attributed to sepsis and nutritional failure. The growth of the transplanted tumor was not influenced by the age of the host or by castration. The regional lymph nodes of mice bearing subcutaneous transplants were occasionally deeply pigmented, but since transplants of such lymph nodes did not yield tumors, the pigmented areas were not considered to be neoplastic. This dark appearance of the regional lymph nodes was attributed to melanin-containing phagocytes. Such phagocytes were also found in the liver and spleen and occasionally in the lungs. Large amounts of pigment, presumably melanin, might be detected in the urine and feces of the host.

Sugiura stated in a personal communication that a suspension of tumor cells injected intraperitoneally into young adult mice produced multiple intra-abdominal tumor nodules that might metastasize to the lungs. He found that pulmonary metastasis occurred more often when the host was a suckling mouse.

In England, most of the early transplant tumors grew slowly, reaching a diameter of several centimeters six months after inoculation. The color of the transplant tumors varied from dark to light gray, and isolated areas of pale tumor tissue were found in some of them. Harding and Passey developed a line of grossly amelanotic tumor by selecting pale areas for transplantation. The lightly pigmented variant grew more rapidly than the deeply pigmented tumor. The degree of pigmentation of the tumor was not related to the coat color of the host mouse. In 1954 Sugiura confirmed this observation. He was able to develop a nonpigmented variant of the Harding-Passey Melanoma by selectively transplanting pale areas that first appeared in a tumor of the 130th generation. The transformed tumor grew slowly and differed from the original pigmented melanoma only in that it did not contain demonstrable melanin.

DESCRIPTION OF CURRENT TUMOR. A subcutaneous transplant of the present Harding-Passey Melanoma reaches an average diameter of 1.5 cm. five or six weeks after inoculation. It is firm, sharply circumscribed, and encapsulated. Some tumors are uniformly black, while others contain pale areas. The cut surface exudes a thin, glistening, mucoid material.

When either the Harding-Passey Melanoma or the Cloudman Melanoma S91 is grown in the transparent window following the technic of Algire, there is a minimal vascular reaction around the tumor. This is in contrast to the extreme dilatation of vessels around many transplantable sarcomas and carcinomas grown under similar conditions.

Microscopically, the Harding-Passey Melanoma is composed of sheets, whorls, and interlacing bundles of spindle-shaped and round cells (figs. 17, 18). Fascicle formation is most prominent in the peripheral part of the tumor, whereas whorl formation is seen more often in the central area. Each whorl has a central blood vessel. The transplanted tumor, like the primary tumor, contains two types of cell—the neoplastic cell or melanoblast, and the phagocytic cell or melanophore.

The melanoblast constitutes 50 to 80 percent of the tumor. It varies in form from an elongated spindle-shaped cell to a nearly round cell 15 to 20 microns in diameter. The cytoplasm is somewhat basophilic and vacuolated and contains pigment and nonpigmented granular material (pl. I–B). Most of the nuclei are the same size and shape. The deeply colored nuclear membrane encloses a fine linin meshwork and a few clumps of chromatin that are distributed along its inner aspect. The nucleus of the melanoblast contains three distinctive structures: (1) a small deeply basophilic granule generally located at the intersection of the linin threads; (2) a large irregularly shaped, round, oval, or elongated structure that stains grayish blue in the hematoxylin—eosin preparation, but stains deep red if the section has first been bleached with potassium permanganate; (3) a round structure, intermediate in size and deeply basophilic, that is a satellite of the second large intranuclear structure. Mitotic figures are most numerous in the peripheral part of the tumor where they may number three per oil immersion field. A minority of the melanoblasts contains pigment. Its distribution in the cytoplasm may be perinuclear, peripheral, or diffuse. The cytoplasm of the pigment-containing tumor cells is often uniformly brown in the hematoxylin and eosin preparation. Woods and associates studied living cells and described melanin and nonmelanized granules in the cytoplasm of the dentritic processes and in the cytoplasm surrounding the nucleus.

The phagocytic melanophores are distributed throughout all portions of the Harding-Passey Melanoma. They are exceedingly numerous in the center of it, where they are clustered around the small areas of necrosis. The phagocyte varies in size, shape, and appearance, depending upon the amount of intracellular pigment. The pigment occurs in dense irregular clumps and frequently obscures the nucleus. The outline of the phagocytic cell is delimited by its content of pigment. The cell membrane, previously indistinct, becomes discernible in stained preparations previously bleached with potassium permanganate. The nucleus is small, round, and appears to have been compressed by the pigment.

The reticulum occurs as fine or coarse twisted strands that surround single neoplastic cells, or groups of 6 to 10 cells. Fibrous connective tissue is scanty, and there are few collagenic fibrils. In Wilder's silver preparations, certain cells heavily impregnated with silver appear to be anatomically related to the reticular fibrils (figs. 19, 20). These cells resemble the metalophil cells de-

HARDING-PASSEY MELANOMA. MOUSE

(Tumor-bearing animal courtesy of Dr. G. H. Algire, National Cancer Institute, Bethesda, Md.)

Figure 17. Photomicrograph of transplant tumor. The tumor cells are arranged in whorl formation. Each whorl is surrounded by melanophages. Hematoxylin and eosin stain. X 80. N. C. I. 7806; A. F. I. P. Acc. No. 219934–17.

Figure 18. Photomicrograph of transplant tumor. The central part of the illustration shows a single whorl with a small central vessel containing erythrocytes. The nuclei of the metalophil cells are small and dark. Hematoxylin and eosin stain. X 480. N. C. I. 7826; A. F. I. P. Acc. No. 219934–18.

Figure 19. Photomicrograph of transplant tumor. Both the cytoplasm and the nucleus of the metalophil cells are blackened by silver. Wilder's silver preparation. X 830. N. C. I. 9060; A. F. I. P. Acc. No. 219934–19.

Figure 20. A lower power photomicrograph of transplant tumor showing the number and distribution of the metalophil cells that are blackened by silver. Note relationship between the reticular fibers and the metalophil cells. Wilder's silver preparation. X 420. N. C. I. 9063; A. F. I. P. Acc. No. 219934–20.

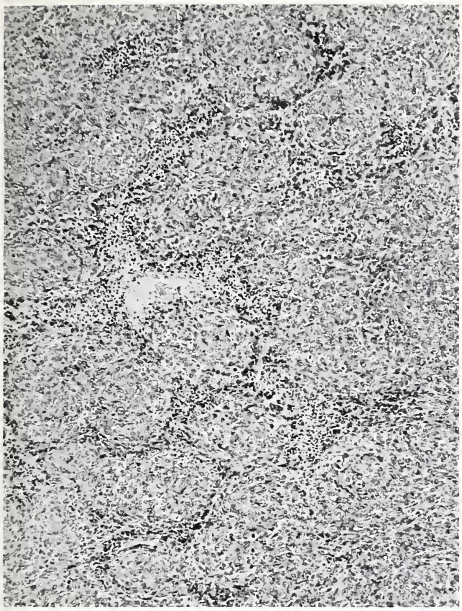

Fig. 17

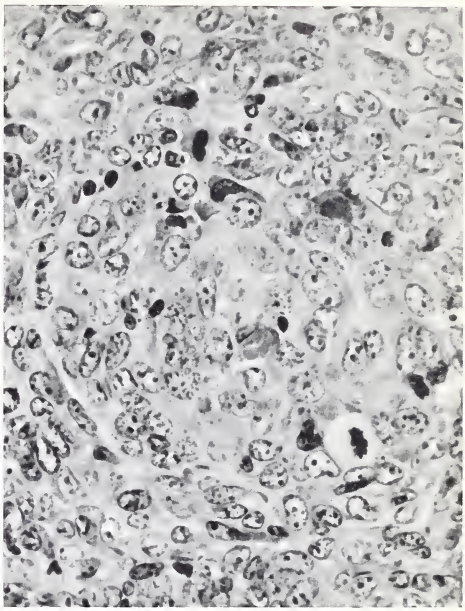

Fig. 18

Fig. 19

Fig. 20

scribed as part of the reticuloendothelial system by Marshall and others. Most of them are small and crescentic in outline. They have branched dendritic processes that appear to be continuous with the reticular fibers, and sometimes these dendrites surround a melanoblast. The nuclei of these metalophil cells are small, oval, centrally located, and hyperchromatic in hematoxylin and eosin stained sections. The nuclei are obscured in the silver preparations. More metalophil cells are found in the whorled areas than in other parts of the tumor. A very few of them may be filled with granules of melanin. These metalophil cells are considered to represent the precursors of the melanophores of the tumor.

References

Algire, G. H., and Legallais, F. Y. Growth and vascularization of transplanted mouse melanomas. In: Biology of Melanomas. New York Acad. Sc., (Special publ.), 4:159–170, 1948.

Greenstein, J. P. Chemistry of melanomas. In: Biology of Melanomas. New York Acad. Sc., (Special publ.), 4:433–436, 1948.

Harding, H. E., and Passey, R. D. A transplantable melanoma of the mouse. J. Path. & Bact., 33: 417–427, 1930.

Marshall, A. H. E. The reticular tissue and the "reticuloendothelial system." J. Path. & Bact., 65: 29–48, 1953.

Sugiura, K. The effects of various physical and chemical factors on transplantable mouse melanoma. In: Biology of Melanomas. New York Acad. Sc., (Special publ.), 4:369–387, 1948.

Woods, M. W., DuBuy, H. G., Burk, D., and Hesselbach, M. L. Cytological studies on the nature of the cytoplasmic particulates in the Cloudman S91 mouse melanoma, the derived Algire S91A partially amelanotic melanoma, and the Harding-Passey mouse melanoma. J. Nat. Cancer Inst., 9:311–323, 1949.

TUMORS OF SUBCUTANEOUS TISSUES

Earle L Fibrosarcoma. Mouse

SYNONYMS: Earle L Sarcoma; L Sarcoma; Fibrosarcoma Earle L.

DEFINITION. A fibrosarcoma derived from an explant of the subcutaneous tissue of a C3H mouse grown in tissue culture medium to which 20-methylcholanthrene had been added.

HISTORY AND DEVELOPMENT OF THE TUMOR. On October 18, 1940, Earle planted strips of subcutaneous tissue excised from a 100-day-old male C3H mouse (Andervont substrain) in a tissue culture flask containing horse serum—chick embryo extract in saline solution. He maintained transfer cultures of the original explant in this medium until November 1941. At that time, approximately one microgram of 20-methylcholanthrene per ml. of culture medium was added to the culture. The cells were propagated in this medium containing 20-methylcholanthrene until March 26, 1942. By that time, the cells had been exposed to methylcholanthrene for 111 days. The L line of cells represents one of several lines of cells derived from this carcinogen-treated culture and designated by letters of the alphabet. The L line of cells was then explanted to a methylcholanthrene-free medium in which the cells grew for an additional 68 days, or until June 2, 1942.

The cells of the L line were then injected by syringe and needle into the dorsal muscles of young male mice of the C3H/An strain. Tumors grew at the site of inoculation in many of the host mice, and pieces of them were transplanted to other hosts of the same strain. Thus the Earle L Fibrosarcoma originated.

A major part of the explant of the original strip of subcutaneous tissue planted in vitro in 1940 consisted of fat cells. Earle described the growth of this explant in tissue culture as luxuriant and uniform, although somewhat loose. Forty-two days after the original subcutaneous tissue was placed in tissue culture, the first tissue culture transfer was made. The first explant then measured 18 mm. in width. Subsequent transfers were made at 63, 43, 39, and 30 days, corresponding to the 6th tissue culture generation (May 22, 1941), and thereafter as necessary. The number of cells containing fat droplets, numerous in the beginning, diminished, until by the 3rd generation, entire cultures were often almost free of them. This was considered by Earle to be normal for growing fibroblasts.

Both the L strain cells exposed to the carcinogen for 111 days and the cells grown in the medium free of carcinogen exhibited a growth pattern and cyto-

logical changes considered by Earle to be characteristic of malignant neoplasia. The timing, character, and possible causes of the neoplastic change in both the experimental and control cultures, and much other information relating to this experiment, are presented at length in the articles by Earle and his co-workers. Gey had previously obtained a neoplastic change in cultures of subcutaneous tissues to which no carcinogen had been added. However, Earle believed that his own control cultures, grown parallel with the L strain of cells, had been accidentally contaminated with carcinogen. More recently, however, Sanford and her associates in Earle's laboratory have shown that untreated subcutaneous tissue cultured without the addition of methylcholanthrene produced tumors when inoculated into host mice, thus indicating that normal untreated subcutaneous tissue may acquire malignant neoplastic properties spontaneously in vitro. Goldblatt and Cameron have found that the conversion of normal to neoplastic cells in tissue culture may be accelerated by intermittent anaerobiosis. Leighton has observed the neoplastic conversion of fibroblasts from human foreskin grown in tissue culture, indicating that this phenomenon is not confined to the tissues of laboratory animals.

It has been presumed by Earle that the L Sarcoma and other neoplasms developed in this experiment arose from fibroblasts. However, the fragment of subcutaneous tissue from which the original cultures were started doubtless contained other cells in addition to fibroblasts. There might have been primitive cells with unknown potentialities for differentiation: fat cells, endothelial cells, histiocytes, myocytes, or Schwann cells. Hence the exact cell of reference for each of the neoplasms in this experiment of Earle is by no means established.

The more recent work of Sanford and associates (1954) has demonstrated that tissue cultures may be grown successfully from a single isolated cell, a feat that had hitherto not been accomplished. Tremendous possibilities may be inherent in this technic. In theory, by systematically isolating identified cells from different tissues and growing them in tissue culture, our knowledge of the histogenesis of tumors that might arise from a single tissue cell would be enhanced.

The tumors that developed in the first mice inoculated intramuscularly with the line L tissue cultures were round, firm, nodular, deeply seated masses. Different lines of the L cells maintained in tissue culture grew successfully as tumors in 5 to 90 percent of the host mice inoculated. Upon subsequent repeated transplantation of these tumors into C3H/An mice, the tumors grew successfully in nearly 100 percent of the inoculated hosts. These later tumors were not encapsulated and varied in size, some exceeding 3 cm. in diameter. On section, such tumors had a large central area of necrosis surrounded by a zone of firm pinkish tumor tissue. Local invasion and occasional metastatic growths in the lung were observed. Nettleship and Earle described the early tumor as showing some variability of cell size and pattern, with giant cells

and abnormal mitoses. They designated the tumor as a fibrosarcoma. At the present time, subcutaneous transplants of Earle's L Sarcoma become palpable within 5 to 10 days after inoculation in C3H/An mice. They grow progressively and kill the host animal in about two months.

DESCRIPTION OF CURRENT TUMOR. A 1-month-old intramuscular transplant of the Earl L Fibrosarcoma is irregularly shaped, soft, glistening, pinkish gray, and measures 15 mm. in its greatest diameter. Thin prolongations of tumor tissue extend several millimeters beyond the main tumor mass. On section, the central third of the tumor consists of necrotic tissue.

The peripheral aspects of the tumor are demarcated for the most part from the surrounding host tissue, but the tumor tissue infiltrates the skeletal muscle, and a few degenerated muscle fibers are included within the neoplasm. There is little inflammatory reaction. The tumor is composed of cells that are fairly uniform in size, shape, and staining capacity (fig. 21). They are tightly packed, forming sheets, interlacing bundles, and whorls of cells that show little palisading. The tumor cells are usually elongated, and some are spindle shaped (figs. 22, 23). The nuclei are generally the same in size and staining capacity and have an average diameter of 20 microns. They are oval, elongated, or round, and deeply hyperchromatic due to the large number of chromatin granules and the heavily stained nuclear membrane. One to five rounded or irregularly-shaped nucleoli can be found in each nucleus.

The cells of the L Fibrosarcoma possess a large amount of cytoplasm. This is lightly basophilic and frequently fibrillar, as revealed in the phosphotungstic acid—hematoxylin stain (fig. 23). The cell membrane is distinctly colored (fig. 24). As many as 10 mitotic figures may be observed in each high power field, and they are usually of normal appearance. The blood vessels of the viable portion of the tumor resemble capillaries and are not numerous. In the areas of degeneration and necrosis the vessels are dilated, and there is frequent hemorrhage.

The tumor contains only a limited number of reticular and collagenic fibers, as demonstrated by the silver methods of Wilder and Bielschowsky and by van Gieson's technic. These fibers are most numerous in the region of the small blood vessels from which they extend outward for a short distance between the cells. Most of the tumor tissue at a distance from the vessels is therefore free of reticular and collagenic fibers. In most parts of the tumor, individual cells not closely associated with their neighbors are surrounded by a fine fibrillar network that consists of material colored pale blue with Mallory's aniline blue, brown with phosphotungstic acid—hematoxylin (fig. 24), bright red in the periodic acid—Schiff reaction, and green with Masson's trichrome stain. The nature of this network that is colored by many stains but not blackened by silver is not understood. Numerous fine fibroglial fibrils that lie parallel to the long axis of the cell may be found in many parts of the tumor stained with phosphotungstic acid—hematoxylin. These fibroglial

EARLE L FIBROSARCOMA. MOUSE

(Tumor-bearing animal courtesy of Dr. J. M. Weaver, National Cancer Institute, Bethesda, Md.)

Figure 21. Photomicrograph of transplant tumor. This shows an area composed of cells arranged in sheets, interlacing bundles, and whorls. There are several areas of necrosis. Hematoxylin and eosin stain. X 105. N. C. I. 8292; A. F. I. P. Acc. No. 219934-21.

Figure 22. This photomicrograph of the transplant tumor shows nuclei that are deeply hyperchromatic. There are numerous mitotic figures. Hematoxylin and eosin stain. X 950. N. C. I. 8299; A. F. I. P. Acc. No. 219934-22.

Figure 23. Photomicrograph of an area of the transplant tumor composed chiefly of spindle-shaped cells. Fine fibroglial fibers are present. Phosphotungstic acid—hematoxylin stain. X 880. N. C. I. 9282; A. F. I. P. Acc. No. 219934-23.

Figure 24. In this photomicrograph of the transplant tumor long collagenic fibers are present, and fine fibrils surround many of the cells. The cell membrane is distinctly outlined. Phosphotungstic acid—hematoxylin stain. X 430. N. C. I. 9284; A. F. I. P. Acc. No. 219934-24.

Fig. 21

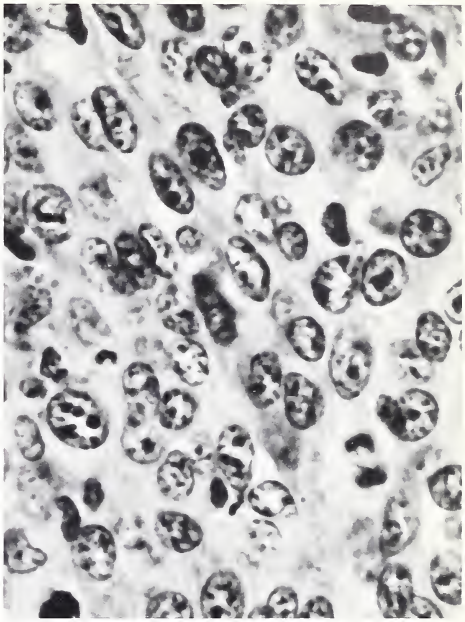

Fig. 22

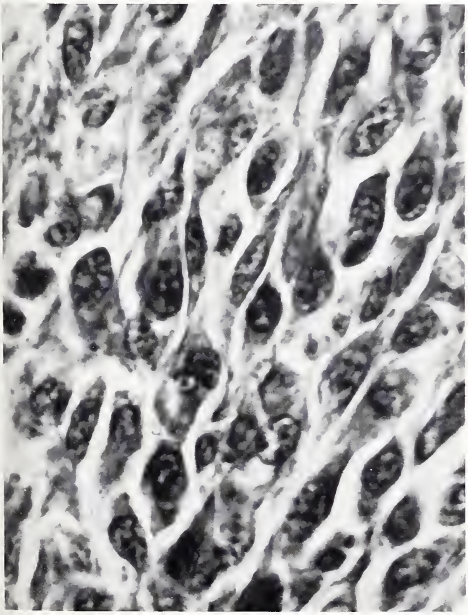

Fig. 23

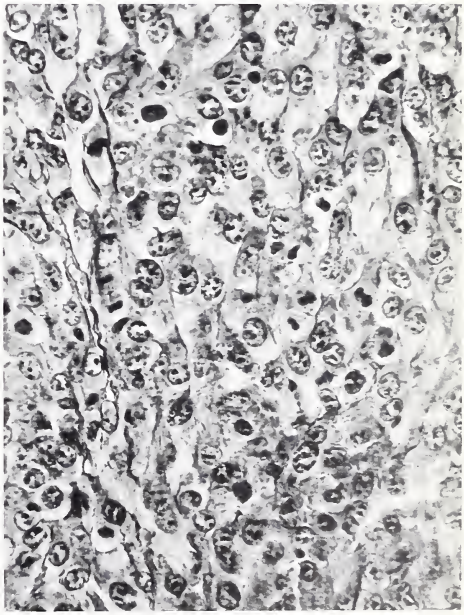

Fig. 24

fibrils appear to be most numerous in areas showing degenerative changes. It is our opinion that the classification of the Earle L tumor as a fibrosarcoma is justified.

References

Earle, W. R. Production of malignancy in vitro. IV. The mouse fibroblast cultures and changes seen in the living cells. J. Nat. Cancer Inst., 4:165–212, 1943.

———, and Nettleship, A. Production of malignancy in vitro. V. Results of injections of cultures into mice. J. Nat. Cancer Inst., 4:213–227, 1943.

Gey, G. O., Gey, M. K., Firor, W. M., and Self, W. O. Cultural and cytologic studies on autologous normal and malignant cells of specific in vitro origin. Conversion of normal into malignant cells. Acta Unio internat. cancr., Louvain, 6:706–712, 1949.

Goldblatt, H., and Cameron, G. Induced malignancy in cells from rat myocardium subjected to intermittent anaerobiosis during long propagation in vitro. J. Exper. Med., 97:525–552, 1953.

Leighton, J., Kline, I., and Orr, H. C. Transformation of normal human fibroblasts into histologically malignant tissue in vitro. Science, 123:502–503, 1956.

Likely, G. D., Sanford, K. K., and Earle, W. R. Further studies on the proliferation in vitro of single isolated tissue cells. J. Nat. Cancer Inst., 13:177–184, 1952.

Nettleship, A., and Earle, W. R. Production of malignancy in vitro. VI. Pathology of tumors produced. J. Nat. Cancer Inst., 4:229–248, 1943.

Sanford, K. K., Earle, W. R., and Likely, G. D. The growth in vitro of single isolated tissue cells. J. Nat. Cancer Inst., 9:220–246, 1948.

———, Earle, W. R., Shelton, E., Schilling, E. L., Duchesne, E. M., Likely, G. D., and Becker, M. M. Production of malignancy in vitro. XII. Further transformations of mouse fibroblasts to sarcomatous cells. J. Nat. Cancer Inst., 11:351–375, 1950.

———, Hobbs, G. L., and Earle, W. R. The tumor-producing capacity of strain L mouse cells after 10 years in vitro. Cancer Research, 16:162–166, 1956.

———, Likely, G. D., and Earle, W. R. The development of variations in transplantability and morphology within a clone of mouse fibroblasts transformed to sarcoma-producing cells in vitro. J. Nat. Cancer Inst., 15:215-237, 1954.

Myofibrosarcoma HS–6. Hamster

SYNONYM: Sarcoma HS–6.

DEFINITION. A myofibrosarcoma induced in a Syrian hamster by the subcutaneous injection of 9, 10-dimethyl-1, 2-benzanthracene.

HISTORY AND DESCRIPTION OF ORIGINAL TUMOR. This sarcoma was induced by multiple injections of a solution of 9, 10-dimethyl-1,2-benzanthracene into the subpanniculus of the middorsal lumbar region of a female hamster* in 1944 in the laboratory of E. D. Crabb at the University of Colorado at Boulder.

*F. Homburger and A. Tregier (Tufts Medical School, Boston) have called our attention to a sarcoma (leiomyosarcoma HT–1) that developed in the left flank of a hamster that had been inoculated subcutaneously with a cholesterol pellet eight months previously. However, the site of implantation of the pellet could not be correlated with the location of the tumor. It is interesting that this tumor has grown successfully in all animals inoculated for more than 40 generations but has shown no change in its histologic pattern. Hamsters bearing the transplanted tumor die within 3 to 5 weeks after inoculation, with metastases usually in the lungs and occasionally in the peritoneum, kidneys, adrenal glands, and mediastinum.

The solution was prepared by dissolving 20 mg. of the dimethylbenzanthracene in 10 cc. of a solution of equal parts of olive oil and benzene. Four doses (either 0.10 or 0.16 cc.) of this solution were injected into the subpanniculus of each of four hamsters during a period of less than three weeks. All four animals developed tumors. A local tumor that developed in one animal within three months of the first injection was transplanted for a number of generations. Several sublines were developed by transplantation of bits of tissue obtained either from subcutaneous transplant tumors or from renal or pulmonary metastases. Eventually, all but one subline were discontinued and this one was designated by Crabb as "first generation transplant HS–6." On April 4, 1954, Myofibrosarcoma HS–6 was in its 117th transplant generation.

There is no separate description of the primary tumor from which the transplant tumor line HS–6 was derived. Crabb made some general remarks about the tumors that developed in the four treated animals. He did state, however, that he considered the HS–6 to be a mixed cell tumor, primarily of fibroblastic derivation.

TRANSPLANTATION STUDIES. Crabb found that the latent period of growth of Sarcoma HS–6 was rather closely related to the volume of the tissue transplanted. Thus, if the volume of the inoculum was optimum he found that growth could be obtained as readily with tumor tissue that appeared necrotic on gross examination as it could with tumor tissue that appeared viable. Such transplants grew progressively in nearly 100 percent of the hosts. The latent period usually varied from 4 to 10 days. If blood-tinged fluid from incised solid tumors was used for injection, the latent period was increased slightly, and the tumor grew in only 50 percent of animals inoculated.

The tumor-bearing host generally died within 28 days following inoculation. Subtotal removal of the tumor prolonged the life of the animal and allowed time for the development of metastases. Of 345 such animals surviving 100 days following inoculation, 33 percent had metastases in the lungs, in the axillary lymph nodes, or more frequently in the inguinal lymph nodes. Metastases were occasionally observed in the kidney and pancreas, but not in the liver. The metastatic tumors in the lung, which were found in nearly 15 percent of these animals, consisted of multiple scattered nodules of nearly uniform size and shape, suggesting simultaneous dissemination. (Many of these data were kindly given us by Dr. E. D. Crabb of the University of Colorado, Boulder, Colo.)

DESCRIPTION OF CURRENT TUMOR. The transplanted subcutaneous tumor undergoes necrosis early, so that growths 2.5 cm. or more in diameter consist of a thin rim of viable white or gray tissue surrounding an orange to brown necrotic, partially liquefied, central area.

The viable areas of Myofibrosarcoma HS–6 are composed of fascicles of spindle-shaped cells interspersed with areas of loosely arranged cells (figs.

25, 26). The neoplastic cells reveal pronounced variation in size, shape, and staining characteristics. The fasciculi may course in all directions and are composed of an abundant collagenous and reticular framework in which are enmeshed spindle-shaped cells (fig. 27). The long axes of these cells are regularly oriented in the same general direction within any given bundle. Their processes interdigitate with one another. Fibroglia may be demonstrated by appropriate stains. The spindle-shaped cells may be small and often resemble fibroblasts. Some of the cells are large and plump and resemble smooth muscle cells. The cytoplasm is faintly basophilic and homogeneous. The nucleus is elongated, its membrane is deeply colored, and it contains clumps of chromatin and a fine linin mesh. Mitotic figures are infrequently seen and appear normal in form.

The fasciculi of spindle-shaped cells divide the tumor into irregular compartments containing bizarre tumor cells. These latter cells are pleomorphic and have no specific arrangement and no organized pattern. They measure 40 to 80 microns in width and often twice that in length. Although many of the bizarre cells are polyhedral, most of them possess at least four elongate processes, the terminal portions of which are not always contained within the plane of the section. The cell membrane is distinct. The cytoplasm is abundant, markedly acidophilic, and although usually homogeneous, may contain fine granules often dispersed more or less uniformly. The body and the processes of these bizarre cells often contain intracellular myofibrils as revealed by phosphotungstic acid—hematoxylin and iron alum hematoxylin stains. These myofibrils are beaded but lack demonstrable coincident cross striations (fig. 28). The nucleus is generally large, and the nuclear cytoplasmic ratio often seems to be greater than one to one. Most cells have 1 nucleus, although a few contain 2 or 3 nuclei. The nucleus is generally eccentric in position, irregular in outline, and occasionally lobate. The nuclear membrane is dense and encloses a delicate chromatin mesh. From 1 to 4 large, faintly basophilic, irregular, or elliptical nucleoli are present. As many as 10 mitotic figures may be found in a single high power field, with a high proportion of tripolar or irregular bar forms.

Necrosis is extensive and occurs in large and small areas. Spindle-shaped cells may survive within the areas of necrosis. Blood vessels are usually small, thin walled, and not numerous. Some may show endothelial hyperplasia, and others are dilated and irregular in shape. At the periphery of the transplant, the tumor tissue infiltrates the panniculus carnosus and invades the subcutaneous connective tissue. There is little or no evidence of the establishment of a capsule that would form any sort of barrier to the extension of growth of the tumor. The subcutaneous connective tissue in the region of the spreading tumor shows pronounced edema and a sparse inflammatory cell infiltration.

In view of the obvious fibromatous and myxomatous components of this tumor, together with the original opinion of Crabb that he was dealing with a mixed cell tumor primarily of fibroblastic origin, HS–6 is classified as a myofibrosarcoma.

References

Crabb, E. D. A transplantable 9, 10-dimethyl-1, 2-benzanthracene sarcoma in the Syrian hamster. Cancer Research, 6:627–636, 1946.

———. Relation of duration of a transplanted sarcoma to metastasis in the hamster. J. Nat. Cancer Inst., 10:581–596, 1949.

Kelsall, M. A. Hematopoiesis in the spleen of tumor-bearing hamsters. J. Nat. Cancer Inst., 10:625–636, 1949.

Liposarcoma D4888. Guinea Pig

DEFINITION. A liposarcoma induced in the subcutaneous tissue of an inbred guinea pig by the injection of methylcholanthrene.

HISTORY AND DESCRIPTION OF ORIGINAL TUMOR. Liposarcoma D4888 was induced experimentally in 1945 in the laboratory of W. E. Heston at the National Cancer Institute, Bethesda, Maryland. A dose of 20 mg. of 20-methylcholanthrene in sesame oil was injected subcutaneously in a 5-month-old male guinea pig of Family 2. The guinea pig was killed 18 months later, and two tumors were present beneath the skin at the site of inoculation. The tumors were soft, yellow, and apparently encapsulated. On section, the tumor tissue was semisolid or firm and bulged above the surrounding tissue.

Since the histologic pattern and appearance of the cells of the primary tumor (figs. 29, 30) and of the 90th generation transplant tumor are in general similar, only points of difference are noted. The blood vessels of the primary tumor are more numerous and more dilated, and necrosis is less extensive than in the 90th generation transplant. In paraffin sections stained with hematoxylin and eosin, the cytoplasmic vacuoles of the cells of the primary tumor are larger, less numerous, and less frequently located peripherally than those of the transplant. There are many more signet ring cells in the original tumor.

TRANSPLANTATION STUDIES. Liposarcoma D4888 has been maintained in Family 2 guinea pigs by subcutaneous transplantation at 30 day intervals. From the outset, the transplant tumor grew successfully in 100 percent of the hosts, with no regressions. The tumor becomes palpable within 10 days and kills the host in approximately five weeks. In September 1954, the tumor was in its 111th transplant generation. (Many of these data were obtained in personal interview with Dr. W. E. Heston of the National Cancer Institute, Bethesda, Md.)

DESCRIPTION OF CURRENT TUMOR. A 30-day-old subcutaneous transplant tumor of the 90th generation measures 15 x 8 x 6 cm. The surface of the tumor appears coarsely nodular and pinkish gray or yellow. On section, the

MYOFIBROSARCOMA HS-6. HAMSTER

(Fixed tissue courtesy of Dr. E. D. Crabb, University of Colorado, Boulder, Colo.)

Figure 25. Photomicrograph of transplant tumor. This shows the interlacing bundles of spindle-shaped cells and the loosely arranged more atypical cells. There is invasion of skeletal muscle in the upper left hand corner of the section. Hematoxylin and eosin stain. X 112. N. C. I. 8585; A. F. I. P. Acc. No. 219934-25.

Figure 26. Photomicrograph of transplant tumor. This shows in greater detail the contrast between the spindle-shaped cells and the more atypical cells. Hematoxylin and eosin stain. X 250. N. C. I. 8556; A. F. I. P. Acc. No. 219934-26.

Figure 27. Photomicrograph of transplant tumor. Almost all the large atypical cells are surrounded by reticular fibers. Note that the reticular fibers are parallel in the interlacing bundles of cells. Wilder's silver preparation. X 250. N. C. I. 8558; A. F. I. P. Acc. No. 219934-27.

Figure 28. High power photomicrograph of transplant tumor. The bizarre neoplastic cells are illustrated in detail. Note the intracytoplasmic fibrils. Phosphotungstic acid—hematoxylin stain. X 1790. N. C. I. 8563; A. F. I. P. Acc. No. 219934-28.

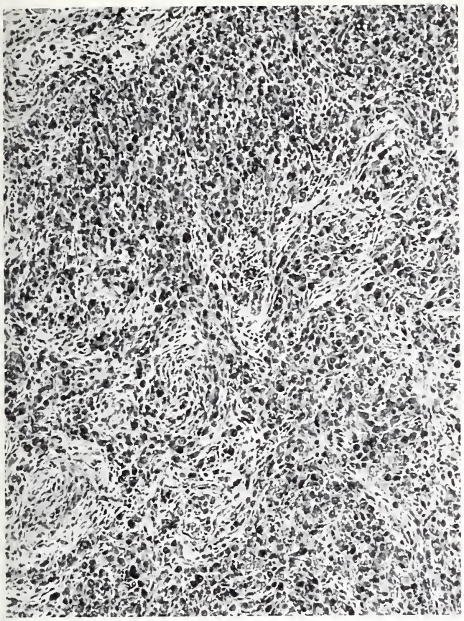

Fig. 25

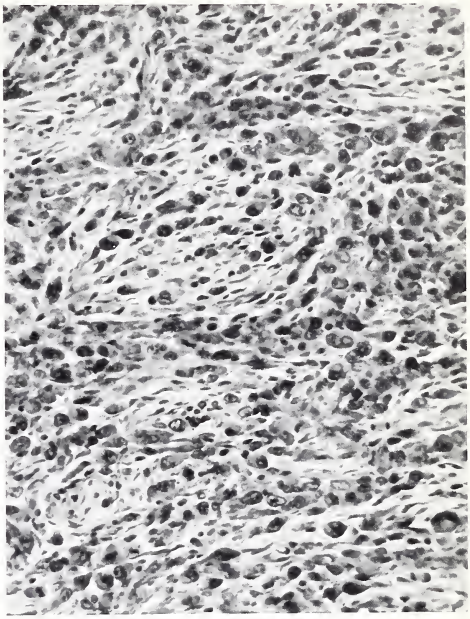

Fig. 26

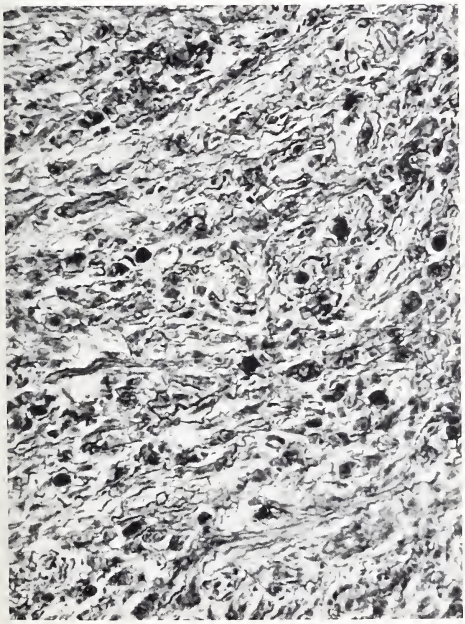

Fig. 27

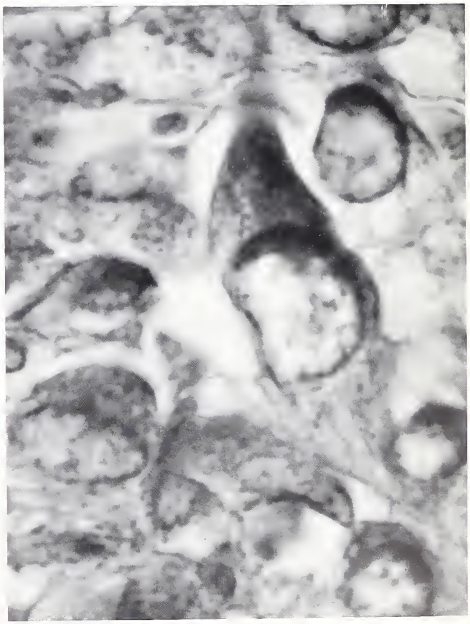

Fig. 28

tumor is lobulated, friable, hemorrhagic, and extensively necrotic. Two circumscribed grayish yellow metastases, 2 mm. in diameter, are present in the lung.

Upon histologic examination, more than 90 percent of the tumor is found to be necrotic. The viable tissue is located chiefly in the peripheral region of the tumor, although even here some necrotic areas are present. The tumor is demarcated from the surrounding tissue of the host by a thin capsule of connective tissue that is infiltrated with neoplastic cells at various points. The tumor is divided into fine or coarse lobules by septa of mature connective tissue that often contain thin-walled blood vessels (fig. 31).

The neoplastic cells of Liposarcoma D4888 are round or polygonal in shape and fairly uniform in size and appearance (fig. 32). Most of the tumor cells measure 25 microns in diameter and possess one nucleus. There are a few scattered giant tumor cells that are multinucleated or have a multilobed nucleus. Such giant cells are 2 or 3 times larger than the other tumor cells. The nucleus of most of the tumor cells is round or oval with a deeply stained nuclear membrane that encloses 1 to 5 basophilic nucleoli and heavily stained chromatin granules (fig. 33). The nuclei are colored bright orange with Mallory's aniline blue stain. As many as a dozen mitotic figures may be found in a single high power field, and they are frequently atypical and bizarre in form.

The tumor cells have a large amount of cytoplasm and a well defined cell membrane. The cytoplasm may be granular or vacuolated. The granular portion of the cytoplasm may be acidophilic or slightly basophilic in its staining capacity. The vacuoles vary in size and are usually located in the peripheral cytoplasm. Some of them displace the nucleus so much that the cell resembles a signet ring cell.

Frozen sections stained with Sudan IV (oil red 0) reveal a large amount of stainable lipoid usually in the form of fine granules and droplets in the periphery of the cytoplasm of the viable tumor cells (fig. 34). The necrotic portion of the tumor contains little fat. A small amount of doubly refractile lipoidal material chiefly in the form of small needle-shaped crystals is found in association with the stainable lipoid.

Two types of cytoplasmic inclusion bodies occur. These are present both in resting intermitotic and in mitotic tumor cells. The number of tumor cells containing inclusion bodies varies considerably in different parts of the tumor, with large areas free of them. The largest but least numerous type of inclusion body measures roughly 8 microns in diameter, is deeply eosinophilic, and is colored bright red in periodic acid—Schiff preparations. The second type of inclusion body is spherical and homogeneous and varies from 3 to 6 microns in diameter. The coloring reaction of this latter inclusion body resembles closely that of the red blood cell with the periodic acid—Schiff reaction and

in the Wilder silver preparations, as well as with the iron hematoxylin, Mallory's aniline blue, hematoxylin—eosin, trichrome, and van Gieson's stains. However, in the phosphotungstic acid—hematoxylin stain in which the red blood cell is deep blue, this inclusion body is usually nearly colorless, or if it is stained at all, it is colored tan or gray. Even though the staining reaction of the inclusion body and the red blood cell may be similar in certain preparations, the two can usually be differentiated on the basis of other characteristics. The inclusion body is homogeneous throughout, is never crenated, never in rouleaux formation, and shows no evidence of disintegration with liberation of pigment as is the case with red blood cells.

Fine reticular fibers in continuity with the stroma surround single cells and small groups of tumor cells (fig. 35). In a given sheet of neoplastic cells, the reticular fibers are most prominent and numerous in its periphery, whereas they diminish centrad. Certain cells, considered not to be tumor cells, are found to be aligned along the reticular fibers. These cells evidently reduce silver more rapidly than the tumor cells for they are more intensely black. Their cytoplasmic processes are continuous with the reticular fibers. These cells may be called metalophil cells and are probably derived from reticuloendothelium. In the hematoxylin and eosin preparation, these metalophil cells can be recognized by their small, lightly colored nuclei that differ markedly from the larger, hyperchromatic nuclei of the tumor cells. The metalophil cells may contain phagocytosed material such as the debris of necrotic cells.

Few blood vessels are present in the tumor, and in areas of necrosis some of them contain thrombi. There are extensive areas of hemorrhage. As stated, the unit of the tumor may be said to be a sheet of cells surrounded by a thin strand of connective tissue stroma. Areas of necrosis are observed most frequently in the center of such a structural unit, whereas viable tumor tissue persists longest at the periphery and especially immediately around blood vessels. Necrotic cells are eosinophilic and deep red in periodic acid—Schiff preparations regardless of their location in sporadic foci or in large areas.

The metastatic tumor nodules of Liposarcoma D4888 in the lung reveal essentially the same characteristics as the subcutaneous transplant (fig. 36).

References

Heston, W. E., and Deringer, M. K. Induction of pulmonary tumors in guinea pigs by intravenous injection of methylcholanthrene and dibenzanthracene. J. Nat. Cancer Inst., 13:705–717, 1952.

Nadel, E. M., and Burstein, S. Urinary excretion of corticosteroids in guinea pigs with malignant neoplastic diseases. J. Nat. Cancer Inst., 17:213–220, 1956.

Shimkin, M. B., and Mider, G. B. Induction of tumors in guinea pigs with subcutaneously injected methylcholanthrene. J. Nat. Cancer Inst., 1:707–725, 1941.

Warren, S., and Gates, O. Spontaneous and induced tumors of the guinea pig. Cancer Research, 1:65–68, 1941.

LIPOSARCOMA D4888. GUINEA PIG

(Histologic sections of original tumor and animal bearing 90th generation transplant tumor courtesy of Dr. W. E. Heston, National Cancer Institute, Bethesda, Md.)

Figure 29. Photomicrograph of original tumor showing the pattern of growth and the appearance of vacuoles from which the fat has been dissolved. Hematoxylin and eosin stain. X 230. N. C. I. 8180; A. F. I. P. Acc. No. 219934–29.

Figure 30. Photomicrograph of original tumor. This shows the appearance of a multinucleated giant tumor cell. Hematoxylin and eosin stain. X 440. N. C. I. 8183; A. F. I. P. Acc. No. 219934–30.

Figure 31. Photomicrograph of 90th transplant generation tumor showing the lobular pattern and connective tissue septa. Hematoxylin and eosin stain. X 100. N. C. I. 8210; A. F. I. P. Acc. No. 219934–31.

Figure 32. Photomicrograph of 90th generation transplant tumor. The cells are round or polygonal and fairly uniform in size and shape. Note the numerous mitotic figures present in this field. Hematoxylin and eosin stain. X 440. N. C. I. 8693; A. F. I. P. Acc. No. 219934-32.

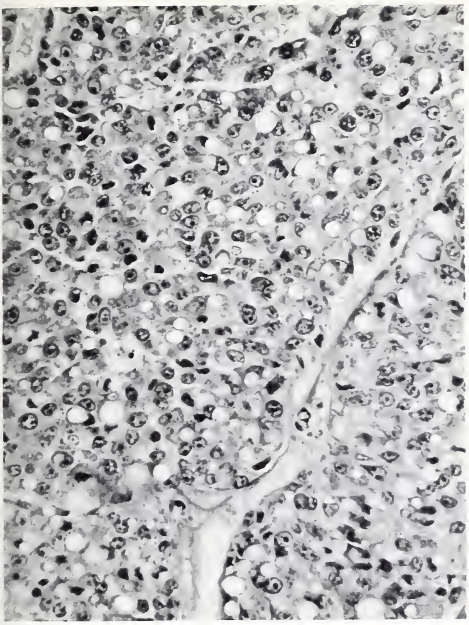

Fig. 29

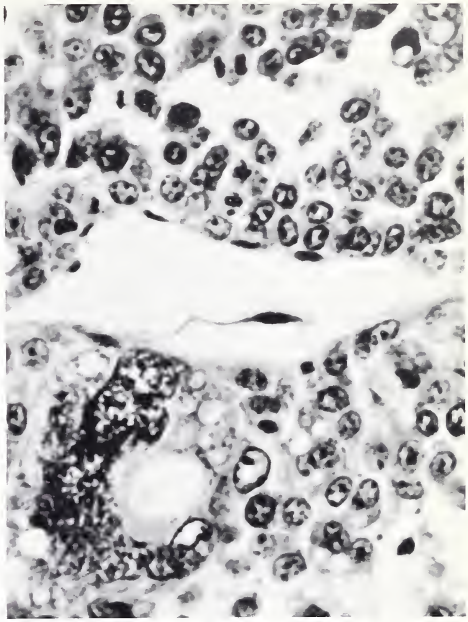

Fig. 30

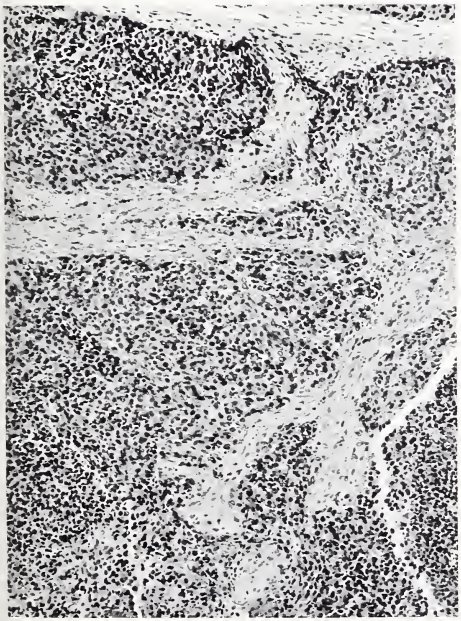

Fig. 31

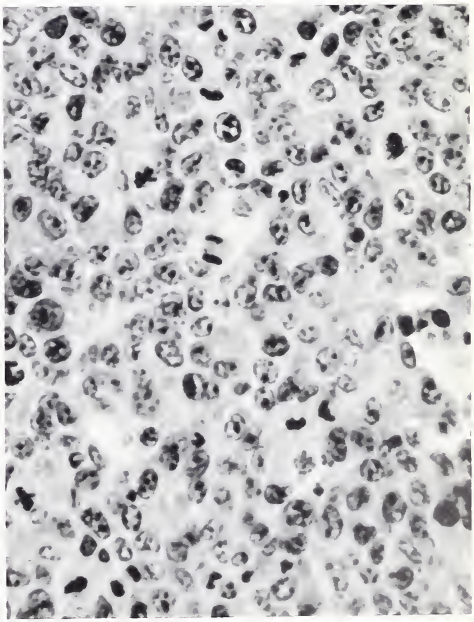

Fig. 32

LIPOSARCOMA D4888. GUINEA PIG

Figure 33. Photomicrograph of 90th generation transplant tumor. The nucleus of the tumor cell is round or oval, has a deeply stained nuclear membrane, one to several nucleoli, and heavy chromatin granules. Hematoxylin and eosin stain. X 950. N. C. I. 7499; A. F. I. P. Acc. No. 219934-33.

Figure 34. Photomicrograph of 90th generation transplant tumor. There is a large amount of stainable lipoidal material in the cytoplasm of the tumor cells. Frozen section stained with Sudan IV. X 440. N. C. I. 8687; A. F. I. P. Acc. No. 219934-34.

Figure 35. Photomicrograph of 90th generation transplant tumor. Fine reticular fibrils are present around single tumor cells and small groups of cells. Metalophil cells, deeply impregnated with silver, are present in close relationship to some of the reticular fibers. Wilder's silver preparation. X 440. N. C. I. 8690; A. F. I. P. Acc. No. 219934-35.

Figure 36. Section of a metastatic tumor in the lung of an animal bearing the 90th generation transplant tumor. Hematoxylin and eosin stain. X 60. N. C. I. 8209; A. F. I. P. Acc. No. 219934-36.

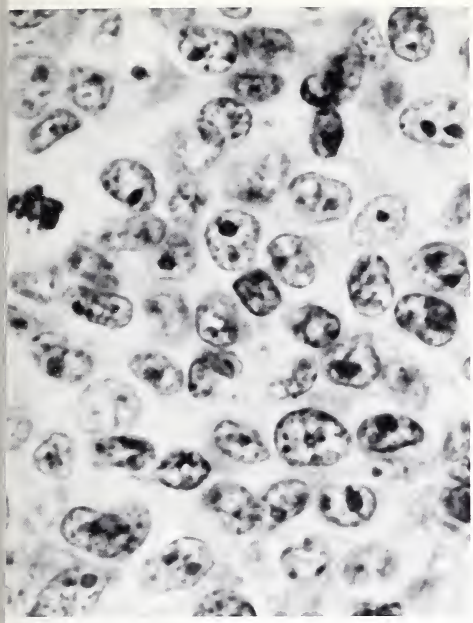

Fig. 33

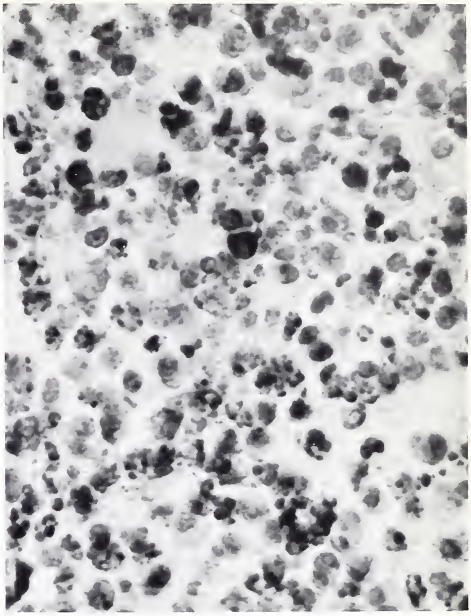

Fig. 34

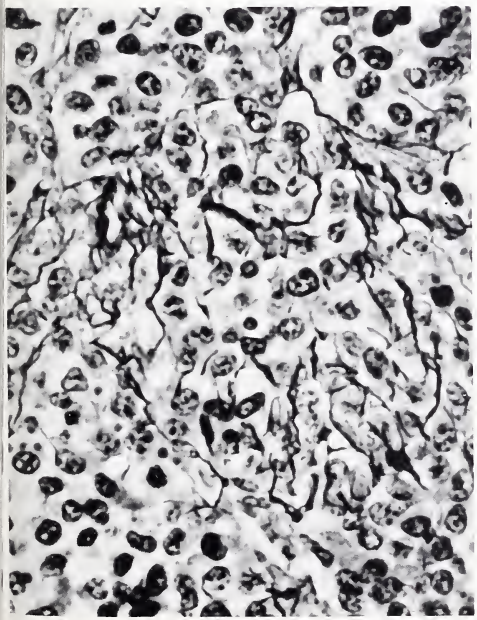

Fig. 35

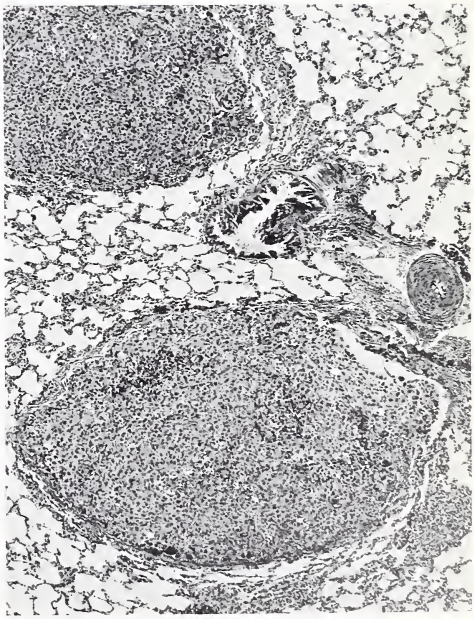

Fig. 36

Rous Sarcoma. Chicken

SYNONYMS: Chicken Tumor I; Rous Sarcoma No. 1; C. T. 1.

DEFINITION. A fibrosarcoma that arose spontaneously in a barred Plymouth Rock hen and that is transmissible by cell-free filtrates.

HISTORY AND DESCRIPTION OF ORIGINAL TUMOR. The tumor arose in the tissues of the right breast region of a pure-bred, adult, barred Plymouth Rock barnyard hen 15 months of age. The growth of the tumor was observed for a period of two months, and then in October 1910, the hen was brought to the laboratory of Peyton Rous at the Rockefeller Institute in New York City. Without further delay, the tumor was resected under ether anesthesia, and small pieces of it were inoculated intramuscularly and intraperitoneally into the same bird. The tumor was also inoculated in the same manner into two other hens from the same setting of eggs as the bird in which the tumor arose. The original tumor-bearing hen died 35 days later with extensive intraperitoneal tumor. At that time, one of the other two fowls that had been inoculated with tumor tissue exhibited a large tumor in the breast region.

The resected original tumor measured 4.8 x 4.1 x 4.1 cm. It was irregularly globular and was ulcerated. At surgical operation, the growth, which was enclosed in a vascular capsule, shelled out easily from the surrounding tissue. The cut surface revealed a central area of necrosis surrounded by a rim of translucent, friable, yellow-pink tissue.

Microscopically, loose bundles of spindle-shaped cells of varying size and shape coursed in different directions. The blood vessels were small and separated from tumor tissue only by endothelium. Fibrils were demonstrable by Mallory's phosphotungstic acid—hematoxylin stain. The spindle-shaped cells had large, bulging, vesicular nuclei that contained a loose network and coarse masses of chromatin. Numerous mitotic figures were found in the tumor. Giant cells with 5 or 6 nuclei were seen in the vicinity of areas of necrosis. Some areas consisted of myxomatous tissue.

TRANSPLANTATION STUDIES. At first, transplanted tumors grew progressively only in genetically related fowls. At the 7th transplant generation, however, it was found that the Rous Sarcoma could be successfully transplanted to nonrelated strains of barred Plymouth Rock chickens. At the 9th transplant generation, the tumor could be transplanted to other breeds. In later transplant generations, the tumor grew successfully in a higher percentage of birds than in early generations. The invasive capacity of the tumor had also become enhanced, the latent period had decreased, and the tumor-bearing chickens died earlier.

The Rous Sarcoma grows best in young chickens 2 to 10 weeks of age. It grows successfully in 90 to 100 percent of hosts, and it rarely regresses. In those cases in which regression does occur, the host becomes resistant to subsequent inoculation. The tumor should be transplanted every seven days.

Serial transplantation is conveniently maintained by the inoculation of small fragments of tumor tissue or saline suspensions of tumor cells into the subcutaneous tissue or into the muscle of the breast. The tumor can also be successfully transmitted by the use of cell-free extracts of fresh Rous Sarcoma tissue or of reconstituted lyophilized samples of partially purified Rous Sarcoma virus. The tumor grows well at the site of implantation, but the extent of growth varies somewhat with the size of the inoculum. Subcutaneous or intramuscular transplants usually produce palpable growths within 3 to 5 days, and the bird dies within 10 to 21 days after inoculation. Metastatic tumors begin to appear in 10 or 12 days. They are frequently observed in the lungs, heart, and liver, and occasionally in the kidneys, spleen, intestine, mesentery, pancreas, gizzard, gallbladder, and lymph nodes. No fundamental change in histologic pattern of the Rous Sarcoma has been observed during the years of transplantation. However, Rous stated that the tumor cells of the present transplant tumor are plumper and slightly less regular than those of the primary tumor. (Many of these data were obtained in personal interview with Dr. W. R. Bryan of the National Cancer Institute, Bethesda, Md.)

VIRUS ETIOLOGY. In 1910 Rous was able to transmit Chicken Tumor I by a cell-free filtrate. He filtered ground tumor tissue suspended in Ringer's solution under the supposition that the tumor cells would be held back in the filter paper, and that the filtrate would be innocuous (as had been the case with transplantable tumors of the rat, mouse, and dog). However, he found that the watery filtrate of the Rous Sarcoma produced tumors in fowls inoculated with small amounts of it. He was able also to produce tumors by inoculation of the fowl with the supernatant of a tumor emulsion. Finally, he produced tumors with filtrates passed through a fine Berkefeld filter that was impervious to Bacillus prodigiosus. This observation by Rous, coupled with that by Ellermann and Bang, who in 1908 had transmitted fowl leukosis with cell-free filtrates, introduced a new and important concept of the virus etiology of cancer. Shortly after Rous's discovery, Murphy demonstrated that the Rous Sarcoma could be transmitted by means of dried and powdered neoplastic tissue that had been kept at room temperature for many days. Most investigators at present consider the filtrable agent of the Rous Sarcoma to be a virus. The agent has been introduced into closely related species, such as pigeons and ducks, in which it produces tumors.

DESCRIPTION OF CURRENT TUMOR. Four-tenths of a cubic centimeter of a 1 to 2 dilution of Rous Sarcoma tissue in saline was injected into the wing muscles of a 45-day-old New Hampshire Red hen. Seven days later the tumor in the left wing muscle measures 5 x 3 x 2.5 cm. Grossly, this tumor consists of grayish tan, red and purple, soft or firm tissue that exudes a semitranslucent, greenish brown, mucoid material (pl. II–A, B).

Microscopically, the neoplastic cells of the Rous Sarcoma infiltrate the host tissues, and arteries, veins, and remnants of skeletal muscle are incor-

porated deep within the neoplasm. The cells are pleomorphic and the histologic pattern is variable. For descriptive purposes, three somewhat distinctive histologic patterns of the tumor are considered separately: (1) the interlacing spindle-cell pattern, (2) the myxomatous pattern, and (3) the pleomorphic pattern (fig. 37). In transplant tumors that possess all three of these, the line of demarcation between them may be sharp and distinct or the patterns may merge with one another.

(1) The spindle-cell pattern is composed of interlacing and interweaving bundles of closely packed, uniform, plump, spindle-shaped cells. Each of the cells lies within a network of thick fibers of reticulum and collagen. The bundles of tumor cells may be cut in different planes so that the cells may appear elongated, spindled, or round. Many fibroglial fibers can be demonstrated. The nucleus is surrounded by a rather heavy nuclear membrane and contains fine chromatin granules evenly distributed and 1 or 2 acidophilic or basophilic nucleoli. Mitotic figures average one per oil immersion field. There are a few inflammatory cells, but little hemorrhage or necrosis. Little or no periodic acid—Schiff-positive staining material is found anywhere in the section. The tumor tissue is interspersed with numerous slitlike branched sinusoidal vessels lined with a single layer of endothelial cells, or in some instances with neoplastic cells (fig. 38). This spindle cell area of the growth can be considered as a well differentiated fibrosarcoma.

(2) The myxomatous pattern of the neoplasm is composed predominately of spindle-shaped cells. However, the individual cells and bundles are widely separated by myxomatous material, which takes the basophilic stains but which remains uncolored in the periodic acid—Schiff preparation (fig. 39). In the myxomatous area, there are in addition numerous phagocytic and other inflammatory cells and extravasated red blood cells. The tumor cells are more pleomorphic than those in the first area described. There is considerable variation in number, size, shape, and staining capacity of the nuclei. When stained with hematoxylin and eosin, a nucleus may contain a dull basophilic nucleolus, which may have a reddish cast when the focus of the microscope is moved up and down. This reddish cast to the nucleolus is particularly apparent in a pale possibly degenerated nucleus that has little chromatin. Single greatly elongated cells often extend across the greater part of an oil immersion field. Mitotic figures are fairly frequent and often appear degenerated. The neoplastic cells show pronounced regressive changes. Cytoplasmic vacuoles containing periodic acid—Schiff-positive material are sometimes observed. Fibroglia are frequently identified but are pale (figs. 40, 41). The collagenic and reticular fibers are widely separated, split, and frayed due to the presence of myxomatous material (fig. 42). The fibrils are best preserved in areas having the smallest amount of myxomatous material.

(3) The pleomorphic pattern is characterized by cellular variations, myxomatous change, degeneration and necrosis. There is pronounced variation

in size, shape, and staining quality of the neoplastic cells, and more particularly of their nuclei. Some of the nuclei are lobated or multiple. The cytoplasm is vacuolated and frequently heavily loaded with granular periodic acid—Schiff-positive material. Of the three histologic variants described, mitotic figures are least numerous in the cells of the third or pleomorphic pattern. There may be thrombosis of blood vessels, hemorrhage, and an inflammatory infiltrate composed chiefly of eosinophils and of macrophages containing blood pigment.

There has been a great deal of speculation regarding the interrelation of the various cell types composing the Rous Sarcoma. It has been postulated that there is a parent cell from which the other cells of the neoplasm are derived. The other possibility is that the Rous Sarcoma is indeed a mixed tumor composed of closely related cell types. On morphologic grounds alone, a strong case can be made for the view that transition stages exist between cells of different types, but proof of this is lacking. There is now available a technic designed by Sanford and associates for the isolation and propagation of single tumor cells in tissue culture. The application of this technic to the Rous tumor might be expected to throw light on this question which has so far not been explained by conventional experimental technics.

References

Bryan, W. R. Quantitative studies on the latent period of tumors induced with subcutaneous injections of the agent of chicken tumor I. II. Estimation of the latent period. J. Nat. Cancer Inst., 6:373–377, 1946.

Duran-Reynals, F. Virus-induced tumors and the virus theory of cancer. In: Homburger, F., and Fishman, W. H. (eds.). The Physiopathology of Cancer, pp. 298–337. New York: Paul B. Hoeber, Inc., 1953.

Ellermann, V., and Bang, O. Experimentelle Leukämie bei Hühnern. Centralbl. f. Bakt., 1. Abt., 46:595–609, 1908.

Epstein, M. A. The identification of the Rous virus; a morphological and biological study. Brit. J. Cancer, 10:33–48, 1956.

Gaylord, W. H., Jr. Virus-like particles associated with the Rous sarcoma as seen in sections of the tumor. Cancer Research, 15:80–83, 1955.

Levine, M. The cytology of the tumor cell in the Rous chicken sarcoma. Am. J. Cancer, 36:386–430, 581–602; 37:69–107, 1939.

Likely, G. D., Sanford, K. K., and Earle, W. R. Further studies on the proliferation in vitro of single isolated tissue cells. J. Nat. Cancer Inst., 13:177–184, 1952.

Loomis, L. N., and Pratt, A. W. The histogenesis of Rous Sarcoma I induced by partially purified virus. J. Nat. Cancer Inst., 17:101–121, 1956.

Rous, P. A transmissible avian neoplasm. (Sarcoma of the common fowl). J. Exper. Med., 12:696–705, 1910.

———. A sarcoma of the fowl transmissible by an agent separable from the tumor cells. J. Exper. Med., 13:397–411, 1911.

———. The virus tumors and the tumor problem. Am. J. Cancer, 28:233–272, 1936.

Sanford, K. K., Earle, W. R., and Likely, G. D. The growth in vitro of single isolated tissue cells. J. Nat. Cancer Inst., 9:220–246, 1948.

ROUS SARCOMA. CHICKEN

(Tumor-bearing animal courtesy of Dr. W. R. Bryan, National Cancer Institute, Bethesda, Md.; histologic sections courtesy of Dr. A. W. Hilberg, National Cancer Institute, Bethesda, Md.)

Figure 37. Low power photomicrograph of transplant tumor. The lower right portion of the field is cellular. Other areas show myxomatous change and necrosis. Hematoxylin and eosin stain. X 24. N. C. I. 8461; A. F. I. P. Acc. No. 219934–37.

Figure 38. Photomicrograph of transplant tumor showing the appearance of the blood vessels. Hematoxylin and eosin stain. X 285. N. C. I. 8462; A. F. I. P. Acc. No. 219934–38.

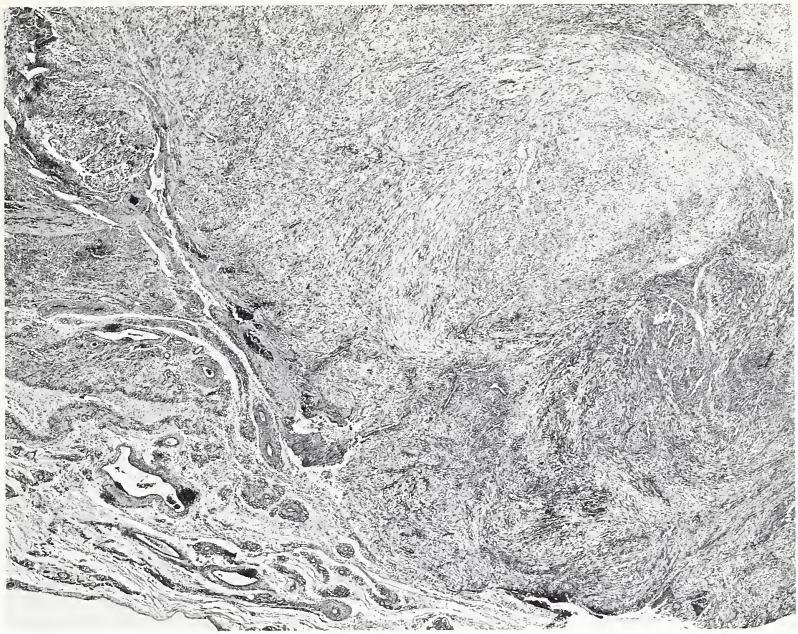

Fig. 37

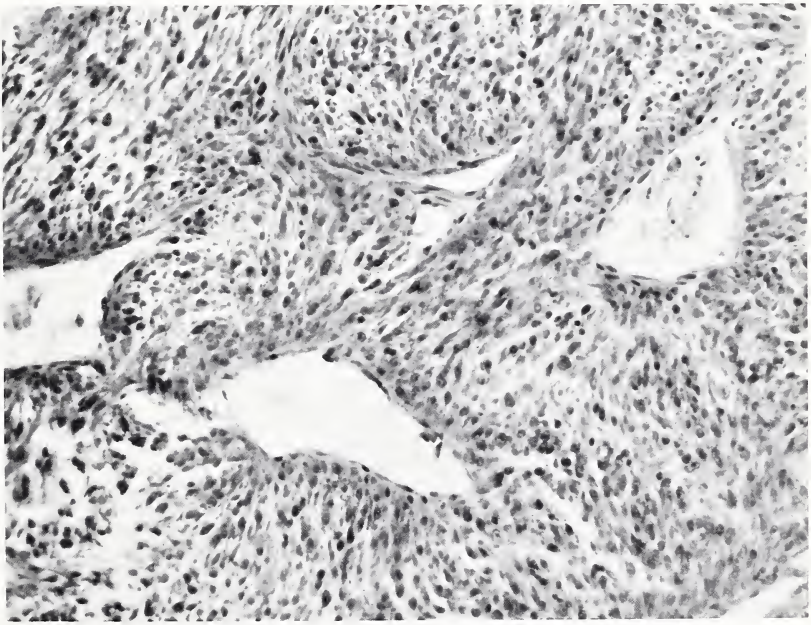

Fig. 38

ROUS SARCOMA. CHICKEN

Figure 39. Photomicrograph of transplant tumor. This portion of the tumor shows spindle-shaped cells, inflammatory cells, and myxomatous change. Hematoxylin and eosin stain. X 285. N. C. I. 8464; A. F. I. P. Acc. No. 219934–39.

Figure 40. Photomicrograph of transplant tumor. This area is composed of spindle-shaped cells. Note fibrils interpreted as fibroglia. Phosphotungstic acid—hematoxylin stain. X 570. N. C. I. 12632; A. F. I. P. Acc. No. 219934–40.

Figure 41. Photomicrograph of transplant tumor. This area shows the relative proportion of nucleus and cytoplasm of the cells. Fibrils interpreted as fibroglia are in close relationship with the tumor cells. Phosphotungstic acid—hematoxylin stain. X 1790. N. C. I. 8491; A. F. I. P. Acc. No. 219934–41.

Figure 42. Photomicrograph of transplant tumor. The reticular fibers are split and frayed in an area showing myxomatous change and degeneration. Wilder's silver preparation. X 325. N. C. I. 8472; A. F. I. P. Acc. No. 219934–42.

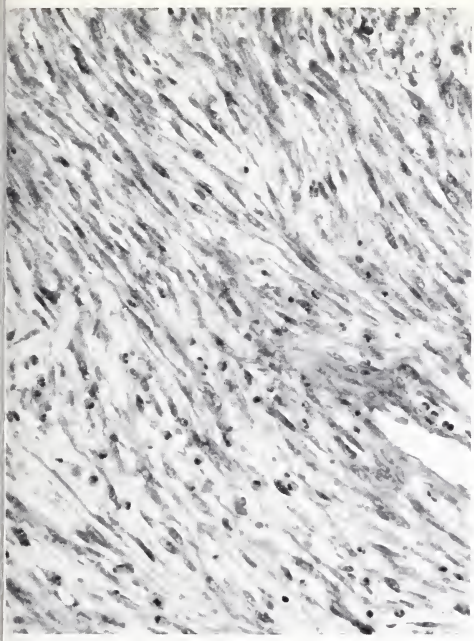

Fig. 39

Fig. 40

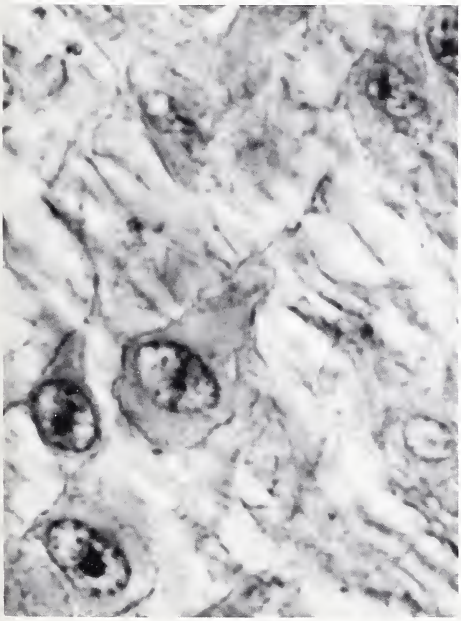

Fig. 41

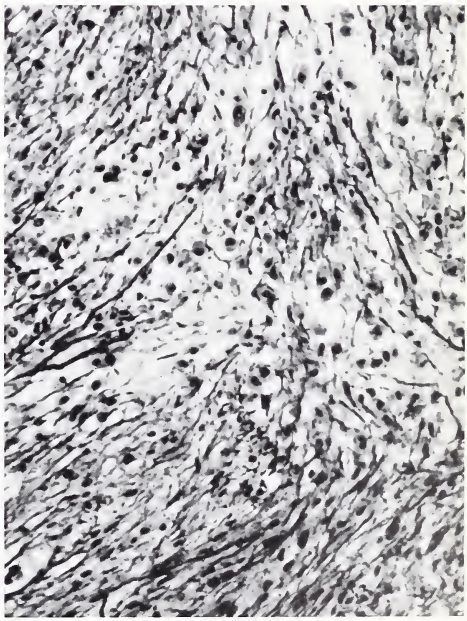

Fig. 42

PLATE II

ROUS SARCOMA. CHICKEN

(Tumor-bearing animals courtesy of Dr. W. R. Bryan, National Cancer Institute, Bethesda, Md.)

A. Gross photograph of transplant tumor in a New Hampshire Red chicken. Eight days previously a partially purified ("microsome") fraction derived from Rous Sarcoma tumor tissue by ultracentrifugation was injected into the muscles of the right wing. The dose corresponds to the amount of virus extracted from 0.002 grams of tumor tissue. N. C. I. 448; A. F. I. P. Acc. No. 219934-294.

B. Gross photograph of transplant tumor. This shows a horizontal section through a tumor in the wing of a New Hampshire Red chicken 15 days after inoculation with a reconstituted lyophilized sample of purified Rous Sarcoma virus. The dose injected into the muscles of the wing corresponds to the amount of virus extracted from 0.02 grams of tumor tissue. N. C. I. 986; A. F. I. P. Acc. No. 219934-295.

A

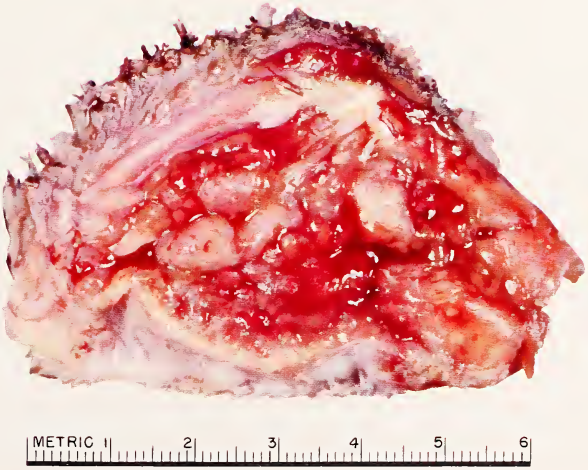

B

PLATE II

TUMORS OF MUSCLE

Rhabdomyosarcoma H6668. Mouse

DEFINITION. A rhabdomyosarcoma that arose spontaneously in a BALB/c mouse.

HISTORY AND DESCRIPTION OF ORIGINAL TUMOR. Rhabdomyosarcoma H6668 arose in the anterior intercostal muscles of an untreated BALB/c strain mouse necropsied on April 5, 1951, in the laboratory of Katharine Hummel at the Roscoe B. Jackson Memorial Laboratory, Bar Harbor, Maine. The tumor consisted of a small, firm, white nodule that was located in the chest wall and was adherent to the overlying skin. It was described as consisting of atypical muscle fibers arranged for the most part in interlaced and entangled strands and occasionally in parallel bundles, supported by a highly vascular stroma of connective tissue. Most of the atypical muscle fibers contained one centrally located nucleus, while others contained several nuclei. Longitudinal intracytoplasmic fibrils were visible, and well stained preparations revealed cross striation.

TRANSPLANTATION STUDIES. The tumor has always been transplanted in BALB/c strain mice. Subcutaneous transplants of the tumor grow progressively in 100 percent of animals inoculated, and the tumor does not regress. It becomes palpable in seven days, and kills the host in about 50 days. In more than 30 transplant generations the tumor cells have maintained their capacity to produce cross-striated and longitudinal myofibrils.

DESCRIPTION OF CURRENT TUMOR. A 1-month-old subcutaneous transplant of the 24th generation of Rhabdomyosarcoma H6668 measures 12 x 7 x 5 mm. and is grayish tan. It is sharply circumscribed, completely encapsulated, and has no large areas of necrosis and virtually no hemorrhage (fig. 43). There are two types of neoplastic cell: the large cell and the small cell. Different portions of the tumor show a predominance of one or the other type of cell, or the two may be evenly intermingled. These two types of cell may be variants of a single stem cell, for transitional stages between the two can often be found (figs. 44, 45).

The large cell is round, sometimes oval, racquet shaped or strap shaped (fig. 46). It measures 100 microns or more in length and varies from 15.1 to 57.9 microns in diameter, the average diameter of 26 cells being 27 microns. The area of the nucleus is relatively much smaller than that of the cytoplasm. Many of the cells contain a single nucleus which is centrally or peripherally placed. However, as many as six nuclei may be counted in a single round

cell, and the straplike cells may contain a dozen or more nuclei, usually clustered in the center. The nucleus of the large cell is generally round, with a sharply outlined nuclear membrane. It possesses one centrally placed, irregularly shaped, basophilic nucleolus or several small nucleoli. The strands of the linin network in the center of the nucleus are coarse, while in the periphery, where most of the chromatin granules are concentrated, the strands are of fine structure. In a few instances, the nucleus contains one or more vacuoles, and sometimes the entire nucleus appears vacuolated. No mitotic figures are observed. The nucleus of degenerative cells may contain one or several round acidophilic objects. The large cell has a great deal of cytoplasm and a distinct cell membrane. The cytoplasm usually contains rods, threads, and granules which are colored deep blue with the phosphotungstic acid—hematoxylin stain and are considered to be mitochondria. Sections prepared by the Regaud and the aniline fuchsin methods for the demonstration of mitochondria reveal that the large cells have both filamentous and granular mitochondria, but chiefly the latter (fig. 47). These mitochondria may be haphazardly arranged or may form themselves into one or more whorls. Occasionally, a single cell may contain 2 to 4 such whorls of mitochondria, sometimes oriented around the nucleus. A number of the cells have thick, heavily stained myofibrils which, in a few cells, are arranged in cross striation (figs. 48, 49). In sections prepared by the Regaud and the aniline fuchsin methods, the staining capacity of myofibrils in cross striation in the straplike cells is similar to that of the mitochondria of developing muscle cells of embryos. The large cell contains many small and large cytoplasmic vacuoles that are most numerous near the cell membrane. Such vacuolated cells may resemble spider cells (fig. 50). The periodic acid—Schiff reaction reveals a large amount of purplish red cytoplasmic material that is removable by diastase, and is therefore presumably glycogen. However, glycogen does not account for all of the vacuoles noted in the hematoxylin—eosin preparations.

The small cell is pleomorphic and varies in size from that of a small lymphocyte to that of the large neoplastic cell. Fibroglial fibers are numerous in areas of the tumor composed predominantly of small cells. Many of the small cells are elongated, spindle shaped or stellate; others are oval or kidney shaped, while still others are round. The small cells have both filamentous and globular mitochondria as demonstrated by the Regaud and aniline fuchsin methods. The nuclei, which are often the same shape as the cell, are more hyperchromatic, smaller, and more uniform than those of the large cell. Nearly all of them have from 1 to 6 nucleoli. Two to four mitotic figures may be found in every high power field, and many of them are abnormal in form.

The blood vessels of the tumor are moderately numerous and are supported by a small amount of stroma containing reticular and collagenic fibers. They are dilated and thin walled, having the structure of capillaries. The endothelial lining is prominent and appears everywhere intact. Small cells

are most numerous around blood vessels, and in these locations reticular and collagenic fibers are most abundant. The processes of the small cells appear at times to be continuous with the reticular and collagenic fibers. In areas in which the small cells predominate, they may partially or completely encircle a large cell. Every large cell is surrounded by a sheath of reticular or collagenic fibers or both. In areas of the tumor in which the large cell predominates, the small cell may be found within the reticular network at points where the fibers converge.

Transition forms between the small cell and the large cell are believed to exist. This, coupled with the fact that no mitotic figures are observed in the large cell whereas many are found in the small cell, lends weight to our belief that the large cell represents a maturation product of the small cell.

(Data on the original tumor and its transplantation characteristics were kindly given to us by Dr. Elizabeth Fekete of the Jackson Memorial Laboratory, Bar Harbor, Me., and Dr. W. H. Eyestone of the National Cancer Institute, Bethesda, Md.) There is no publication extant on Rhabdomyosarcoma H6668.

RHABDOMYOSARCOMA H6668. MOUSE

(Tumor-bearing animal courtesy of Dr. W. H. Eyestone, National Cancer Institute, Bethesda, Md.)

Figure 43. Photomicrograph of 24th generation transplant tumor. This low power view shows two contrasting areas. The dark area is composed of small cells and the lighter area of large cells. Hematoxylin and eosin stain. X 32. N. C. I. 8496; A. F. I. P. Acc. No. 219934-43.

Figure 44. Photomicrograph of 24th generation transplant tumor. This area shows both small and large cells with a predominance of the large type of cell. Hematoxylin and eosin stain. X 275. N. C. I. 8475; A. F. I. P. Acc. No. 219934-44.

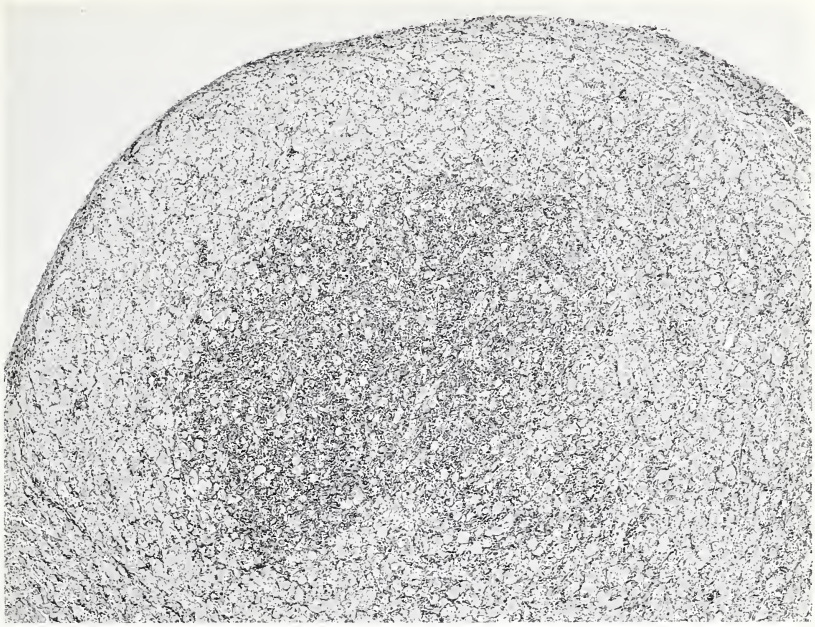

Fig. 43

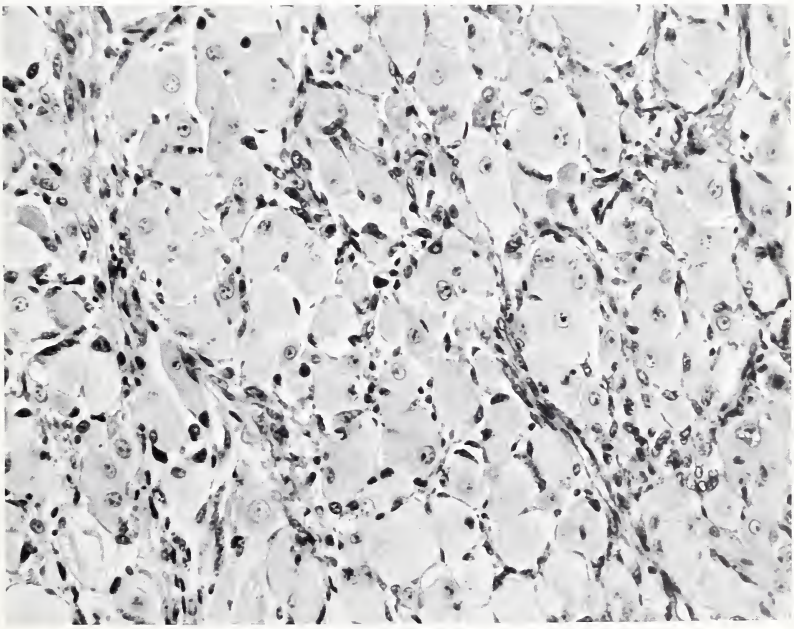

Fig. 44

RHABDOMYOSARCOMA H6668. MOUSE

Figure 45. Photomicrograph of 24th generation transplant tumor. This shows a numerical predominance of the small type of cell. Suggestive transition forms between the large and small types of cell are present. Hematoxylin and eosin stain. X 310. N. C. I. 8474; A. F. I. P. Acc. No. 219934–45.

Figure 46. Photomicrograph of 24th generation transplant tumor. This shows a single cell of the large type with two nuclei. Note the fibrillar and granular character of the cytoplasm. Phosphotungstic acid—hematoxylin stain. X 950. N. C. I. 8476; A. F. I. P. Acc. No. 219934–46.

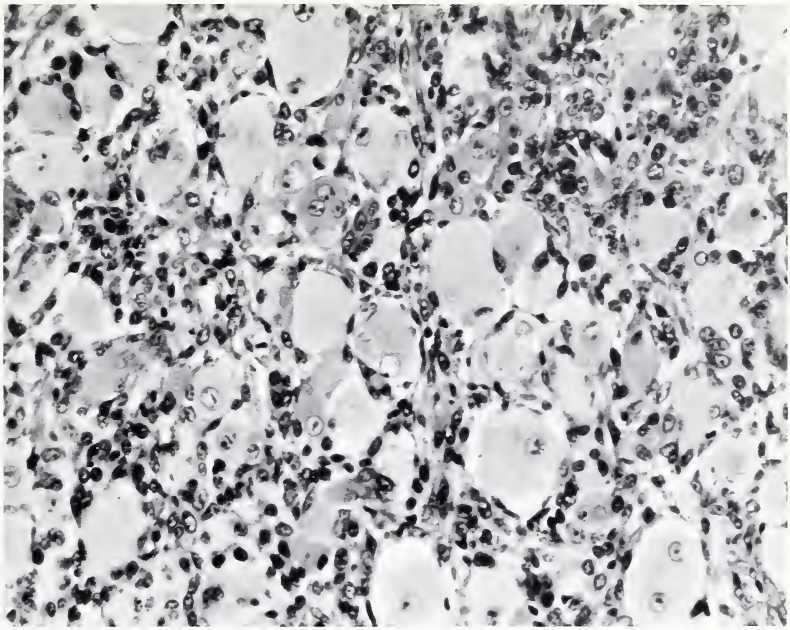

Fig. 45

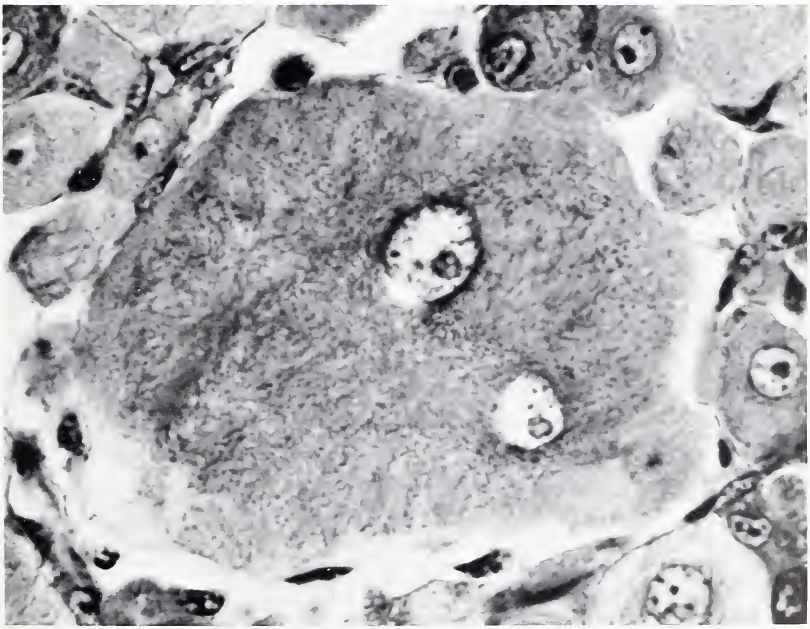

Fig. 46

RHABDOMYOSARCOMA H6668. MOUSE

Figure 47. Photomicrograph of 24th generation transplant tumor. The large cell shows both granular and filamentous mitochondria. Aniline fuchsin stain. X 1050. N. C. I. 8487; A. F. I. P. Acc. No. 219934–47.

Figure 48. Photomicrograph of 24th generation transplant tumor. Two straplike cells show myofibrils in cross striation. Phosphotungstic acid—hematoxylin stain. X 1260. N. C. I. 8489; A. F. I. P. Acc. No. 219934–48.

Figure 49. Photomicrograph of 24th generation transplant tumor. This shows a more rounded type of cell with myofibrils in cross striation. Phosphotungstic acid—hematoxylin stain. X 1050. N. C. I. 8481; A. F. I. P. Acc. No. 219934–49.

Figure 50. Photomicrograph of 24th generation transplant tumor showing a spider-like cell. Phosphotungstic acid—hematoxylin stain. X 900. N. C. I. 8479; A. F. I. P. Acc. No. 219934–50.

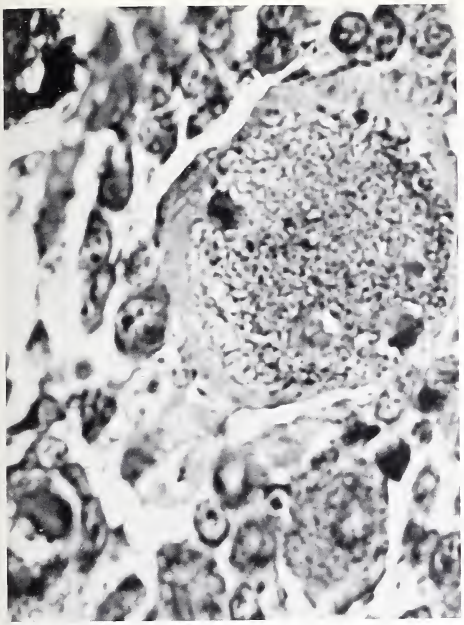

Fig. 47

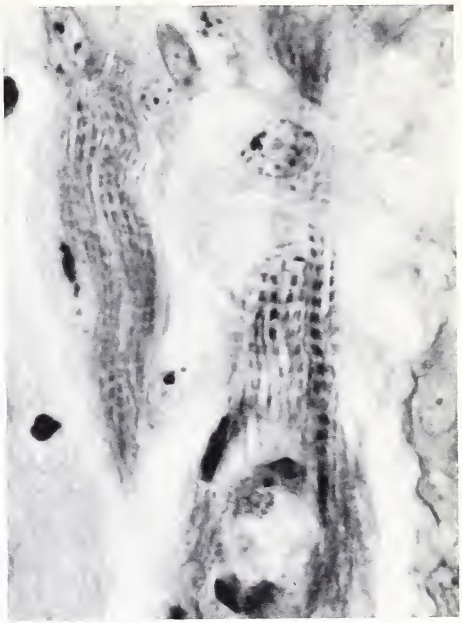

Fig. 48

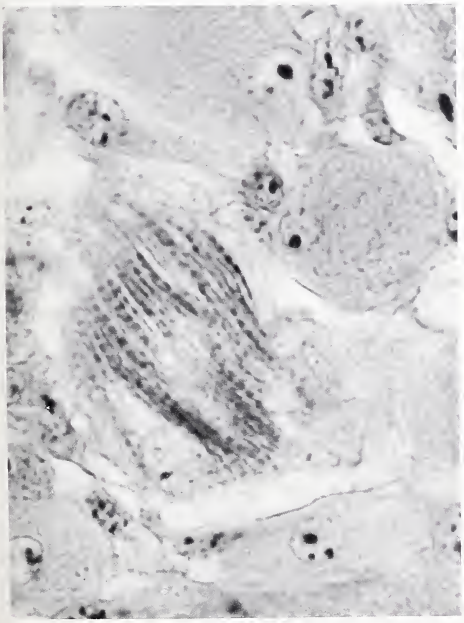

Fig. 49

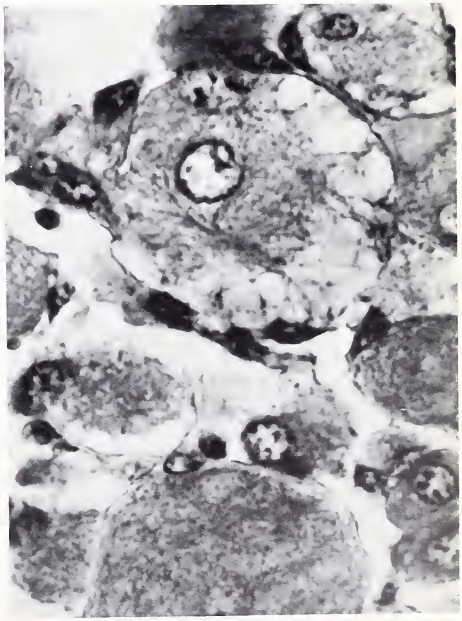

Fig. 50

TUMORS OF BONE

Osteogenic Sarcoma EM2. Mouse

DEFINITION. An osteogenic sarcoma of a $C3H_f/He$ mouse that had received total body radiation with the spleen protected.

HISTORY AND DESCRIPTION OF ORIGINAL TUMOR. Osteogenic Sarcoma EM2 was first observed on the ventral thorax of a mouse on December 21, 1951. The animal was one of a group of $C3H_f/He$ mice which on May 8, 1950, had received 400 r total body roentgen irradiation in the laboratory of the late Egon Lorenz at the National Cancer Institute, Bethesda, Maryland. The spleen had been protected during the roentgen ray treatment.

At necropsy, the tumor was found to involve the sternum and the adjacent musculature. It was very firm, grayish white, and measured 2.5 cm. in greatest diameter. The ovary contained a tubular adenoma. Microscopically, Osteogenic Sarcoma EM2 was composed of spindle-shaped cells arranged in interlacing bundles, with the central portion showing areas of cancellous bone containing osteoblasts within lacunae (fig. 51). Multinucleated giant cells were frequently associated with the areas of osseous tissue. A few small foci of necrosis and hemorrhage were present.

TRANSPLANTATION STUDIES. The original tumor was transplanted subcutaneously in five $C3H_f/He$ mice and grew in all. The transplanted tumors had an average diameter of 4 cm. in 50 days. All these tumors contained large amounts of bone. Transplant sublines were selected from each of two different animals, one subline from tumor tissue containing bone, and one subline from tumor tissue largely devoid of bone. The transplant subline from the former has now passed through 26 generations, and bone has formed in the majority of the transplanted tumors. In general, intramuscular, intraperitoneal, and intrathoracic transplants have produced osseous tissue, whereas subcutaneous and intracranial transplants have not. The other transplant subline, selected from tumor tissue largely devoid of bone, has produced bone in 7 of 22 generations. Both tumor transplant sublines generally killed the host in from 25 to 50 days. Terminally, a significant number of these tumors metastasized to lung (fig. 52). Whether or not bone was formed in a given transplant, the alkaline phosphatase reaction in the tumor tissue was usually positive. Osteogenic Sarcoma EM2 was in its 40th transplant generation May 16, 1955. (These data on the original tumor and its transplantation characteristics were kindly contributed by Dr. W. H. Eyestone of the National Cancer Institute, Bethesda, Md.)

DESCRIPTION OF CURRENT TUMOR. A 28-day-old intramuscular transplant from the bone-producing subline of Osteogenic Sarcoma EM2 measures 2.5 cm. in diameter. It is partially surrounded by a fibrous capsule but in some areas invades the adjacent host tissue. The tumor tissue is firm, gray to yellow, and contains dense, white, gritty areas.

On microscopic examination, the capsule is found to be composed of fascia and adipose tissue showing an inflammatory reaction. Where the transplant is unencapsulated, it infiltrates muscle and fibrofatty tissue, remnants of which lie deep within the tumor (fig. 53). The histologic pattern is that of a sarcoma with numerous large areas of membranous-like bone. The cellular portion of the tumor consists of interlacing bands of spindle-shaped cells. This tissue is moderately vascular and has slitlike blood vessels of varying size and shape lined with a thin layer of endothelial cells. There are only a few small areas of necrosis and hemorrhage. The spindle-shaped cells may be cut longitudinally, tangentially, and in cross section (fig. 54). They vary moderately in size, shape, and staining capacity, and generally possess one nucleus. The nuclear membrane is distinct and has fine chromatin granules along its inner aspect, leaving the center of the nucleus relatively clear. There are usually one or several small deeply-colored nucleoli. The cytoplasm varies in amount and exhibits many characteristic fibroglial fibrils. As many as five mitotic figures may be seen in a single oil immersion field. Reticular fibrils surround each cell. Although collagenic fibers are also present, they are much less numerous (fig. 55).

Approximately one third of the tumor transplant is occupied by membranous-like bone, which may consist of a large central bony focus or several small central or peripheral foci (fig. 56). The cellular portion of the tumor is best preserved around blood vessels. The transition from the cellular portion of the tumor to bone is often abrupt. In other instances, there is a gradual transition so that there is interdigitation of bundles of tumor cells with sheets of bone. The bone consists of a thick hyaline network surrounding spaces containing shrunken cells isolated from one another. These isolated cells resemble osteocytes in some instances, while in other instances they are similar to the spindle-shaped cells of the remainder of the tumor. It is believed that the spindle-shaped cells give rise to the osteocytes. In the more central areas of the membranous-like bone, the nuclei of the osteocytes are small and deeply colored and are surrounded by a small amount of cytoplasm. In this location, these cells are more likely to be round or stellate than spindle shaped. Some of them are pale and appear to be necrotic.

The hyaline network of the membranous-like bone is colored red with van Gieson's stain (fig. 57); gray, brown, or black in silver impregnation; a mixture of deep blue and deep red with Mallory's aniline blue method; green with the trichrome stain; brown with the phosphotungstic acid—hematoxylin stain; black with the iron hematoxylin stain; purplish red with the periodic

OSTEOGENIC SARCOMA EM2. MOUSE

(Tumor-bearing animal courtesy of Dr. W. H. Eyestone, National Cancer Institute, Bethesda, Md.)

Figure 51. Low power photomicrograph of original tumor. A portion of the tip of the sternum is present at the upper left. Approximately 50 percent of the tumor in this area is composed of bone. Hematoxylin and eosin stain. X 32. N. C. I. 8437; A. F. I. P. Acc. No. 219934–51.

Figure 52. Section of lung from a mouse bearing an intramuscular transplant tumor. Note metastatic tumor. Hematoxylin and eosin stain. X 100. N. C. I. 8441; A. F. I. P. Acc. No. 219934–52.

Figure 53. Photomicrograph of intramuscular transplant tumor. A cross section of the femur is visible in the upper left corner of the illustration, and surrounding it are skeletal muscles. Much of the tumor is cellular. The pale area at the lower right is bone. Hematoxylin and eosin stain. X 15. N. C. I. 8435; A. F. I. P. Acc. No. 219934–53.

Fig. 51

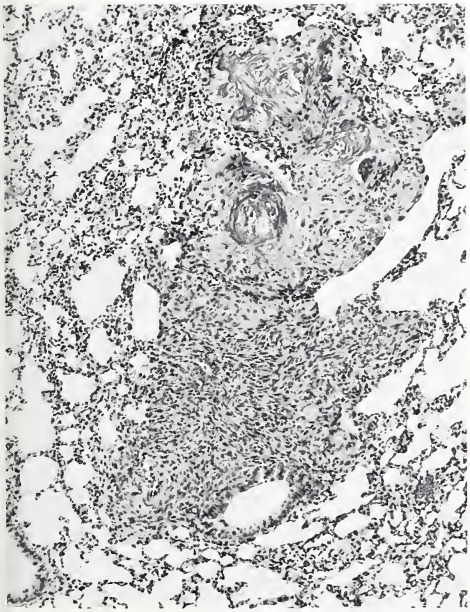

Fig. 52

Fig. 53

OSTEOGENIC SARCOMA EM2. MOUSE

Figure 54. Photomicrograph of intramuscular transplant tumor showing interlacing bundles of spindle-shaped cells. Hematoxylin and eosin stain. X 400. N. C. I. 8450; A. F. I. P. Acc. No. 219934–54.

Figure 55. Photomicrograph of intramuscular transplant tumor. This shows the distribution of reticular fibers around virtually every cell in the field. Wilder's silver preparation. X 400. N. C. I. 8451; A. F. I. P. Acc. No. 219934–55.

Figure 56. Photomicrograph of intramuscular transplant tumor. This area contains membranous-like bone. Hematoxylin and eosin stain. X 400. N. C. I. 8449; A. F. I. P. Acc. No. 219934–56.

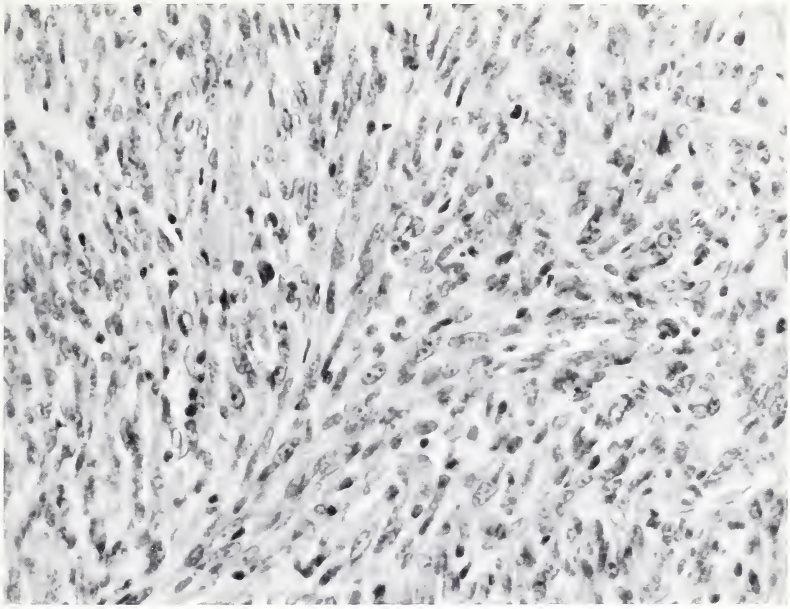

Fig. 54

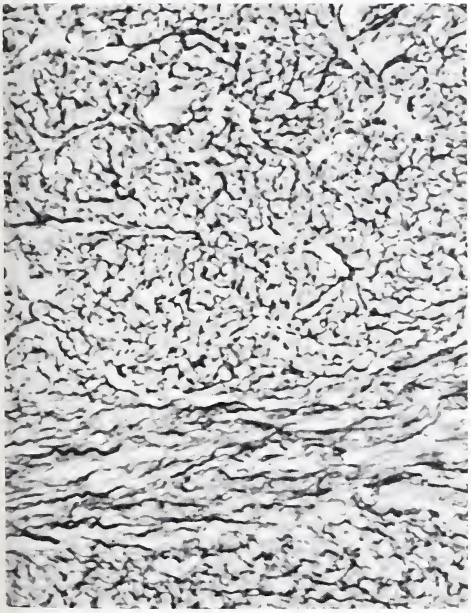

Fig. 55

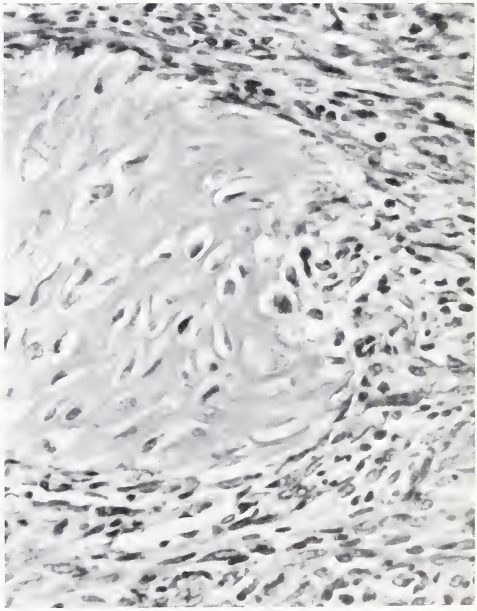

Fig. 56

OSTEOGENIC SARCOMA EM2. MOUSE

Figure 57. Photomicrograph of intramuscular transplant tumor. The lower half shows cellular tumor and the upper half shows membranous-like bone. Note the pattern of the collagenic fibers. Van Gieson stain. X 100. N. C. I. 8445; A. F. I. P. Acc. No. 219934-57.

Figure 58. Photomicrograph of intramuscular transplant tumor showing an area containing osteoclasts. Hematoxylin and eosin stain. X 400. N. C. I. 8446; A. F. I. P. Acc. No. 219934-58.

Figure 59. Low power photomicrograph of intramuscular transplant tumor showing the distribution of alkaline phosphatase. Alkaline phosphatase preparation. X 15. N. C. I. 8433; A. F. I. P. Acc. No. 219934-59.

Figure 60. Low power photomicrograph of intramuscular transplant tumor showing most of the acid phosphatase concentrated in the older bone. Acid phosphatase preparation. X 15. N. C. I. 8432; A. F. I. P. Acc. No. 219934-60.

Fig. 57

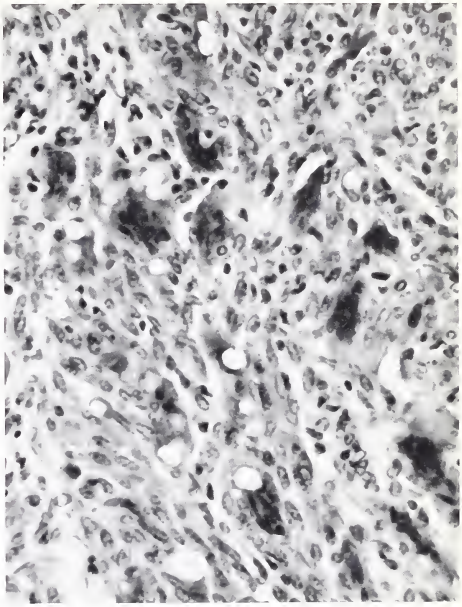

Fig. 58

Fig. 59

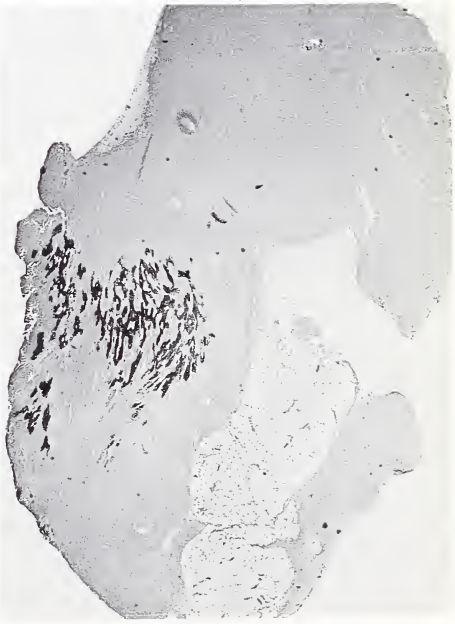

Fig. 60

acid—Schiff reaction; and red with hematoxylin and eosin. The black argentaffin fibers of the hyaline network alternate with pale unstained material. The collagenic fibers are continuous with corresponding fibers of the cellular portion of the tumor.

A hyaline material is usually observed among the spindle-shaped cells near the margin of the bone. The cells thus surrounded by hyalinized material appear later to lose their processes and become round cells that occupy clear spaces or lacunae in the newly formed bone. Occasionally tumor cells assume a round shape and become marginated along the borders of the newly formed bone, thus simulating osteoblasts. Cells of similar appearance may be distributed around thin-walled blood vessels within the areas of bone.

Osteoclastic activity in relation to the newly formed bone is not apparent. In the non-osseous portion of the tumor, however, there are sometimes relatively large fields containing numerous irregularly shaped giant cells having the appearance of osteoclasts (fig. 58). Some of these cells have a dozen or more centrally placed nuclei surrounded by a deeply stained vacuolated cytoplasm. There are fine cytoplasmic projections extending into the surrounding area, and portions of the periphery of the cells are often serrated.

The membranous-like bone stains deeply for alkaline phosphatase and is thus sharply delineated from the cellular areas of the tumor which stain less deeply (fig. 59). There is less alkaline phosphatase in the central portion of the area of bone where the structure is more mature than at the periphery of the osseous foci where the hyaline network encloses tumor cells. Acid phosphatase is precipitated in the central area in what appears to be the oldest portion of the bone, whereas in younger peripheral areas of bone there is little acid phosphatase (fig. 60).

References

Barrett, M. K., Dalton, A. J., Edwards, J. E., and Greenstein, J. P. A transplantable osteogenic sarcoma originating in a C3H mouse. J. Nat. Cancer Inst., 4:389–402, 1944.

Hilberg, A. W. Morphologic variations in an osteogenic sarcoma of the mouse when transplanted to the kidney. J. Nat. Cancer Inst., 16:951–959, 1956.

TUMORS OF HEMATOPOIETIC TISSUES

GRANULOCYTIC LEUKEMIA

Chloroleukemia 123, Shay. Rat

DEFINITION. A granulocytic leukemia characterized by leukemic blood and local tumors of a green color in various sites induced in a Wistar rat by the gastric instillation of 20-methylcholanthrene.

HISTORY AND DESCRIPTION OF ORIGINAL TUMOR. Shay and his associates (1951) induced granulocytic leukemia in two Wistar rats, aged 14 and 16 months, by the gastric instillation of 20-methylcholanthrene. The experiment was performed at the Fels Research Institute, Temple University Medical School, Philadelphia, Pennsylvania. Attempts to transplant these leukemias to rats 30 to 40 days of age were unsuccessful. However, neoplastic tissue from a third rat, aged 16 months, in which granulocytic leukemia had been induced in the same manner, was successfully transplanted to rats less than seven days of age. This transplantable line of leukemia was established in June 1950 and was designated Chloroleukemia 123.

The features of local tumor formation and of the leukemic blood picture were said to be similar in all three of these rats in which leukemia was induced. However, Shay and associates (1951) described the pathologic changes in the first two rats in greater detail than in the third rat, from which Chloroleukemia 123 was derived. The animals were anemic and had an increased number of circulating white blood cells with many immature granulocytic forms. The spleen, liver, and intra-abdominal lymph nodes were enlarged. Although none of the three original animals with induced myelogenous leukemia showed green discoloration of the localized tumors, all of the transplanted tumors derived from the original tumor-bearing animal developed as chloroleukemia. An incidental finding in the third animal was carcinoma of the seminal vesicle.

On microscopic examination, the liver was found to be infiltrated by leukemic cells of various shapes that possessed round, indented, or lobated nuclei. These leukemic cells were rich in peroxidase. They were most numerous in the portal triad areas and in the sinusoids. The spleen was distorted due to replacement of its follicles and pulp by leukemic cells similar to those in the liver. A number of giant cells considered to be megakaryocytes were scattered throughout the spleen. In the lungs, there was an infiltration of leukemic cells around the bronchi and blood vessels and in the walls of the alveolar septa. The renal tubular epithelium was degenerated. At one pole of one of

the kidneys, masses of leukemic cells were found in the cortical vessels near the capsule. Leukemic cells were found in the lymph nodes from the right groin and from the region of the cecum, pancreas, mesentery, and salivary glands. They were also present in the parenchyma of the pancreas and in the areolar tissue surrounding the thyroid gland.

TRANSPLANTATION STUDIES. Chloroleukemia 123 was transplanted in the first few generations by the intraperitoneal injection of whole blood or of a brei of spleen or liver into rats less than seven days of age. Subsequently, the best results were obtained when 0.2 cc. of whole blood from animals having leukocyte counts ranging between 20,000 per cu. mm. and 300,000 per cu. mm. was used for inoculation. However, transplantation was successful, and the host developed leukemia when the injected blood from the donor rat contained as few as 1 percent leukemic granulocytes. Wistar, Long Evans, and Sherman strain random-bred rats have been used as hosts to carry the transplanted tumor. As of July 1954, transplantation of the tumor was successful in 80 percent of the baby host rats inoculated, with an average latent period of 6.6 weeks. The host animals died approximately 10 days after the first appearance of leukemic cells in the circulating blood. When Chloroleukemia 123 was inoculated by the intraperitoneal route, its effect on the host was usually manifested by the development of leukemic blood and only occasionally by the formation of a local tumor. However, when 0.2 cc. of whole blood from a leukemic donor was inoculated subcutaneously, the results in 35 of 64 animals so treated were as follows: only 3 developed leukemic blood without local tumor, 13 had chloromas but no leukemic blood, and 19 developed both leukemic blood and local chloromas 1 to 9 weeks after injection. (Many of these data were kindly contributed by Dr. Charles Harris and Mrs. Margot Gruenstein of the Fels Research Institute, Philadelphia, Pa.)

DESCRIPTION OF CURRENT TUMOR. At necropsy of the host rat bearing Chloroleukemia 123, the organs and tissues involved by the neoplasm generally reveal a greenish color. The sites of tumor deposits may include the intra-abdominal fat, lymph nodes, thymus gland, bone marrow, portal areas of liver, galea, dura, cranial bones, ribs, and vertebrae. In contrast to the other organs, the spleen does not display a greenish color, even though it is invariably infiltrated by leukemic cells.

Under ultraviolet light, the lesions of Chloroleukemia 123 show the same red fluorescence as do chloromas of man. Schultz and associates have shown that the red fluorescence of the chloroma of the rat is due at least in part to a porphyrin that appears to be dicarboxylic acid and which has the solubility and spectrophotometric absorption characteristic of protoporphyrin. A green pigment has been isolated from the lesions of Chloroleukemia 123. This pigment is slightly soluble in saline but insoluble in 65 to 70 percent alcohol; it possesses a high peroxidase activity with an absorption spectrum closely resembling that of verdoperoxidase.

The abnormal cells observed in the organs and tissues of the host animal bearing Chloroleukemia 123 consist chiefly of small blast cells, myelocytes, and ring form granulocytes (figs. 61–66). Large phagocytes with engulfed eosinophilic material and chromatin, evidently the products of degenerated neoplastic cells, are also commonly found. A study of the peripheral blood of one of the tumor-bearing hosts shortly before death is as follows:

Hemoglobin 7.5 grams
Red blood cells 5,220,000 per cu. mm.
White blood cells 111,000 per cu. mm.
Platelets 417,000 per cu. mm.

The differential white blood cell count: promyelocytes, 6 percent; myelocytes, 18 percent; metamyelocytes, 43 percent; stabs, 13 percent; segmented forms, 7 percent; small lymphocytes, 13 percent; 2 nucleated red blood cells per 100 white blood cells counted.

References

Dunn, T. B. Normal and pathologic anatomy of the reticular tissue in laboratory mice, with a classification and discussion of neoplasms. J. Nat. Cancer Inst., 14:1281–1433, 1954.

Gruenstein, M., and Shay, H. Technics in transfer of leukemias induced in rats by gastric instillation of methylcholanthrene. Laborat. Invest., 4:406–413, 1955.

Shay, H., Gruenstein, M., and Harris, C. The effect of triethylene thiophosphoramide (Thio-TEPA) in the treatment of chronic myelocytic chloroleukemia in the rat. J. Nat. Cancer Inst., 15: 463–481, 1954.

———, Gruenstein, M., Harris, C., and Glazer, L. Transfer of myelogenous leukemia induced by gastric instillation of methylcholanthrene in Wistar rats. Blood, 7:613–622, 1952.

———, Gruenstein, M., Marx, H. E., and Glazer, L. The development of lymphatic and myelogenous leukemia in Wistar rats following gastric instillation of methylcholanthrene. Cancer Research, 11:29–34, 1951.

Schultz, J., Shay, H., and Gruenstein, M. The chemistry of experimental chloroma. I. Porphyrins and Peroxidases. Cancer Research, 14:157–163, 1954.

Sparks, S. J., Walsh, M. E., Sebastianelli, L., Stevens, M., Landes, J., Halliday, S. L., and Oleson, J. J. Chemotherapy of a granulocytic chloroleukemia in the rat. Cancer Research, 14:753–757, 1954.

Wilens, S. L., and Sproul, E. E. Spontaneous leukemia and chloroleukemia in the rat. Am. J. Path., 12:249–258, 1936.

LYMPHOCYTIC LEUKEMIA

Leukemia Line I (MacDowell). Mouse

DEFINITION. A transplantable line of lymphocytic leukemia that arose spontaneously in a strain C58 mouse.

HISTORY AND DESCRIPTION OF ORIGINAL TUMOR. In 1926 Richter and MacDowell found that a large number of strain C58 mice, six months or more of age, developed lymphocytic leukemia. A study of this disease was undertaken two years later, and several transplantable lines of leukemia, designated by the letters of the alphabet, were established.

CHLOROLEUKEMIA 123, SHAY. RAT

(Tumor-bearing animal courtesy of Dr. Harry Shay, Fels Research Institute, Temple University School of Medicine, Philadelphia, Pa.)

Figure 61. Section of liver from a rat bearing the transplanted tumor. Note the leukemic infiltration in the portal areas. Hematoxylin and eosin stain. X 70. N. C. I. 9202; A. F. I. P. Acc. No. 219934–61.

Figure 62. Section of lung from a rat bearing the transplanted tumor. This shows leukemic cell infiltration around the blood vessels and in the alveolar septa. Hematoxylin and eosin stain. X 315. N. C. I. 9212; A. F. I. P. Acc. No. 219934–62.

Figure 63. Section of ganglion and fatty tissue from the mediastinum of a rat bearing the transplanted tumor. This shows infiltration of leukemic cells. Hematoxylin and eosin stain. X 94. N. C. I. 9207; A. F. I. P. Acc. No. 219934–63.

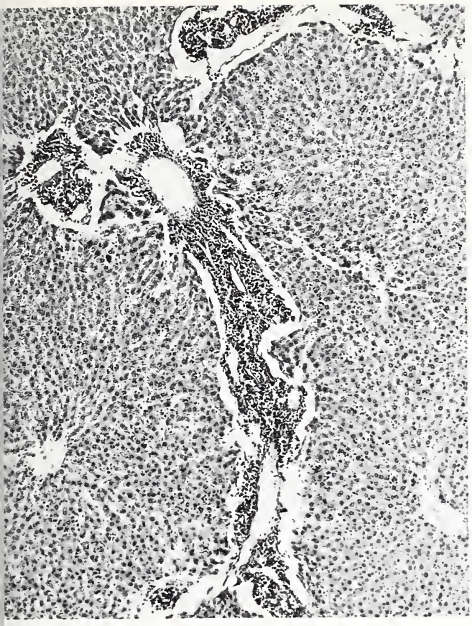

Fig. 61

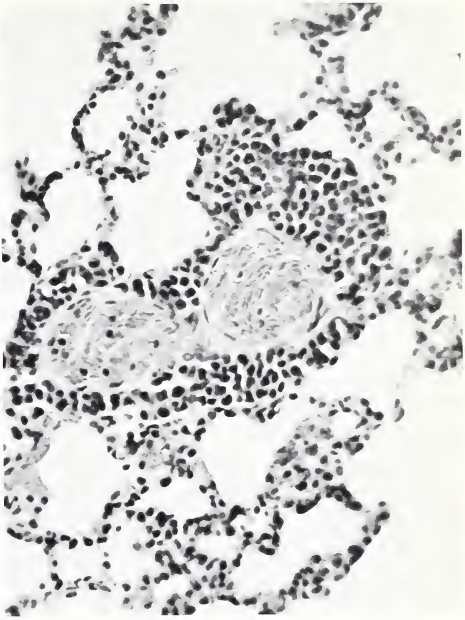

Fig. 62

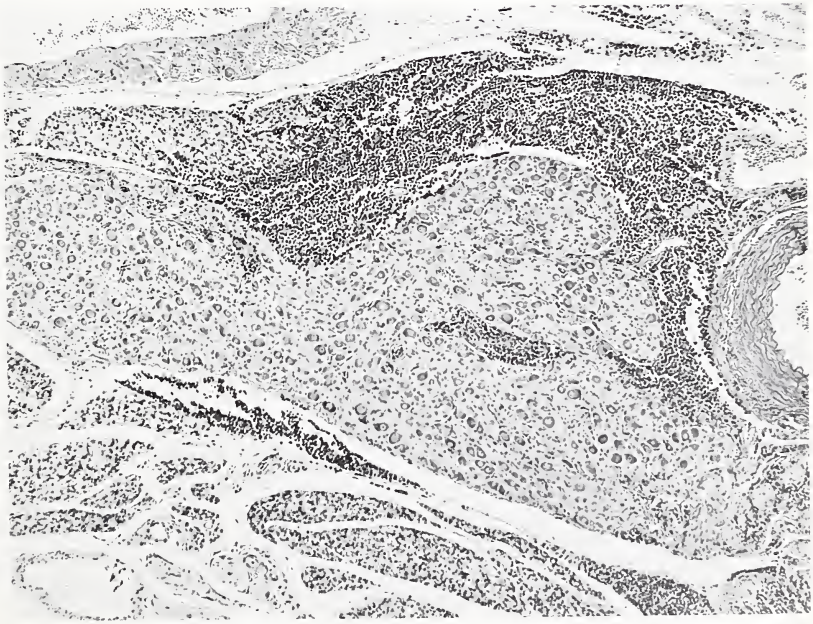

Fig. 63

CHLOROLEUKEMIA 123, SHAY. RAT

Figure 64. Section of sternum from a rat bearing the transplanted tumor. There is replacement of the marrow and infiltration of adjacent muscle by leukemic cells. Hematoxylin and eosin stain. X 94. N. C. I. 9205; A. F. I. P. Acc. No. 219934–64.

Figure 65. Section of fat tissue from the cervical region of a rat bearing the transplanted tumor. This shows infiltration of leukemic cells. Hematoxylin and eosin stain. X 330. N. C. I. 9215; A. F. I. P. Acc. No. 219934–65.

Figure 66. Section of lymph node from a rat bearing the transplanted tumor. This shows replacement of the node by leukemic cells. Hematoxylin and eosin stain. X 82. N. C. I. 9203; A. F. I. P. Acc. No. 219934–66.

Fig. 64

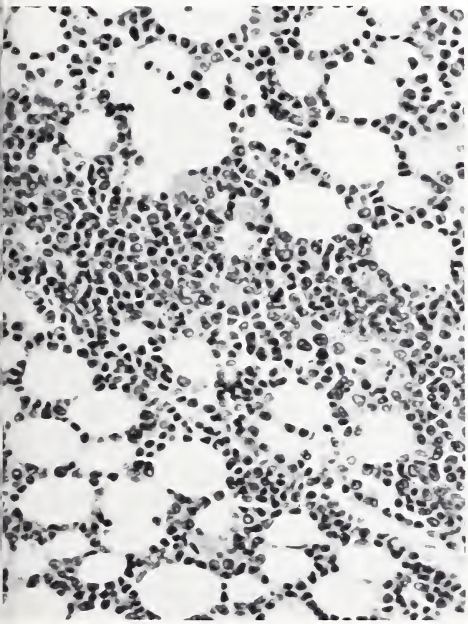

Fig. 65

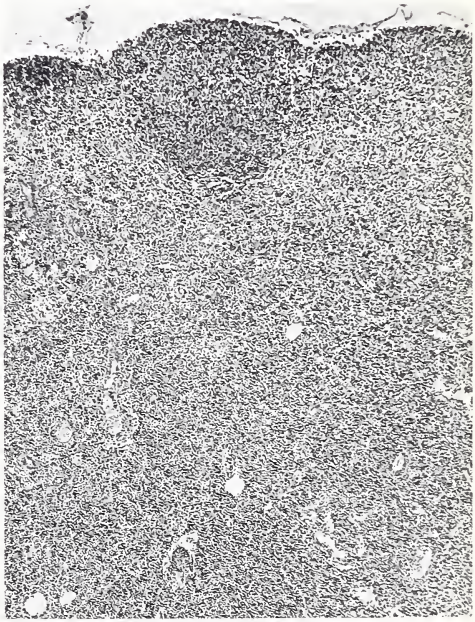

Fig. 66

Leukemia Line I arose spontaneously in a male mouse of the 17th inbred generation of strain C58 from the colony maintained by E. C. MacDowell at Cold Spring Harbor, New York. This mouse was found to have a palpably enlarged spleen at 11 months of age and was taken to the department of pathology of the College of Physicians and Surgeons, Columbia University, New York City, where a blood count revealed 42,500 white blood cells per cu. mm. The mouse was killed and necropsied on April 12, 1929. The thymus gland and the mesenteric, lumbar, and renal lymph nodes, as well as the spleen, were all found to be enlarged. The lungs, liver, kidneys, and the axillary and inguinal lymph nodes showed no significant change on gross examination. Histologic study revealed the presence of neoplastic cells considered to be of lymphocytic type in the lymph nodes, lungs, liver, and spleen.

TRANSPLANTATION STUDIES. The spleen of the animal in which Line I Leukemia originated was minced in sterile normal saline, and the suspension was inoculated intraperitoneally into four strain C58 mice approximately two months of age. All four mice developed leukemia and either died or were killed 43 to 62 days after inoculation. The interval between inoculation of the animal and its death from leukemia gradually became shortened during the next several years. In 1933 a standard dose of about 80 million Line I cells killed the host in 3 to 4 days, and, using this dose, no further decrease in the interval was noticed over a period of the next 20 years. When dilutions of the standard dose were used, there was found to be a rather close correlation between the number of cells in the inoculum and the average interval between inoculation and death. Thus, an inoculum of 20,000 cells killed mice in eight days, and an inoculum of 1,200 cells in 10 days. A dose of 19 cells killed 63 percent of 159 mice at an average interval of 12.5 days. These correlations, first reported in 1936, also held true in 1949 after Line I had been freed from a virus with which, as described hereinafter, it had been previously contaminated.

In genetic studies in which cells of Line I were transplanted into the various hybrids from the cross between the susceptible strain C58 and the resistant strain Storrs-Little, results were obtained indicating that the observed differences in suscepibility were controlled by one dominant gene.

DESCRIPTION OF CURRENT TUMOR. A 4-month-old male C58 mouse inoculated with about 300,000 Leukemia Line I cells is killed in extremis six and a half days later. This animal had been inoculated with a strain of the leukemia that Dr. Edgar Hurst of the Johns Hopkins Hospital in Baltimore, Maryland, had obtained from Dr. J. Syverton, of the University of Minnesota in Minneapolis, who had preserved the cells in the frozen state for some time. The pathologic alterations in this mouse are essentially similar to those of several other mice killed four days after inoculation with a standard dose of 80 million Line I Leukemia cells of a subline that had never been preserved in the frozen state. The spleen measures 3.2 cm. in length. The liver is pale

and rather soft. The subcutaneous and intra-abdominal lymph nodes are noticeably enlarged and on section reveal small foci of hemorrhage. The thymus gland is slightly if at all enlarged. The markings of the pancreas are lost within a mass of neoplastic tissue.

Microscopic examination reveals that leukemic cells are present in the chambers of the heart and in the lumen of many of the blood vessels in all parts of the body. Many of the organs and tissues are infiltrated by leukemic cells. The most pronounced degree of this infiltration is present in the liver, where aggregates of leukemic cells are found in the portal areas, around the central vein, and to a lesser extent in the sinusoids. Leukemic cells are especially numerous within the intrahepatic branches of the portal and hepatic veins (fig. 67).

In the lymph nodes, the infiltrated leukemic cells are numerous in the medullary cords and in the cortical sinuses. As the leukemic cells multiply, they apparently crowd out the lymphatic follicles and so replace large areas of some nodes. Such areas may show foci of necrosis. Follicles in which the structure is still preserved show evidence of phagocytosis at the center. The infiltrating leukemic cells in the thymus gland are present chiefly in the perivascular tissue. Many of the cells of the thymus gland itself are necrotic. In the spleen the perifollicular region is most consistently involved, and from here the leukemic cells extend in all directions, encroaching upon the follicles, and spreading out in tonguelike projections into the pulp (fig. 68). The pulp is congested, and within it there are foci of necrosis.

The marrow spaces of the vertebrae and sternum are full. Cells of the granulocytic series and megakaryocytes predominate, with foci of erythropoiesis infrequently encountered. Collections of leukemic cells are small and not numerous and are located chiefly near the line of ossification. Cellular elements of the bone marrow as well as leukemic cells are present in the tissue of the intervertebral foramens. The brain is not involved by the leukemic process, but a few leukemic cells are found in fibrofatty tissue in relation to the auditory canal.

The renal tissue is only slightly infiltrated with leukemic cells. These appear in the perivascular tissue of the small arteries of the cortex, in the glomeruli, and beneath Bowman's capsule. In the adrenal gland, the leukemic cells are chiefly confined to the subcapsular area of the cortex. Leukemic cells are numerous within the septa of the lungs and around the bronchi and blood vessels, some small branches of which are thrombosed (fig. 69). A few foci of leukemic cells are found in the myocardium.

The fibrofatty tissue of the mesentery, greater omentum, genital omentum (fig. 70) and mediastinum, as well as that surrounding the lymph nodes, adrenal glands, and the kidneys (fig. 71), contains densely packed accumulations of leukemic cells. These cells are very numerous around the blood vessels and are also to be found infiltrating nerves and ganglia (fig. 72). Many indi-

vidual pancreatic acini and sometimes entire lobules of the pancreas may be seen in various stages of destruction due to the infiltration of leukemic cells (fig. 73). Foci of leukemic cells in the muscularis of the stomach probably represent extensions from the neoplastic lesions in the pancreas and the mesentery.

The leukemic cells are round or slightly oval, having about twice the diameter of a small lymphocyte (figs. 74, 75). The nucleus is coarsely lobulated. It occupies an eccentric position and fills most of the cell, leaving a small amount of nongranular cytoplasm. The nucleus usually contains one large, heavily stained nucleolus. Mitotic figures are frequent and usually normal in form. The cytoplasm is colored an intense purple with Giemsa stain.

MECHANISM OF SPREAD. The leukemic cells were traced step by step from the mass of original inoculum to their final widespread dissemination in the body of the host. All significant organs and tissues of a number of mice, taken at intervals after intraperitoneal or intramuscular (leg) inoculation, were studied in serial section by Potter and Richter. The inoculated cells migrated from their original position, continually dividing as they spread further and further through the body, following fascial planes or lymph channels or penetrating directly through membranes into organs and lymph nodes. In this primary invasion, leukemic cells did not migrate by way of the blood vessels. The spleen was infiltrated before any significant appearance of the leukemic cells in the blood. Within three days of death, the number of circulating white blood cells usually increased suddenly, and the majority of leukocyte counts were over 100,000 cells per cu. mm. In this whole process, the lymphoid tissues of the host showed no increased activity, and the enlargement of the organs was due to the invading cells.

THE MORPHOLOGY OF THE LINE I LEUKEMIA CELL. In 1932 Potter and Richter described the morphologic characteristics of the leukemic cells in tissue sections of mice killed at different intervals after intraperitoneal inoculation with Line I Leukemia. The cell type in Line I Leukemia has been studied so carefully and described in such detail by Potter and Richter (p. 301) that it seems worthwhile to quote rather extensively from their work which might serve as a model for investigators in the future.

"The accumulations of cells in the lymphatic tissues and elsewhere appear to consist predominantly of a large type cell of the lymphatic series. This is true of all stages up to the death of the animal. A series of measurements in sectioned material placed the size range of the cell type between 9 and 11 micra when rounded up.

"This cell type has a moderate amount of cytoplasm containing many large, round mitochondria . . . which, with one or several vacuoles, are usually located near to the nuclear membrane, and have been observed in a number of cases to clump in a position near to the nucleolus. There may

be a few azure granules or none at all. Observations on basophilia as described by Wiseman indicated that the majority of the cells were young.

"The nucleus is usually irregular in shape. The position and size of the nucleolus and the arrangement of the chromatin may best be demonstrated by the Feulgen technique, in which the nucleolus takes a brilliant green from the light green counter-stain in contrast to the purple of the chromatin. The nucleolus is a large, elongated plasmasome, irregular in shape and adherent through most of its length to the nuclear membrane. . . . During the 'resting' condition the chromatin is dispersed in an open network with a tendency to clump about the nucleolus. . . . The size and position of the plasmasome and the arrangement of the chromatin complement become identifying features of the cell type.

"Cell division is found in every section of the areas affected. In some of the earlier stages of infiltration about fifty percent of the cells involved have been observed in some active stage of division.

"During the early prophase the spireme is coarse and is in the form of loops radiating from a point adjacent to the plasmasome. The strands of the loops usually adhere to the nuclear membrane, making it possible to count the strands in optical section . . . and giving a striking appearance to this stage. At the time of fragmentation of the spireme and formation of the individual chromosomes, the plasmasome has disappeared entirely.

"Because of the tendency of the chromosomes to split precociously at metaphase, late prophase was found to be the best time at which to make counts of the chromosomes. . . . A series of fifty counts was made in areas of accumulated cells in different tissues and at various stages of development following inoculation. Camera lucida outlines of the chromosomes were made to facilitate counting and to insure accuracy. The number in the figures examined was invariably forty, the 2n number reported for the mouse. . . .

"No variation from normal metaphase and anaphase was observed except in areas with much cellular degeneration. The abnormalities were so rare, however, that they are interpreted as being of no consequence in the continuity of a cell type, but rather the result of abnormal physiological conditions in the degenerative areas. Abnormal mitotis is atypical of most stages of this line of leukemia. . . .

"Abnormal 'inclusion bodies' have not been observed so far. The peroxidase reaction of the cell type is negative. . . .

"Observations in the developing liver of mouse embryos and in lymphatic tissues in unweaned and maturing mice of different strains revealed cells of a type morphologically identical to the cell type predominating in the areas of infiltration in the inoculated mice. In the infiltrated areas intermediate stages appear between the cell type described here and the normal small lymphocyte of the mouse."

TUMOR IMMUNITY STUDIES AND VIRAL CONTAMINATION. Experiments carried out in MacDowell's laboratory revealed that C58 mice could be made resistant to Line I Leukemia. It was found that active resistance to the standard dose could be induced by giving survivors of small doses of viable leukemic cells repeated and increasingly larger doses. Active resistance could also be induced by inoculating C58 mice with heated Line I leukemic tissue, with Line I leukemic cells broken up by sonic oscillation, or with tissues taken from a genetically different strain of mouse. Passive resistance could be induced by inoculating C58 mice with tissues taken from other mice of the same strain in which active resistance had previously been induced.

In the course of the study of the experimental induction of resistance to Line I Leukemia, it became evident that some factor, aside from the leukemia, was causing an illness in the mice. A self-reproducing agent, apparently a virus, was isolated from Line I Leukemia in 1947 by Taylor and MacDowell. In reviewing past experiments, they found evidence indicating that this agent had been carried along with the leukemic cells for more than a decade. Mice surviving their first dose of Line I cells developed a mild nonlethal illness clinically identical with that later shown to be virus induced. The disease was manifested by a sudden loss of weight, inactivity, moist hair, sticky eyes, and a moderate lymphocytosis. The spleen and lymph nodes became enlarged, but the thymus gland underwent involution. Animals that recovered were invariably resistant to reinfection with the agent. To free Line I Leukemia from this agent, the infection was first induced in mice by inoculating them with a filtrate containing the agent but no leukemic cells. Upon recovery, the mice were immune to the virus and were then used as hosts for inoculation of Line I Leukemia. The leukemic lesions that developed after Line I had been passed through virus-immune mice were found to be free from virus.

A comparison of animals inoculated with the virus-free subline of Line I Leukemia with those inoculated with the virus-contaminated subline revealed certain differences. It was found that the presence of the virus in leukemic animals was responsible for slight shortening of the interval between inoculation and death from leukemia, slight retardation in the enlargement of the spleen, intensification of the hyperemia of leukemic lesions, and the more frequent occurrence of small pulmonary hemorrhages. After Line I was freed from the contaminating virus, the mechanism for inducing resistance to the leukemia by the inoculation of progressively larger doses of Line I cells failed to operate since even very small doses of leukemic cells killed all mice inoculated. It may be that the virus inhibited in some way the proliferation of the leukemic cells without destroying their capacity to induce resistance. (Miss Martha Taylor of Fort Detrick, Md., kindly gave us much assistance in the preparation of this section of the manuscript.)

References

Biesele, J. J. Chromosomes in lymphatic leukemia of C58 mice. Cancer Research. 7:70–77, 1947.

Dunn, T. B. Normal and pathologic anatomy of the reticular tissue in laboratory mice, with a classification and discussion of neoplasms. J. Nat. Cancer Inst., 14:1281–1433, 1954.

MacDowell, E. C. Genetic aspects of mouse leukemia. Am. J. Cancer, 26:85–101, 1936.

_____, and Richter, M. Studies on mouse leukemia. V. A genetic analysis of susceptibility to inoculated leukemia of Line I. Biolog. Zentralbl., 52:266–279. 1932.

_____, Potter, J. S., and Taylor, M. J. The influence of transplantation upon immunological properties of leukemic cells. Proc. Nat. Acad. Sc., 25:416–420, 1939.

_____, Taylor, M. J., and Broadfoot, J. Mouse Leukemia. Carnegie Inst. of Washington Year Book, 49:178–181, 1950; 50:200–203, 1951.

_____, Taylor, M. J., and Lewis, L. Mouse Leukemia. Carnegie Inst. of Washington Year Book, 47:189–193, 1948; 48:185–188, 1949.

_____, Taylor, M. J., and Potter, J. S. Immunization of mice naturally susceptible to a transplantable leukemia. Proc. Soc. Exper. Biol. & Med., 32:84–86, 1934.

_____, Taylor, M. J., and Potter, J. S. The dependence of protection against a transplantable mouse leukemia upon the genetic constitution of the immunizing tissue. Proc. Nat. Acad. Sc., 21:507–508, 1935.

_____, Taylor, M. J., and Stuard, B. Mouse Leukemia. Carnegie Inst. of Washington Year Book, 51:190–193, 1952.

_____, Potter, J. S., Victor, J., Taylor, M. J., Findley, M. D., Laanes, T., Ward, E. N., and Wintersteiner, M. P. Leukemic Studies. Carnegie Inst. of Washington, pp. 45–49, 1936.

_____, Potter, J. S., Richter, M. N., Victor, J., Bovarnick, M., Taylor, M. J., Ward, E. N., Laanes, T., and Wintersteiner, M. P. Experimental Leukemia. Carnegie Inst. of Washington, pp. 47–52, 1938.

Potter, J. S., and Richter, M. N. Studies of mouse leukemia. VI. The predominating cell type in Line I. Proc. Nat. Acad. Sc., 18:298–303, 1932.

_____, and Richter, M. N. Mouse leukemia. VIII. Continuity of cell lineage in transmission lines of lymphatic leukemia. Arch. Path., 15:198–212, 1933.

_____, Taylor, M. J., and MacDowell, E. C. Transfer of acquired resistance to transplantable leukemia in mice. Proc. Soc. Exper. Biol. & Med., 37:655–656, 1938.

Richter, M. N., and MacDowell, E. C. Studies on leukemia in mice. I. The experimental transmission of leukemia. J. Exper. Med., 51:659–673, 1930.

_____, and MacDowell, E. C. Studies on mouse leukemia. III. A comparison of four lines of leukemia transmited by inoculation. J. Exper. Med., 52:823–833, 1930.

_____, and MacDowell, E. C. Experiments with mammalian leukemia. Physiol. Rev., 15: 509–524, 1935.

Taylor, M. J., and MacDowell, E. C. Mouse leukemia. XIV. Freeing transplanted Line I from a contaminating virus. Cancer Research, 9:144–149, 1949.

Murphy-Sturm Lymphosarcoma. Rat

DEFINITION. A malignant lymphoma induced in a Wistar rat by dibenzanthracene and which has the characteristics of lymphosarcoma or lymphocytic leukemia or both, depending upon the technic of transplantation.

HISTORY AND DESCRIPTION OF ORIGINAL TUMOR. This lymphocytic neoplasm arose in a Wistar rat in 1938 in the laboratory of J. B. Murphy and E. Sturm at the Rockefeller Institute for Medical Research, New York City. A local nodule was found six weeks after the rat had received the second of two

LEUKEMIA LINE I (MACDOWELL). MOUSE

(Histologic sections courtesy of Dr. L. W. Law, National Cancer Institute, Bethesda, Md.; tumor-bearing animal courtesy of Dr. Edgar Hurst, Johns Hopkins Hospital, Baltimore, Md.)

Figure 67. Section of liver of a mouse inoculated with Leukemia Line I, showing aggregates of leukemic cells in the portal areas, around the central vein, in the sinusoids, and in the lumens of the vessels. Hematoxylin and eosin stain. X 100. N. C. I. 9625; A. F. I. P. Acc. No. 219934–67.

Figure 68. Section of spleen of a mouse inoculated with Leukemia Line I, showing extensive infiltration of leukemic cells. A remnant of a follicle is present at the lower right margin. Hematoxylin and eosin stain. X 235. N. C. I. 9639; A. F. I. P. Acc. No. 219934–68.

Figure 69. Section of lung of a mouse inoculated with Leukemia Line I. Leukemic cells are numerous within the septa and around the bronchi and blood vessels. Hematoxylin and eosin stain. X 105. N. C. I. 9628; A. F. I. P. Acc. No. 219934–69.

Figure 70. Section of genital omentum of a mouse inoculated with Leukemia Line I. Note infiltration of leukemic cells. Hematoxylin and eosin stain. X 66. N. C. I. 9630; A. F. I. P. Acc. No. 219934–70.

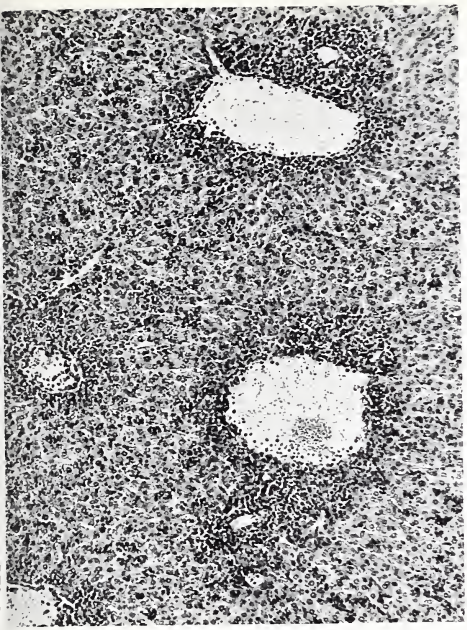

Fig. 67

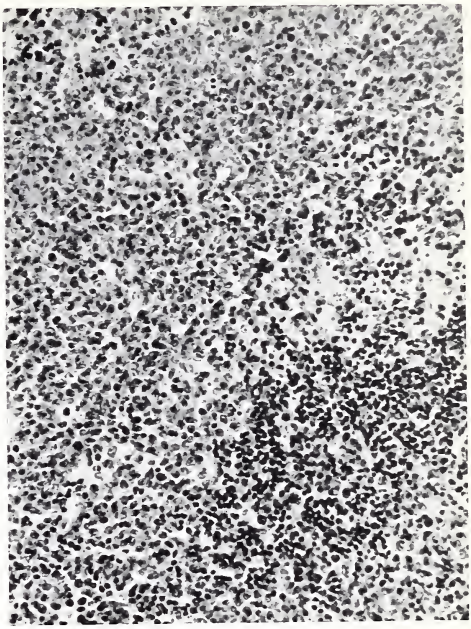

Fig. 68

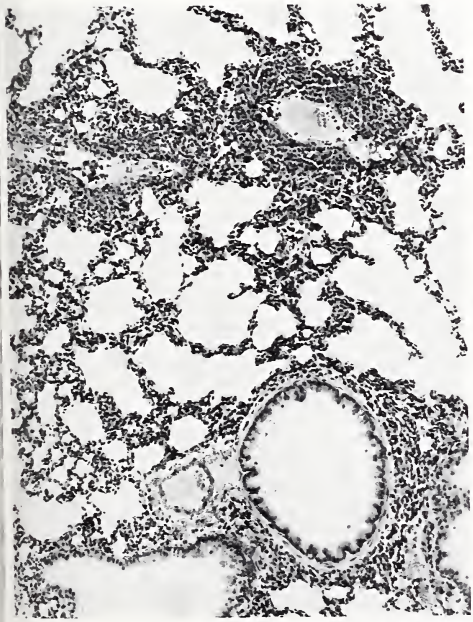

Fig. 69

Fig. 70

LEUKEMIA LINE I (MACDOWELL). MOUSE

Figure 71. Section of perirenal fibrofatty tissue of a mouse inoculated with Leukemia Line I, showing infiltration of leukemic cells. Hematoxylin and eosin stain. X 235. N. C. I. 9638; A. F. I. P. Acc. No. 219934-71.

Figure 72. Section of autonomic ganglion of a mouse inoculated with Leukemia Line I, showing infiltration of leukemic cells. Hematoxylin and eosin stain. X 90. N. C. I. 9632; A. F. I. P. Acc. No. 219934-72.

Figure 73. Section of pancreas of a mouse inoculated with Leukemia Line I. Many individual acini may be seen in various stages of destruction due to infiltration of leukemic cells. Hematoxylin and eosin stain. X 290. N. C. I. 9635; A. F. I. P. Acc. No. 219934-73.

Figure 74. Leukemic cells from the region of the stomach of a mouse inoculated with Leukemia Line I. Hematoxylin and eosin stain. X 1800. N. C. I. 9649; A. F. I. P. Acc. No. 219934-74.

Figure 75. Blood smear of a mouse inoculated with Leukemia Line I. The leukemic cell (above) has about twice the diameter of the lymphocyte (below). Giemsa stain. X 1800. N. C. I. 9645; A. F. I. P. Acc. No. 219934-75.

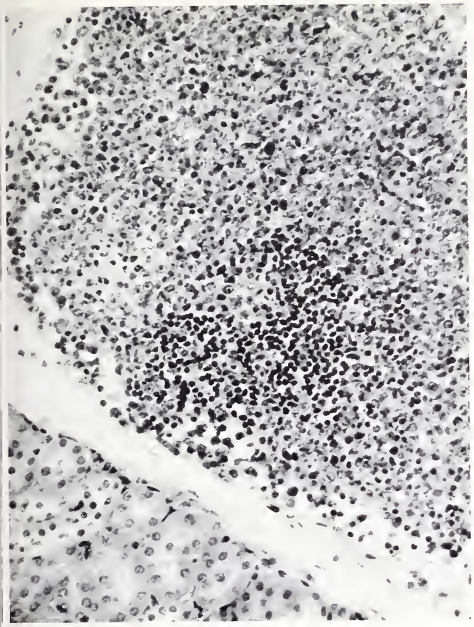

Fig. 71

Fig. 72

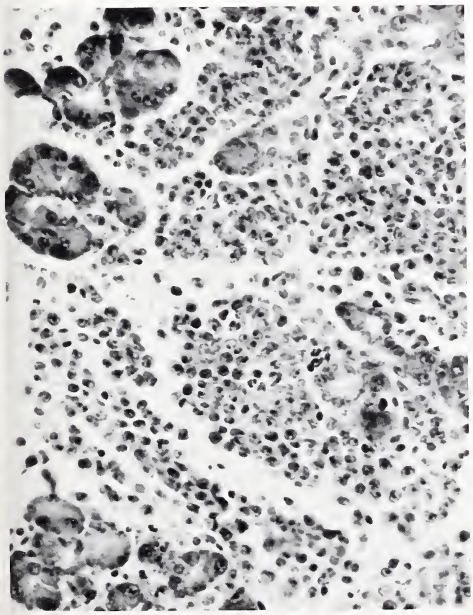

Fig. 73

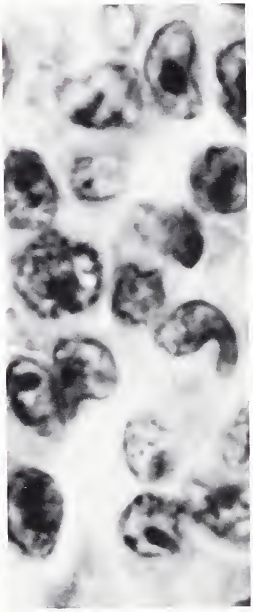

Fig. 74

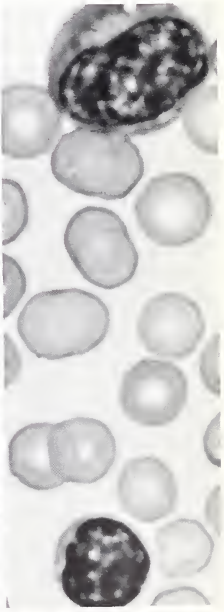

Fig. 75

injections of 0.5 cc. of a 3 percent solution of 1, 2, 5, 6-dibenzanthracene in benzol into the right and left inguinal region. The injections were given six weeks apart. The palpable nodule in the left groin measured 1.2 x 0.7 cm. A biopsy revealed an enlarged lymph node containing crystals of dibenzanthracene. Two weeks later, a mass was palpated in the right groin. A blood count showed 32,000 white blood cells per cu. mm.; 91 percent of the white blood cells observed in the smear were mononuclear cells of the lymphoid type. One week later, the white blood cell count had increased to 43,000 per cu. mm., and at that time the animal was killed.

At postmortem examination, the animal had bilateral inguinal masses and enlargement of the lymph nodes in the axillas, neck, and peritoneum. There was no involvement of the liver, spleen, kidneys, or other organs. Histologic examination of the lymph nodes revealed obliteration of architecture and replacement with closely packed abnormal mononuclear cells resembling lymphocytes. Crystals of dibenzanthracene were present in both inguinal lymph nodes. A diagnosis of lymphatic leukemia and lymphosarcoma was made.

TRANSPLANTATION STUDIES. Murphy and Sturm inoculated defibrinated leukemic blood from the original rat both subcutaneously (0.2 cc.) and intraperitoneally (0.4 cc.) into each of seven Wistar rats weighing about 65 gm. After two or three weeks, 3 of the 7 animals thus inoculated developed leukemic blood and neoplastic enlargement of the lymph nodes and thymus gland. Murphy and Sturm also minced the involved lymph nodes of the original animal and injected the cell suspensions subcutaneously (0.2 cc.) and intraperitoneally (0.5 cc.) into seven other Wistar rats. Four of these rats developed leukemic blood and enlargement of lymph nodes and thymus gland. A thin plaque of tissue was present at the site of the subcutaneous inoculation in some of the leukemic animals of both groups. These leukemic animals died about five weeks after inoculation. During the first 5 generations, leukemia developed in from 60 to 80 percent of the hosts, and the average period of survival was approximately two weeks. In succeeding generations, leukemia developed in from 90 to 100 percent of recipients, and they lived only 6 to 10 days.

Murphy and Sturm found that successful transplantation of this lymphoma was influenced by the strain of the recipient rat, its age at the time of inoculation, and the presence or absence of the adrenal glands. Inoculated intraperitoneally into young rats under five months of age, the tumor grew successfully in more than 90 percent of animals. When rats 12 to 15 months of age were used for inoculation, the tumor grew in less than 60 percent of these animals, and the average period of survival was 9.7 days. However, if the old rats were adrenalectomized prior to inoculation, the tumor grew in 90 percent of them, and the survival time decreased to about 6.2 days. Only occasionally could the tumor be transplanted to rats of strains other than the

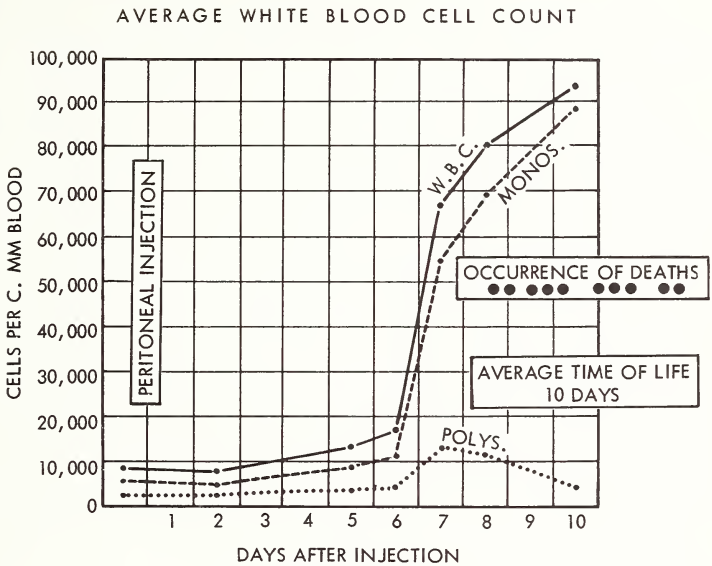

The white blood cell count following intraperitoneal inoculation of leukemia cells based on the average counts in 10 rats. The black circles indicate the time of death of the individual animals. (From Murphy, J. B., and Sturm, E. The transmission of an induced lymphatic leukemia and lymphosarcoma in the rat. Cancer Research, 1:380, 1941.)

Wistar. Hooded rats of the Rockefeller strain were particularly resistant to the growth of this tumor. However, when Sturm and Murphy adrenalectomized young hooded rats they found that the tumor grew in from 88 to 100 percent of them following intraperitoneal inoculation. The average survival time of these tumor-bearing adrenalectomized rats closely approximated that of Wistar rats inoculated with the Murphy-Sturm Lymphosarcoma.

Stasney observed either that animals died with lymphosarcoma within 14 to 15 days following intramuscular or subcutaneous inoculation with the Murphy-Sturm Tumor or that the growths became palpable and regressed within that time. Animals in which the tumor had regressed could not be successfully reinoculated. Stoerk found that resistance developed whether regressions occurred spontaneously or were induced by riboflavin deficiency. Moreover, resistance was induced in rats by injecting into them a suspension of lymphoid cells taken from rats in which implants of the Murphy-Sturm Lymphosarcoma had regressed. Stoerk also found that even injections of

homologous lymphoid cells of normal rats, and to a lesser extent of other tissues, produced a similar but more limited resistance to the growth of the transplanted tumor. Repeated injections with homologous lymphoid cells apparently sensitized the tissues of the recipient rat against lymphosarcoma cells in the same fashion as did regressing tumor transplants. The development of the resistance was prevented by the administration of cortisone. (Many of these data were contributed by Dr. J. Stasney of Jefferson Medical College, Philadelphia, Pa., and by Dr. H. C. Stoerk of the Merck Institute, Rahway, N. J.)

The present Murphy-Sturm Lymphosarcoma varies in its behavior in transplantation depending upon the site of inoculation. When tumor cells are injected intraperitoneally, the disease is manifested in the blood stream as leukemia, and there is lymphosarcomatous involvement of the thymus gland and lymph nodes. The bone marrow is partially replaced by neoplastic cells. Similar cells infiltrate the areolar and muscular tissues about the vertebrae and aorta. When circulating leukemic cells or cell suspensions of lymph nodes replaced by lymphosarcomatous tissue are injected subcutaneously or intramuscularly, a local lesion of lymphosarcoma almost invariably develops at the site of inoculation and later spreads to the regional nodes. Such inoculation does not eventuate in leukemic blood. However, animals inoculated intraperitoneally with the cells of the lymphosarcoma tissue that has thus been carried subcutaneously or intramuscularly for long periods of time do develop the blood picture of leukemia. Inoculation of leukemic blood into the spleen produces in the host the combination of leukemic blood and lymphosarcomatous involvement of the spleen, liver, and mesenteric nodes, but no involvement of other lymph nodes or of other viscera. The Murphy-Sturm Lymphosarcoma survives in the frozen state, is not transmissible by means of cell-free filtrates, and does not grow in other species. Although its virulence has increased during serial transplantation, the morphologic characteristics have remained essentially the same as those of the original tumor.

DESCRIPTION OF CURRENT TUMOR. The 14-day-old subcutaneous or intramuscular transplant of the Murphy-Sturm Lymphosarcoma is well circumscribed, although there is some infiltration of surrounding muscle and fascia. The cut surface of the tumor is grayish white, soft, and glistening. A central necrotic area is not often encountered. Large tumors have been described as showing ulceration, infection, and hemorrhage.

The solid tumor is composed of tightly packed cords, sheets, or coalescent nodules of ovoid or polyhedral tumor cells, 10 to 15 microns in diameter (fig. 76). Except for some slight variation in staining reaction, the cells are generally uniform in appearance. The cells possess a small amount of faintly basophilic cytoplasm that sometimes contains 1 or 2 small vacuoles. The cell membrane is rather indistinct. The nuclei are usually round, rarely lobate, and occupy an eccentric position. Some are hyperchromatic and so opaque that the intranuclear linin network and chromatin particles are somewhat obscured.

Other nuclei are larger, have a more open arrangement, and possess a well stained nuclear membrane. There are 1 or 2 irregularly shaped basophilic or acidophilic nucleoli in each nucleus. Mitotic figures are numerous, averaging two per oil immersion field. Most of them are normal in appearance, although tripolar and Y form mitotic figures may be found. Stasney stated that individual tumor cells seen on imprint slides bear a close resemblance to normal lymphocytes.

The tumor has little supporting connective tissue stroma of its own. Occasional collagenic fibers within a tumor nodule appear to belong to the host, and are therefore pre-existent. Throughout many parts of the tumor, fine reticular fibrils are found closely associated with individual tumor cells (fig. 77), while other large areas of the tumor appear devoid of reticulum.

Murphy and Sturm regarded the circulating leukemic cells as mononuclear cells of the lymphocytic type. However, the leukemic cells closely resemble monocytes of the circulating blood of normal animals. The leukemic cell averages 20 to 30 microns in diameter and is usually ellipsoid in shape. There is generally a clear zone in the cytoplasm which may contain several small azurophilic granules. The large nucleus may be round, oval or kidney shaped, and it is often eccentrically placed. It is reddish violet in the Wright preparation and contains large clumps of chromatin and 2 to 4 nucleoli. The nuclear membrane is indistinct.

References

Dunn, T. B. Normal and pathologic anatomy of the reticular tissue in laboratory mice, with a classification and discussion of neoplasms. J. Nat. Cancer Inst., 14:1281–1433, 1954.

Ellermann, V., and Bang, O. Experimentelle Leukämie bei Hühnern. Centrabl. f. Bakt., 1. Abt., 46:595–609, 1908.

Ingle, D. J., and Nezamis, J. E. Effect of cortisone acetate upon growth of a lymphosarcoma in the rat. Endocrinology, 48:484–485, 1951.

Kirschbaum, A. Rodent leukemia: recent biological studies. A review. Cancer Research, 11:741–752, 1951.

Murphy, J. B., and Sturm, E. The transmission of an induced lymphatic leukemia and lymphosarcoma in the rat. Cancer Research, 1:379–383, 1941.

Stoerk, H. C. Cortisone and immunity to homoiogeneous tissue—Loss of "individuality differentials" from tissues of cortisone-treated rats. In: Mechanism of Corticosteroid Action in Disease Processes. Ann. New York Acad. Sc., 56 (art. 4):742–747, 1953.

———, Budzilovich, T., and Bielinski, T. C. Resistance to grafting with lymphosarcoma cells in rats injected with homologous lymphoid cells. J. Mt. Sinai Hosp., 19:169–174, 1952.

Sturm, E., and Murphy, J. B. The effect of adrenalectomy on the susceptibility of rats to a transplantable leukemia. Cancer Research, 4:384–388, 1944.

Lymphoid Tumor RPL–16. Chicken

DEFINITION. A naturally occurring lymphoid tumor of the visceral type that arose in a white Leghorn chicken and that can be propagated by inoculation of tumor cells or of cell-free filtrates of the neoplasm.

MURPHY-STURM LYMPHOSARCOMA. RAT

(Tumor-bearing animal courtesy of Dr. Kanematsu Sugiura, Sloan-Kettering Institute for Cancer Research, New York City)

Figure 76. Photomicrograph of subcutaneous transplant tumor. The tumor is composed of tightly packed, fairly uniform cells. Hematoxylin and eosin stain. X 465. N. C. I. 8579; A. F. I. P. Acc. No. 219934–77.

Figure 77. Photomicrograph of subcutaneous transplant tumor. Fine reticular fibrils occur throughout many parts of the tumor and are sometimes closely associated with individual tumor cells. Wilder's silver preparation. X 440. N. C. I. 8685; A. F. I. P. Acc. No. 219934–78.

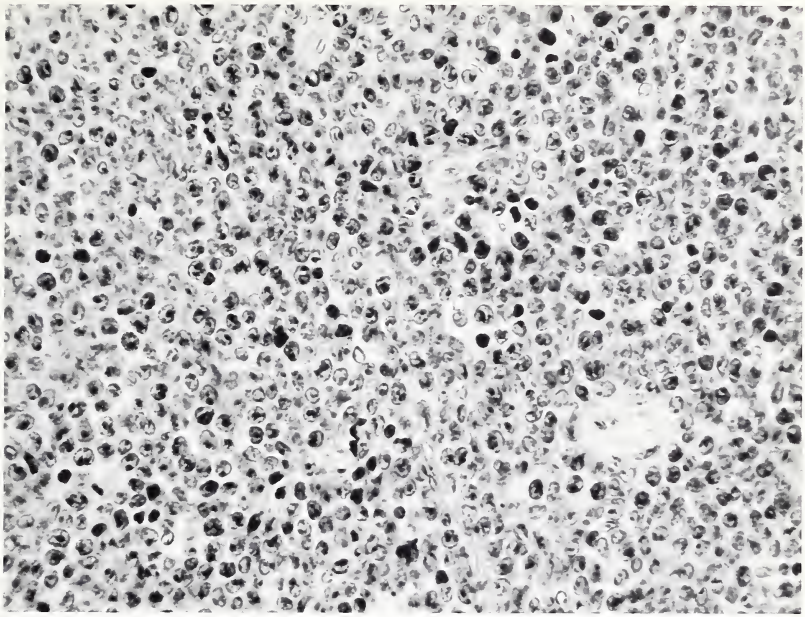

Fig. 76

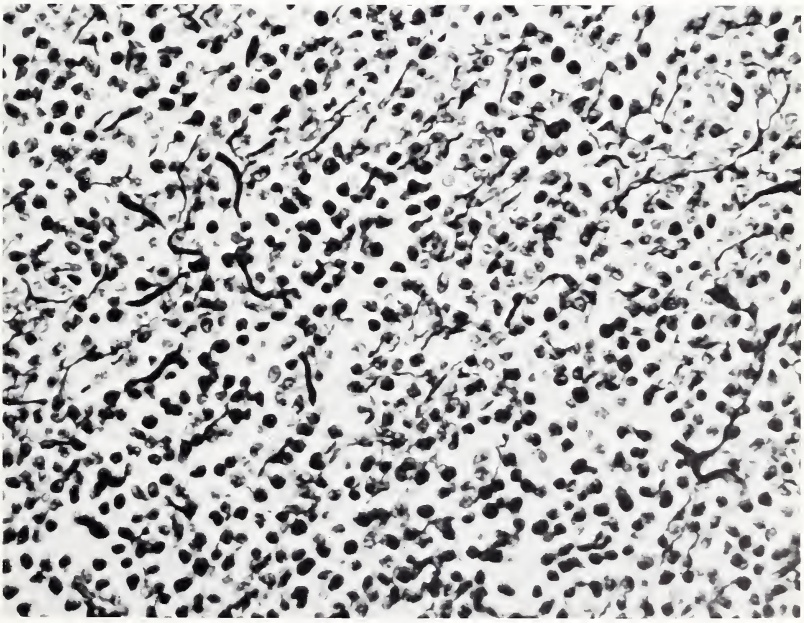

Fig. 77

HISTORY AND DESCRIPTION OF ORIGINAL TUMOR. Lymphoid Tumor RPL–16 was developed in 1944 at the U. S. Regional Poultry Research Laboratory, East Lansing, Michigan, in an effort to obtain a highly virulent strain of lymphomatosis of the fowl for experimental study. The necropsy findings in the chicken with visceral lymphomatosis from which the tumor line RPL–16 was derived were not described in detail. The statement was made, however, that the manifestations of the disease in this bird were similar to those described for visceral lymphomatosis.

TRANSPLANTATION STUDIES. Five-tenths of a cubic millimeter of a saline suspension of minced lesions of lymphomatosis from the liver of a chicken with the naturally occurring disease were injected intraperitoneally into 2-day-old white Leghorn chicks. Tumors arose in 10 of 19 birds inoculated. By the 3rd transplant generation, the disease could be transmitted to nearly 100 percent of birds inoculated subcutaneously and intramuscularly with a suspension of tumor cells. Nearly all of the tumor-bearing hosts died within 30 days. Necropsy revealed widespread tumor deposits in most of the viscera. By the 19th transplant generation, the tumor evidently became more virulent, for the inoculated host survived only 16 days. The tumor, originally inoculated into white Leghorn chickens, is now transplantable to various other breeds as well. A small percentage of birds appears to be naturally resistant. Once a tumor is established, it rarely regresses spontaneously. The tumor is generally transplanted into young chickens 10 to 20 days of age, because older chickens are less receptive to growth of the tumor.

RPL–16 can be transmitted by intraperitoneal or intravenous inoculation of a cell-free filtrate prepared from neoplastic tissue or from blood. Using such a procedure, the disease is detectable within 30 to 90 days. Tumors develop in 75 percent of the inoculated birds which rarely survive more than 12 months. At necropsy, there is focal or diffuse neoplastic involvement of the viscera, principally the liver, spleen, and kidneys.

When cell suspensions of RPL–16 are introduced into the breast muscle of young chicks under one month of age, the tissues in the area of inoculation become swollen by the fifth day, and most of the birds have died by the tenth or twelfth day. At necropsy, the breast muscles are found enlarged fourfold and diffusely infiltrated with tumor tissue. The central portion of this mass is usually necrotic and hemorrhagic. Many of the viscera, but particularly the liver, contain neoplastic deposits and tumor cells in vascular channels. Often there are associated blood stasis and hemorrhage. Burmester and Prickett stated that the predominant type of neoplastic cell resembles an immature lymphocyte, with basophilic cytoplasm and with a large nucleus containing variable amounts of chromatin. This type of cell predominates both in tumors at the site of inoculation and in the metastases. Mature lymphocytes are also present. An unusual number of immature circulating

white blood cells have been reported during the late stages of the disease, often not until within a few hours of death.

DESCRIPTION OF CURRENT TUMOR. Our study of the pathologic manifestations of RPL–16 is based upon material kindly made available to us by W. H. Eyestone of the National Cancer Institute, Bethesda, Maryland. He had inoculated 10,000 tumor cells into the breast muscles of a 10-day-old white Leghorn chicken. The breast muscles were palpably enlarged on the fourth day and had increased to four times their original size by the eleventh day, the day of death (fig. 78). At necropsy, a round gray tumor, 5 cm. in diameter, was found at the site of inoculation. Tumor tissue had also invaded the surrounding breast muscles. The center of the tumor was necrotic. The subcutaneous tissue around it was edematous. The liver was enlarged, the cut edges bulged, and hemorrhagic areas were present deep within the parenchyma as well as on the surface. The proventriculus was one-third larger than normal.

The cells of the tumor are fairly uniform in size, with an average diameter of 13 microns. The large nucleus of the tumor cell occupies approximately four fifths of the cell volume, thus leaving only a small peripheral rim of cytoplasm. The densely packed neoplastic cells are compressed into different shapes (fig. 79). Some tumor cells may possess cytoplasmic processes, and occasionally there is a suggestion of a syncytial pattern. Individual cells detached from one another are generally round or oval.

The cytoplasm of the tumor cells is deeply colored in the hematoxylin and eosin preparation and is dark blue with the Giemsa stain. It contains coarse, irregular, rather poorly defined granules. The nucleus is round or oval with a thick membrane beaded on its inner aspect with coarse chromatin granules. The linin network is open, giving a vacuolated appearance to the nucleus. One large, round or irregularly-shaped, eccentrically placed nucleolus is usually present, but a few of the cells contain two or more nucleoli. These nucleoli stain pale to deep blue with hematoxylin and eosin, bright red with Mallory's aniline blue, dark red with Masson's trichrome stain, dark gray with iron alum hematoxylin, and purplish blue with phosphotungstic acid—hematoxylin. Usually there is one mitotic figure per oil immersion field, although as many as six may be found. Only a few are abnormal in form.

Some areas of the tumor are rich in collagen and reticulum that evidently belong to the host. Large areas of the tumor are devoid of reticular fibrils. In still other areas, a fine reticulum, possibly newly formed with the tumor, is interspersed between individual tumor cells.

The tumor in the breast area is not very vascular. The blood vessels have thin walls and resemble capillaries. They may contain neoplastic cells in their lumens and sometimes in their walls. The central necrotic area of the tumor contains extravasated blood and a threadlike mucoid substance that is purplish red in the periodic acid—Schiff preparation. At the margin of the

area of necrosis, the surviving tumor cells encircle small blood vessels, thus imparting a peritheliomatous appearance to this portion of the neoplasm.

The tumor, although not encapsulated, is delimited in places by the fascial sheath of the muscle which appears to offer resistance to its spread. The skeletal muscle fibers in the region of the advancing margin of the neoplasm show loss of glycogen and striations, and finally cytolysis. Concomitant with these changes in the skeletal muscle fibers, the cytoplasm of the elongated or spindle-shaped tumor cells often becomes filled with granules of glycogen.

The neoplastic involvement of the liver and proventriculus is shown in figures 80, 81.

Lymphomatosis. Ellermann and Bang, in 1908, discovered a filtrable agent associated with certain lymphomatous neoplasms in the domestic chicken. This important observation probably represents the first definitive linking of an infectious agent to the transmission of a neoplasm. There is strong evidence that this agent is a virus. Lymphomatosis in the chicken is also of interest, because at least one form of the disease which is indeed cancerous is contagious and thus like an infectious disease. Under natural conditions, lymphomatosis appears to be transmitted from parent to offspring by way of the fertile egg or by contact with infected environment, possibly through the feces and by droplet infection from the respiratory tract.

At the Second National Cancer Conference in Cincinnati in 1952, Burmester reviewed the subject of fowl lymphomatosis, and much of the following description is taken from his paper. Four forms of lymphomatosis have been recognized on the basis of pathologic manifestations. These entities have been designated the ocular, the visceral, the neural, and the osteopetrotic forms. They may occur separately or in combination; for example, the neural-ocular, neural-visceral, and visceral-osteopetrotic forms. Whether these four entities have one common etiologic factor or separate and distinct causal agents is at present a matter of conjecture. Most of the lesions found in the instances of the ocular and the neural lymphomatoses are now thought to resemble reactive hyperplasia or an inflammatory process more than neoplasia.

As the terms indicate, the lesions of the various forms of lymphomatosis show a predilection for certain tissues. Thus, in neural lymphomatosis there are lymphoid deposits in the nerve trunks, leading to loss of function. In the visceral form, of which RPL–16 is representative, there are widespread lymphoid deposits in the viscera. The visceral and the neural forms of this disease are the two most important entities in the group. Their incidence ranges from a low percentage in some flocks to epizootic proportions in others. In the ocular form, the lymphoid deposits involve particularly the iris which becomes constricted, immobile, and gray, with resulting blindness. In osteopetrosis, alterations of the skeleton involve all the long bones, the pelvis, shoulder girdle, and occasionally the spine. The pathologic process affects

primarily the diaphysis and is ordinarily bilateral. The intensity of the bone lesion varies widely from exostosis-like cortical thickening to massive formation of hard bone, leading to almost complete obliteration of the marrow cavity. Since there is no infiltration of lymphocytes, there is some doubt that osteopetrosis should be classified with the lymphomatoses.

Other somewhat related forms of neoplasia are seen in chickens. One of these, erythromyeloblastosis, is a form of leukemia and seldom occurs under natural conditions. It is rarely if ever contagious. Many of the present lines of erythromyeloblastosis arose in the first few or several passages of tumor lines derived from naturally-occurring lymphomatosis. Other histologic types of tumor have also arisen in chickens used as hosts in transplantation of different lines of lymphomatosis. These neoplasms have been classified as endothelioma, hemangioendothelioma, and various forms of myxosarcoma. Although these latter types of tumor nearly always contain a filtrable transmitting agent, no evidence of direct or indirect contact transmission has been reported. There has been a good deal of speculation on, but no very clearly defined explanation for, the development of these latter varieties of neoplasm in the chicken.

The abdominal organs are principally affected in the naturally occurring visceral lymphomatosis, but all organs, including the skin and many other tissues, may at times be involved. The spleen is usually grayish brown and enlarged threefold. The liver is enlarged, grayish brown, and may be either granular or studded with firm gray nodules of lymphomatous tissue. The major lobes of the kidney are diffusely enlarged and gray. The heart may show myocardial or epicardial tumors, leading to deformities and adhesive pericarditis. The proventriculus, gizzard, lungs, mesentery, and gonads may all show similar invasion by gray nodules of neoplastic tissue. In the skin, there may be many small separate tumors of the feather follicles or large tumors that are prone to become ulcerated. The histopathologic picture of visceral lymphomatosis is comparatively uniform in all affected organs and tissues. Massive accumulations of lymphoid cells are much more widely distributed than is suggested by the gross alterations. The cells vary from small round cells resembling lymphocytes to large lymphoblast-like cells. Terminally, a moderate increase in circulating white blood cells may occur. Some authors have reported an increased number of circulating immature lymphocytes. Julian, however, found that the elevated white blood cell count was due to an increase in neutrophils and that the numerical level of erythrocytes, lymphocytes, and other white blood cell types was not markedly altered.

Visceral lymphomatosis can be transmitted experimentally by injecting pieces of the tumor tissue into the host chicken or by injecting cell-free filtrate preparations of tumor tissue or blood. After several transfers, and using cellular material for inoculation, lymphoid tumors grow readily when the inoculation is made intradermally, subcutaneously, intramuscularly, and intraperitone-

LYMPHOID TUMOR RPL-16. CHICKEN

(Histologic sections courtesy of Dr. W. H. Eyestone, National Cancer Institute, Bethesda, Md.)

Figure 78. Gross appearance of transplant tumor in the breast muscles 10 days following inoculation with a suspension of tumor cells. Natural size. (This is figure 1 in Eyestone, W. H. The behavior of a transmissible lymphoid tumor in the tissues of chickens inbred for resistance and susceptibility to spontaneous lymphomatosis. Am. J. Vet. Research, 14:594-600, 1953.) N. C. I. 5205; A. F. I. P. Acc. No. 219934-79.

Figure 79. Section through transplant tumor produced by an inoculation of a suspension of tumor cells into the breast area. There is extensive infiltration of neoplastic cells between the muscle fibers. Hematoxylin and eosin stain. X 380. N. C. I. 8742; A. F. I. P. Acc. No. 219934-80.

Figure 80. Section of liver of a chicken bearing the transplant tumor. Note neoplastic cells in the sinusoids. Hematoxylin and eosin stain. X 380. N. C. I. 6965; A. F. I. P. Acc. No. 219934-81.

Figure 81. Section of wall of the proventriculus of a chicken bearing the transplant tumor. Note neoplastic cells in all coats of the viscus. Hematoxylin and eosin stain. X 200. N. C. I. 8744; A. F. I. P. Acc. No. 219934-82.

Fig. 78

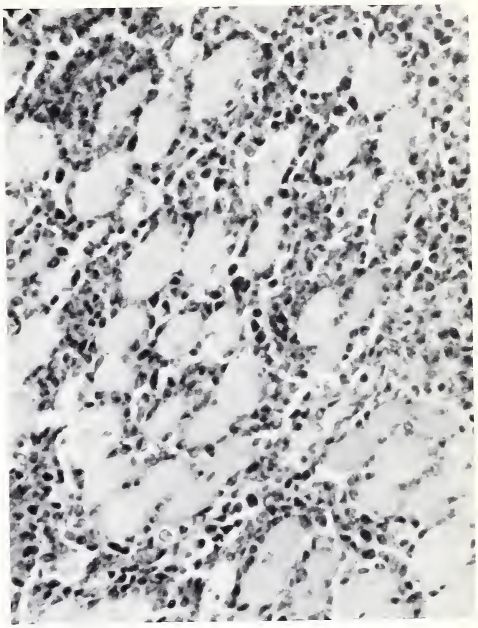

Fig. 79

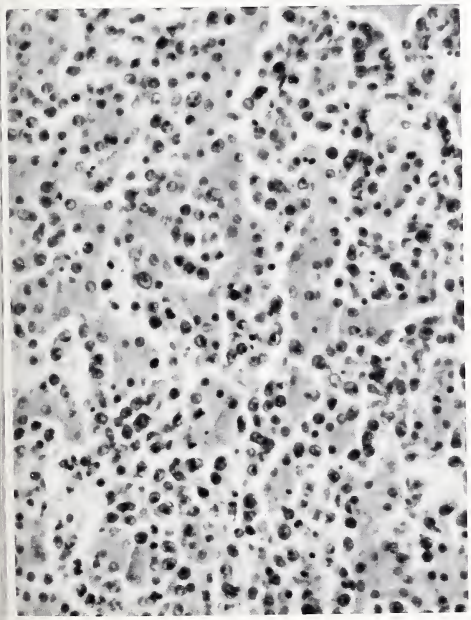

Fig. 80

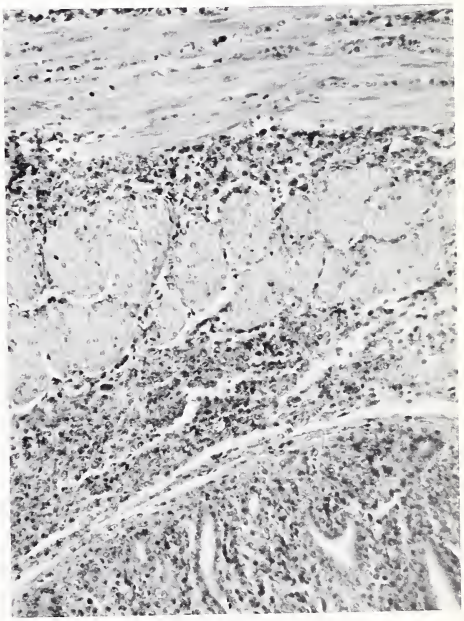

Fig. 81

ally. A tumor may become palpable at the site of inoculation of cells within four days, and death, due to the visceral manifestations of the disease, may occur within six days. The ease with which the neoplasm is transplanted varies in different flocks of chickens.

Inoculation of cell-free filtrates of the tumor gives results different from inoculation with cell suspensions of the same neoplasm. Regardless of the route by which the filtrate is introduced, tumors fail to occur at the point of inoculation. Instead, neoplastic deposits develop in one or more of the viscera after a relatively long incubation period. The age of the chicken at the time of inoculation exerts a pronounced effect upon the tumor incidence. For example, it has been observed that 95 percent of the chicks inoculated with filtrate at two days of age develop tumors, whereas only 31 percent of chickens inoculated at 114 days develop tumors. On the other hand, the latent period and the growth rate of the tumor, once established, are not influenced by the age of the bird at the time of inoculation. It is probable that the agent of lymphomatosis is present in all birds with this disease, although in some of them it is present in an inactive form. For example, cell-free filtrates of neoplastic tissue from the 1st generation tumor-bearing host may not induce tumors in recipient birds, whereas cell-free filtrates of later transplant generations of the same tumor line often produce a high incidence of tumors in inoculated hosts. An apparent loss in filterability has also been observed during the course of serial passage.

Cottral and co-workers have shown that the tissues and fluids of the chick embryo may contain the causative agent of visceral lymphomatosis. Experiments have indicated that the agent may remain latent in many apparently normal egg-laying chickens. This may be demonstrated by inoculation of suitable material derived from eggs of these apparently disease-free chickens into highly susceptible yet relatively disease-free stock.

References

Burmester, B. R. Recent advances in studies of fowl lymphomatosis, pp. 1384–1396. In: Proceedings of the Second National Cancer Conference, March 3, 1952, Cincinnati, Ohio. New York: American Cancer Society Publication, Vol. II, 1954.

_____. Immunity to visceral lymphomatosis in chicks following injection of virus into dams. Proc. Soc. Exper. Biol. & Med., 88:153–155, 1955.

_____, and Gentry, R. F. The transmission of avian visceral lymphomatosis by contact. Cancer Research, 14:34–42, 1954.

_____, and Prickett, C. O. The development of highly malignant tumor strains from naturally occurring avian lymphomatosis. Cancer Research, 5:652–660, 1945.

Cottral, G. E., Burmester, B. R., and Waters, N. F. The transmission of visceral lymphomatosis with tissues from embryonated eggs and chicks from "normal" parents. Poultry Science, 28:761, 1949.

Duran-Reynals, F. Virus-induced tumors and the virus theory of cancer. In: Homburger, F., and Fishman, W. H. (eds.). The Physiopathology of Cancer, pp. 298–337. New York: Paul B. Hoeber, Inc., 1953.

Ellermann, V., and Bang, O. Experimentelle Leukämie bei Hühnern. Centralbl. f. Bakt., 1. Abt., 46:595–609, 1908.

Eyestone, W. H. The behavior of a transmissible lymphoid tumor in the tissues of chickens inbred for resistance and susceptibility to spontaneous lymphomatosis. Am. J. Vet. Research, 14:594–600, 1953.

Feldman, W. H., and Olson, C., Jr. Neoplastic diseases of the chicken. In: Biester, H. E., and Devries, L. (eds.). Diseases of Poultry, pp. 523–597, chap. 30. Ames: Iowa State College Press, 1943.

Julian, L. M. Effect of transplantable lymphomatosis (strain RPL–16) on young, rapidly growing chickens. Am. J. Vet. Research, 14:601–608, 1953.

RETICULUM-CELL SARCOMA

Reticulum-cell Sarcoma 8469. Mouse

SYNONYMS: Transferable liver neoplasm; polymorphous-celled sarcoma; reticuloendotheliosis; monocytoma; histiocytoma; léucemie reticulaire.

DEFINITION. A reticulum cell sarcoma that arose spontaneously in a (C57L X A)F_1 mouse.

HISTORY AND DESCRIPTION OF ORIGINAL TUMOR. Reticulum-cell Sarcoma 8469 was found on June 3, 1948, in an 18-month-old female hybrid (C57L X A)F_1 mouse (formerly designated LAF_1) in the laboratory of T. B. Dunn at the National Cancer Institute, Bethesda, Maryland. At necropsy, there was pronounced distention of the abdomen due to the massive involvement of several organs and structures by tumor (fig. 82). The ovaries, uterus, liver, and lymph nodes were enlarged, but the spleen was free of tumor. The ovaries were firm and white. The wall of the vagina was thickened. There were firm yellowish white nodules of tumor tissue throughout the liver, and tumor implants were present on the diaphragm and mesenteries. Because of the widespread distribution of the neoplasm in this animal, the site of origin was not determined.

Microscopically, there was a good deal of variation in the morphology of the neoplastic cells in different organs and sites involved by tumor. In the wall of the vagina and in the periportal areas of the liver, the neoplasm was composed chiefly of spindle-shaped cells with heavily stained nuclei and relatively little eosinophilic cytoplasm. In other areas, particularly in the mesentery, most of the neoplastic cells were round and often vacuolated; a few giant tumor cells were also present. The sinuses of the lymph nodes were crowded with round mononuclear cells. Tumor cells of similar appearance were often found loosely attached to the endothelial surface of vessels, particularly in the lungs and liver. Minute, yellowish orange, rhomboid crystals were demonstrated in the fresh tumor tissue cleared with glycerine. According to Dunn, the presence of this pigment is a characteristic feature of reticulum cell sarcoma of the mouse.

At the National Cancer Institute, reticulum cell sarcomas similar to the one described here have been observed in mice of various strains, including the C3H, NHO, and C57BL strains. These neoplasms, regardless of the strain of mouse in which they originated, have been quite similar to each other with respect to sites of involvement, pattern of growth, diversity of cell type, and transplantation behavior.

TRANSPLANTATION STUDIES. Bits of tumor tissue from the uterus of the mouse bearing Reticulum-cell Sarcoma 8469 were transplanted subcutaneously by means of a trocar into (C57L X A)F_1 hosts. At the end of four weeks, the transplants had grown to palpable size. The average transplant interval for the first 16 generations was 102 days. On April 14, 1954, the tumor was in its 19th transplant generation. Once the subcutaneous transplant had become palpable, this local tumor might regress, it might remain stationary in size, or it might continue to grow slowly. Regardless of the course of growth of the local subcutaneous transplant, Reticulum-cell Sarcoma 8469 almost invariably became disseminated. The liver was usually enlarged, and much of it was replaced by tumor tissue (fig. 83). Ascites was common. The ovaries and uterus were involved by tumor in about 50 percent of the female hosts. Neoplastic cells were occasionally found lodged in small vessels in the lungs and in the renal glomeruli. The lymph nodes and spleen were usually free of tumor. The peripheral blood and bone marrow of mice bearing the transplanted tumor were not involved by the neoplasm. (The foregoing description was kindly prepared for us by Dr. T. B. Dunn of the National Cancer Institute, Bethesda, Md.)

DESCRIPTION OF CURRENT TUMOR. A 2-month-old subcutaneous transplant tumor of the 19th generation of Reticulum-cell Sarcoma 8469 in a male (C57L X A)F_1 mouse measures 15 x 8 x 5 mm. The deep aspect of the tumor is adherent to the ribs and intercostal muscles, while the remainder of it is surrounded by a thin capsule. The tumor tissue is soft and friable and varies in color from yellow to deep orange to reddish brown. The peritoneal cavity contains about 2 cc. of serosanguineous fluid. The liver is greatly enlarged due to the presence of grayish tan tumor nodules which vary from 1.0 to 6.0 mm. in diameter. Minute, yellowish orange, rhomboid crystals are demonstrated in the fresh tumor tissue cleared with glycerine (fig. 84) and are similar to those described by Dunn in the original tumor. There is no gross or microscopic evidence of tumor in any other site.

Microscopically, the subcutaneous tumor is partially encapsulated by compressed connective tissue; other portions of it invade the adjacent tissues of the host. The central third of the tumor is necrotic, and in this area clumps of bright orange crystalline pigment are present. Scattered foci of necrosis are also present throughout the remainder of the tumor. Blood vessels are dilated and have thin walls, but they are not numerous. The blood vessels at

the periphery and deep within the tumor may contain deposits of tumor tissue. In the liver, the wall of several large intrahepatic branches of the portal vein is invaded by tumor tissue.

A striking feature of the tumor is its cellular pleomorphism, both in the subcutaneous transplant and in the neoplastic deposits in the liver (figs. 85–88). The cells vary from small round cells with little cytoplasm to giant tumor cells as large as a megakaryocyte that may be multinucleated or have a multilobed nucleus. Many of the cells are spindle shaped and arranged in bundles. Strands of spindle-shaped cells often enclose nodular areas composed chiefly of round cells and giant tumor cells (fig. 85). An angiomatous pattern, consisting of alternating cords of tumor cells and sinusoidal vessels, is sometimes observed (fig. 88). The majority of the giant cells are round, but others are stellate and may possess cytoplasmic processes; still others are elongated and straplike (figs. 86, 87). Some of the cells are vacuolated as though they were degenerative. The abundant cytoplasm is partly acidophilic and partly basophilic in its staining capacity. The acidophilic portion of the cytoplasm is purplish red in the periodic acid—Schiff reaction, and this color is not removed by diastase. Some cells contain a few periodic acid—Schiff-positive cytoplasmic granules that are removed by diastase, and are therefore presumably glycogen.

The nuclei are uniform in structure, although they vary in size, shape, and number. A heavily stained nuclear membrane encloses evenly distributed chromatin granules and from 1 to 6 nucleoli. The nucleoli have a sharply etched basophilic outline surrounding homogeneous pink-staining material. There are numerous mitotic figures which are bizarre in form. Almost every cell is enmeshed in a reticulum which is so dense in some instances that the nuclei of small tumor cells appear to be superimposed on reticular fibers (fig. 89). Bundles of collagenic fibers occur at random throughout the tumor, and intercellular extensions of them are frequently present.

No change in the histologic characteristics of Reticulum-cell Sarcoma 8469 has occurred during almost six years of transplantation. Of all the several other similar reticulum cell sarcomas that have been carried in transplantation at the National Cancer Institute, none, according to Dunn, has shown any change in morphologic characteristics during transplantation.

References

Cloudman, A. M. A transferable liver neoplasm (C198) arising in a female mouse of the leaden strain. Am. J. Cancer, 36:578–580, 1939.

Dunn, T. B. Hematoidin crystals in reticulum cell sarcoma of the mouse and in newborn human tissues. Mil. Surgeon, 109:350–359, 1951.

———. Normal and pathologic anatomy of the reticular tissue in laboratory mice, with a classification and discussion of neoplasms. J. Nat. Cancer Inst., 14:1281–1433, 1954.

Furth, J. A neoplasm of monocytes of mice and its relation to similar neoplasms of man. J. Exper. Med., 69:13–30, 1939.

RETICULUM-CELL SARCOMA 8469. MOUSE

(Tumor-bearing animal and histologic sections courtesy of Dr. T. B. Dunn, National Cancer Institute, Bethesda, Md.)

Figure 82.* Gross photograph of original tumor. There is neoplastic involvement of the uterus, ovaries, vagina, and liver. N. C. I. 00169; A. F. I. P. Acc. No. 219934–83.

Figure 83.* Gross photograph of transplant tumor. Note massive neoplastic replacement of the liver six months following subcutaneous inoculation of the tumor. X 1.5. N. C. I. A–3903; A. F. I. P. Acc. No. 219934–84.

Figure 84.** Photomicrograph of transplant tumor showing rhomboid shaped crystals of varying size and shape in the necrotic portions of the tumor. This is an unstained fresh preparation cleared in glycerine. X 650. N. C. I. 9496; A. F. I. P. Acc. No. 219934–85.

Figure 85.** Photomicrograph of transplant tumor. This shows pattern of growth in which strands of spindle-shaped cells surround and enclose nodular areas composed of round cells and giant tumor cells. Hematoxylin and eosin stain. X 110. N. C. I. 2539; A. F. I. P. Acc. No. 219934–86.

---

*From Dunn, T. B. Normal and pathologic anatomy of the reticular tissue in laboratory mice, with a classification and discussion of neoplasms. J. Nat. Cancer Inst., 14:1281–1433, 1954. Figures 47 and 48, plate 104, are our figures 82 and 83.

**From Dunn, T. B. Hematoidin crystals in reticulum cell sarcoma of the mouse and in newborn human tissues. Mil. Surgeon, 109:350–359, 1951. Our figure 84 is taken from figure 2; figure 8 is our figure 85.

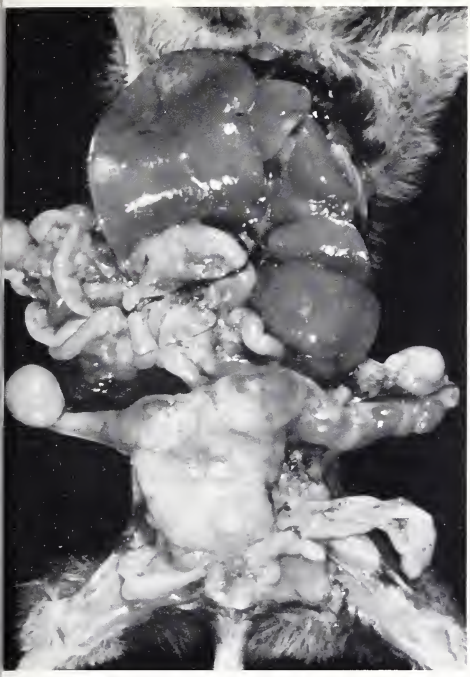

Fig. 82

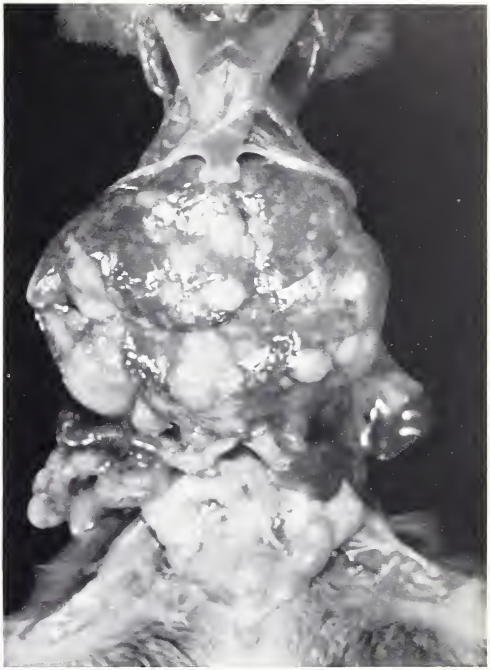

Fig. 83



Fig. 84

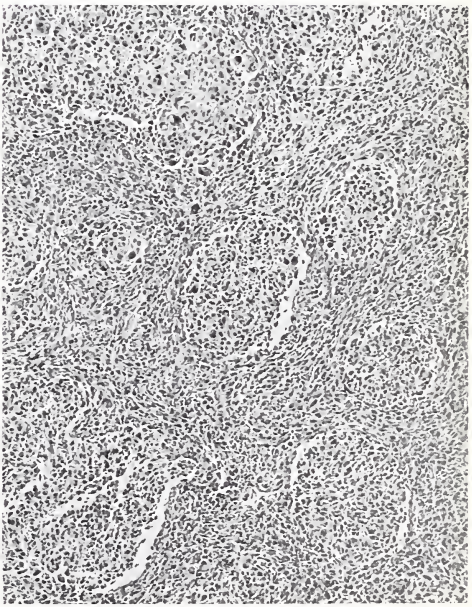

Fig. 85

RETICULUM-CELL SARCOMA 8469. MOUSE

Figure 86. Photomicrograph of transplant tumor. This area of the tumor shows cellular pleomorphism. Hematoxylin and eosin stain. X 565. N. C. I. 9050; A. F. I. P. Acc. No. 219934–87.

Figure 87. Photomicrograph of transplant tumor. This area of the tumor shows a type of giant cell which differs from that illustrated in figure 86. Hematoxylin and eosin stain. X 520. (This is taken from figure 6 in Dunn, T. B. Hematoidin crystals in reticulum cell sarcoma of the mouse and in newborn human tissues. Mil. Surgeon, 109:350–359, 1951.) N. C. I. 2529; A. F. I. P. Acc. No. 219934–88.

Figure 88. Section of liver from a mouse bearing the transplant tumor. Note cordlike pattern of neoplastic cells interspersed with sinusoidal vessels. Hematoxylin and eosin stain. X 210. (This is figure 54, plate 105, in Dunn, T. B. Normal and pathologic anatomy of the reticular tissue in laboratory mice, with a classification and discussion of neoplasms. J. Nat. Cancer Inst., 14:1281–1433, 1954.) N. C. I. 7041; A. F. I. P. Acc. No. 219934–89.

Figure 89. Photomicrograph of transplant tumor. The tumor is extensively permeated by reticular fibers which surround virtually every cell. Wilder's silver preparation. X 430. N. C. I. 9048; A. F. I. P. Acc. No. 219934–90.

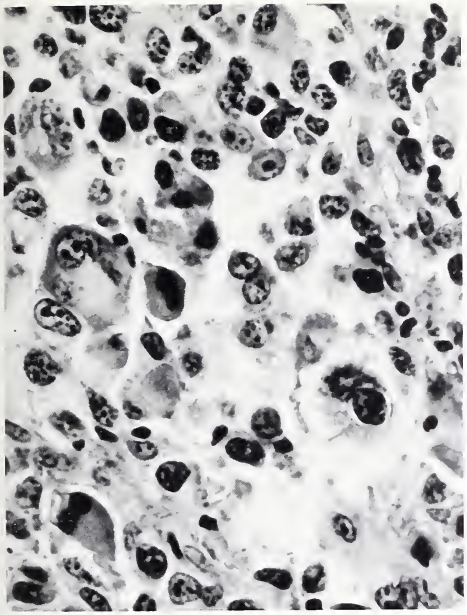

Fig. 86

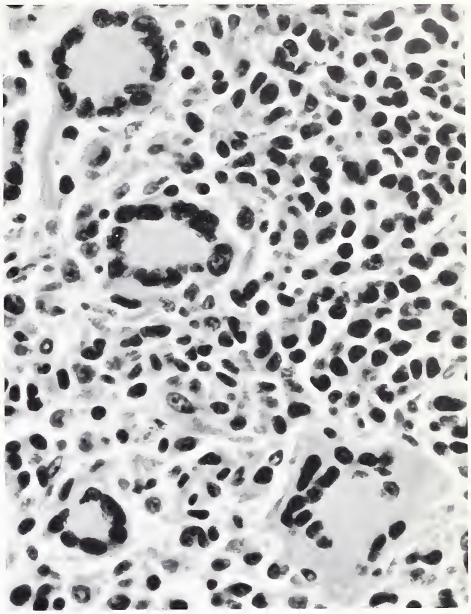

Fig. 87

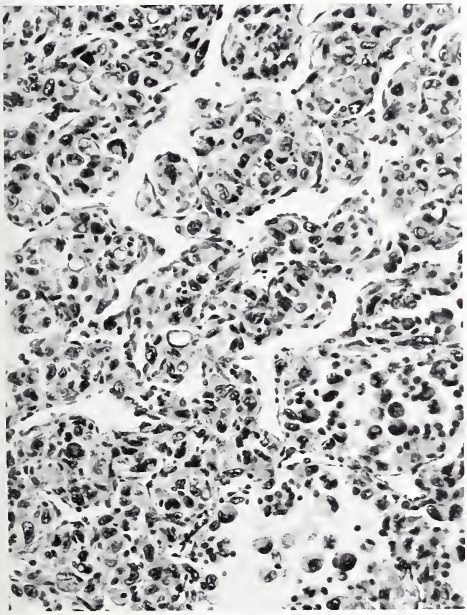

Fig. 88

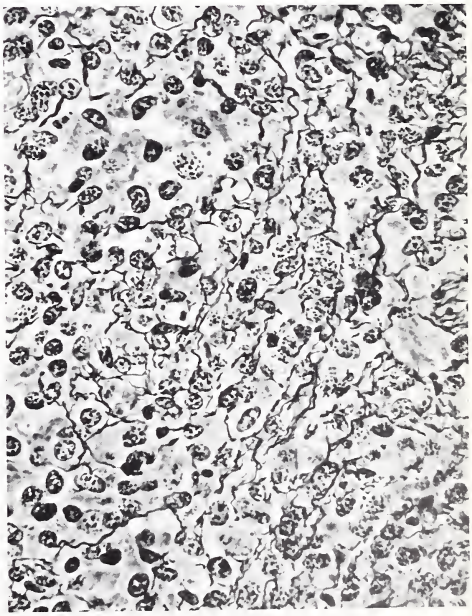

Fig. 89

———, and Furth, O. B. Monocytic leukemia and other neoplastic diseases occurring in mice following intrasplenic injection of 1:2-benzpyrene. Am. J. Cancer, 34:169–183, 1938.

Gorer, P. A. The pathology of malignant histiocytoma (reticulo-endothelioma) of the liver in mice. Cancer Research, 6:470–482, 1946.

Guérin, M. Tumeurs spontanées des animaux de laboratoire. Amédée Legrand & Cie, Editeurs, Paris, 1954.

Lewis, M. R. A transmissible monocytoma of the mouse. Am. J. Cancer, 36:34–43, 1939.

TUMORS OF THE LUNG

Pulmonary Adenocarcinoma C4461. Mouse

DEFINITION. An alveologenic carcinoma of the lung induced in a strain A mouse by the subcutaneous injection of 20-methylcholanthrene.

HISTORY AND DESCRIPTION OF ORIGINAL TUMOR. This tumor was induced in 1943 in a strain A male mouse by a single subcutaneous injection of 20-methylcholanthrene. The experiment was performed in the laboratory of W. E. Heston at the National Cancer Institute, Bethesda, Maryland. At necropsy, several tumors were found in each lung. One of the largest of these tumors was used for transplantation. It consisted of a pearly white, unencapsulated nodule, 1.0 cm. in greatest diameter, situated beneath the pleura. There were no metastases.

Microscopically, this tumor was a papillary acinar carcinoma (fig. 90). The epithelial-like cells of the growth were cuboidal or columnar and uniform in size, shape, and staining reaction. They contained round or oval nuclei and a large amount of basophilic granular cytoplasm. The sharply outlined nuclear membrane enclosed fine particles of chromatin, many of which were aligned against the nuclear membrane. Thus, the central area of the nucleus was clear, except for a solitary acidophilic nucleolus. One or two mitotic figures could be found in every high power field. The stroma was minimal in amount and consisted of mature connective tissue. A small capillary with a thin wall was often found in the papillary projections of tumor tissue. There was little necrosis or hemorrhage and no evidence of inflammatory reaction. The tumor invaded the adjacent parenchyma of the lung and extended into a bronchus.

TRANSPLANTATION STUDIES. Pieces of the tumor were transplanted under the skin of several A/He mice. From the outset, the tumor grew successfully without regression in 100 percent of mice of this strain. The subcutaneous transplant tumor is palpable seven days after inoculation, measures approximately 2 cm. in diameter at 21 days, and kills the host within six weeks. The tumor is generally transplanted at intervals of 14 to 21 days. The tumor was in its 161st transplant generation on October 25, 1954. Pulmonary Adenocarcinoma C4461 has retained the histologic pattern of the original tumor for more than 100 transplant generations. This is in contrast to other pulmonary alveologenic tumors which, upon repeated transplantation, have generally undergone transition to sarcoma. (Many of these data were obtained in personal interview with Dr. W. E. Heston of the National Cancer Institute, Bethesda, Md.)

PULMONARY ADENOCARCINOMA C4461. MOUSE

(Histologic sections and tumor-bearing animal courtesy of Dr. W. E. Heston, National Cancer Institute, Bethesda, Md.)

Figure 90. Photomicrograph of original tumor showing the papillary acinar pattern. Hematoxylin and eosin stain. X 245. N. C. I. 8202; A. F. I. P. Acc. No. 219934–91.

Figure 91. Photomicrograph of 134th generation transplant tumor. The subcutaneous transplant tumor is encapsulated and divided into compartments by thick connective tissue septa. There are areas of necrosis and cystic spaces. Hematoxylin and eosin stain. X 7. N. C. I. 8224; A. F. I. P. Acc. No. 219934–92.

Figure 92. Photomicrograph of 134th generation transplant tumor. The margin of the subcutaneous transplant shows a portion of the capsule containing inflammatory cells and skeletal muscle fibers. The tumor in this area has a papillary glandular appearance. Note the accumulation of edema fluid within the scanty stroma of some of the papillary projections. Hematoxylin and eosin stain. X 66. N. C. I. 8704; A. F. I. P. Acc. No. 219934–93.

Figure 93. Photomicrograph of 134th generation transplant tumor. A solid area of the tumor showing the characteristics of the neoplastic cells. Hematoxylin and eosin stain. X 450. N. C. I. 8200; A. F. I. P. Acc. No. 219934–94.

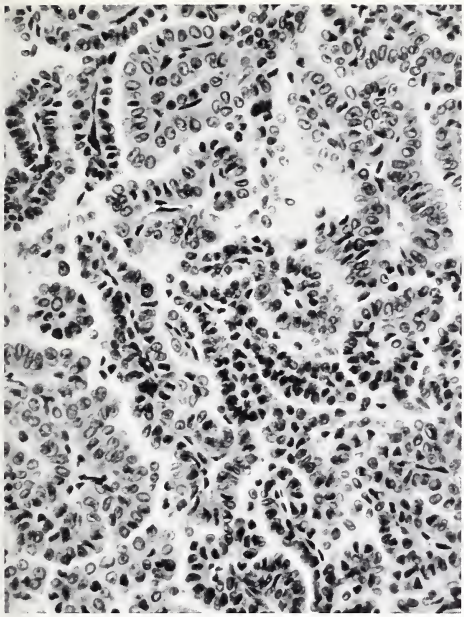

Fig. 90

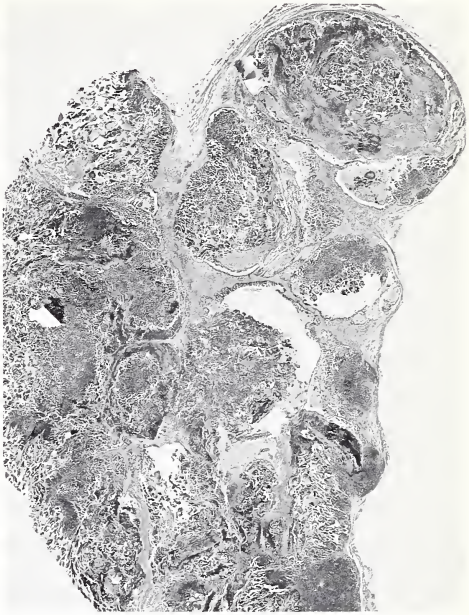

Fig. 91

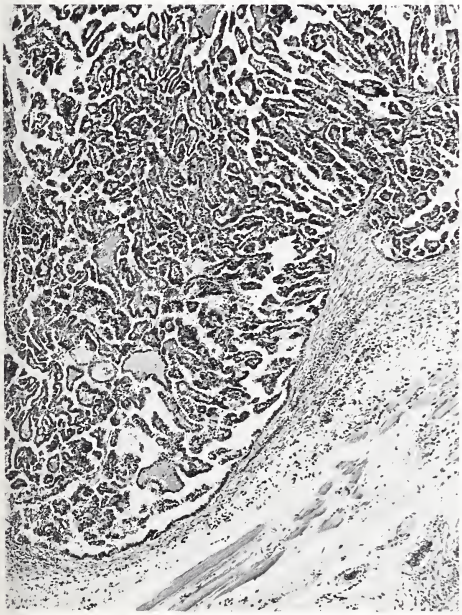

Fig. 92

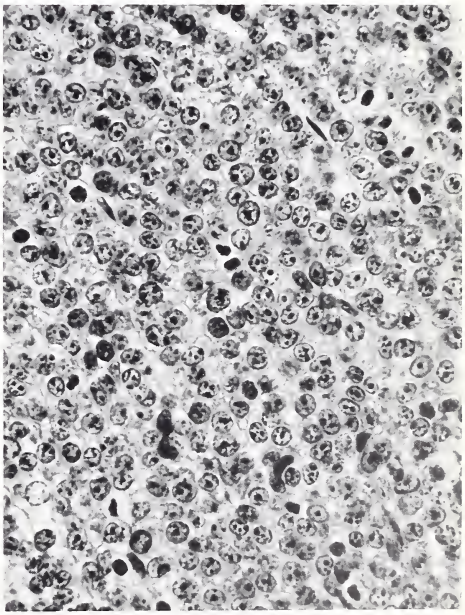

Fig. 93

DESCRIPTION OF CURRENT TUMOR. A subcutaneous transplant of the 134th generation of Pulmonary Adenocarcinoma C4461 measures 1.5 cm. in diameter 21 days after inoculation. It is surrounded by a capsule of connective tissue that is easily separated by blunt dissection from the adjacent tissue of the host. On section, the viable portions of the tumor are grayish pink and papillary; the necrotic areas are grayish yellow.

Microscopically, the tumor is divided into large nodular compartments by septa of connective tissue that are continuous with the capsule (fig. 91). About one third, and often as much as one half, of each large nodule is necrotic. The histologic pattern is chiefly that of papillary acini, but there are also cystic spaces and solid areas of tumor cells (fig. 92). Each papillary projection is thin, branched, and frondlike with a few centrally located reticular and collagenic fibers surrounding a small capillary-like vessel. The neoplastic cells are cuboidal, sharply outlined, and uniform in appearance. The nuclei are round and contain fine granules of chromatin and 1 to 4 basophilic nucleoli (fig. 93). Usually one mitotic figure may be found in each oil immersion field. The cytoplasm is slightly basophilic, granular, and occasionally vacuolated. The central stromal cores of some terminal papillary projections show pronounced swelling. This is due apparently to the accumulation of deeply eosinophilic, homogeneous, edema fluid in which there are vacuoles, small amounts of fibrin, and a few erythrocytes.

The tumor cells contain fine granular material that is colored purplish red in the periodic acid—Schiff reaction. Much of this material is removed by diastase. The edema fluid in the connective tissue of the stroma of many of the papillary processes is purplish red and somewhat fibrillar in periodic acid—Schiff preparations. Between the papillary projections and within the acini, there is sometimes a small amount of granular or homogeneous material that is periodic acid—Schiff-positive. Around the periphery of the tumor, the capsule varies considerably in thickness and is sometimes invaded by neoplastic cells. The connective tissue of the capsule and the septa of the tumor contain varying numbers of inflammatory cells, hyperemic capillaries, lymph vessels, and skeletal muscle fibers.

The term alveologenic carcinoma was coined by one of us (H. L. S.) to designate a tumor that arises from cells of the alveoli, in contrast to bronchogenic carcinoma that arises from cells of the bronchi.

References

Andervont, H. B. Pulmonary tumors in mice. III. The serial transmission of induced lung tumors. Pub. Health Rep., 52:347–355, 1937.

Stewart, H. L. Pulmonary tumors in mice. In: Homburger, F., and Fishman, W. H. (eds.). The Physiopathology of Cancer, pp. 93–112. New York: Paul B. Hoeber, Inc., 1953.

_____, Grady, H. G., and Andervont, H. B. Development of sarcoma at site of serial transplantation of pulmonary tumors in inbred mice. J. Nat. Cancer Inst., 7:207–225, 1947.

TUMORS OF THE ALIMENTARY TRACT

TUMORS OF THE SALIVARY GLANDS

Myoepithelioma HD. Mouse

SYNONYM: Myoepithelioma HE12679.

DEFINITION. A myoepithelioma that arose spontaneously in the parotid gland of a strain A mouse.

HISTORY AND DESCRIPTION OF ORIGINAL TUMOR. Myoepithelioma HD was found in the right salivary gland region of a 12-month-old untreated strain A/HeN female mouse December 17, 1953, in the laboratory of W. E. Heston at the National Cancer Institute, Bethesda, Maryland. Similar tumors have been found in mice of strain BALB/c. The tumor was encapsulated, firm, nodular, and measured 0.75 cm. in diameter. The cut surface showed an outer shell of solid white tissue surrounding a central cystic cavity filled with a slimy, creamy white, mucoid substance.

Microscopically, the tumor was surrounded by a capsule of edematous connective tissue containing dilated blood vessels and many inflammatory cells. The capsule was penetrated by tumor in a few areas. Remnants of the parotid gland were present adjacent to the tumor (fig. 94). The pattern was that of sheets and cords of cells, indistinctly separated into small alveoli by bands of connective tissue containing slitlike blood vessels (fig. 95). The alveoli were surrounded by collagenic and reticular fibers. There was some tendency for the reticulum to penetrate within the sheets and cords of cells (fig. 96). Necrotic areas were large and numerous and frequently contained finely granular and vacuolated histiocytes.

The cells composing the tumor were pleomorphic—elongated, spindle shaped, oval, or round. The round cells were most numerous adjacent to the connective tissue stroma. The cytoplasm was sometimes vacuolated and more eosinophilic in the fusiform than in the round cells. The nuclei varied from 10 to 30 microns in diameter. They had a sharply etched nuclear membrance enclosing a rather loose linin network, very fine granules of chromatin, and 1 to 5 nucleoli. There was an average of one mitotic figure in each high power field. Myoglia and fibroglia were found to be associated with the fusiform cells when sections were stained with phosphotungstic acid—hematoxylin. These fibrillar elements may possibly have originated from the basket cells of the parotid gland. Many large round vacuolated cells were scattered throughout the tumor but were most numerous near the collagenous stroma. They measured as much as 50 microns in diameter. These cells

almost invariably contained Russell bodies but no glycogen. The nucleus was generally centrally located and not compressed, even though the cytoplasm was extensively vacuolated and contained numerous Russell bodies.

A few epithelial pearls were identified (fig. 97). The center of these pearls contained degenerated and necrotic cells, granular periodic acid—Schiff-positive material, and a hyaline substance resembling keratin. The cytoplasm of some of the cells composing the pearls contained fine rodlike fibrils that stained deep blue with phosphotungstic acid—hematoxylin. They resembled tonofibrils. A pseudoglandular pattern suggesting acinar structures was also present in some areas. This pseudoglandular pattern may have resulted from central degeneration of solid nests of cells.

TRANSPLANTATION STUDIES. Pieces of Myoepithelioma HD were inoculated subcutaneously into five male mice of the A/HeN strain. Twenty-seven days later the transplanted tumors averaged 10 mm. in diameter. In June 1954, the tumor was in its 6th transplant generation and had grown successfully without regression in 90 percent of the hosts. Occasionally, metastasis occurred to the lungs and axillary lymph nodes. Animals bearing transplants of Myoepithelioma HD regularly developed a pronounced leukemoid reaction. Large tumors over 60 days of age were frequently ulcerated. Animals bearing such tumors were usually emaciated and anemic. (The foregoing description was kindly prepared for us by Dr. T. B. Dunn of the National Cancer Institute, Bethesda, Md.)

DESCRIPTION OF CURRENT TUMOR. A 7-week-old encapsulated subcutaneous transplant tumor measures 35 x 20 x 10 mm. It is composed of confluent small nodules of grayish white tissue. The central third of the tumor is filled with thick, creamy-white, mucoid fluid. This same type of mucoid material also exudes from the cut surface of the more solid portion of the tumor and from an enlarged axillary lymph node containing a metastatic deposit.

The histologic pattern of the transplanted tumor is remarkably similar to the original, and no radical alteration in morphology is observed (fig. 98). The capsule consists of a thin layer of fibrous tissue containing collagenic fibers. It contains a few dilated blood vessels and a small number of inflammatory cells and is penetrated in a few places by tumor cells. Approximately 70 percent of the tumor is necrotic, and the necrotic areas are located both centrally and peripherally. Blood vessels are contained within the collagenous stroma and appear as thin slits lined with endothelium. The cells of the transplant are similar to those of the original tumor (fig. 99). A few epithelial pearls, often with necrotic centers, are scattered throughout the tumor. The mucicarmine method reveals red fibrillar mucin in many necrotic foci and in the coarse connective tissue septa, particularly surrounding the blood vessels (fig. 100). Small amounts of red mucoid material in the form of droplets are occasionally seen in the cytoplasm of the neoplastic cells. Fibroglial (fig. 101) and myoglial fibrils (fig. 102) can be identified by the use of the phosphotungstic

acid—hematoxylin stain. The collagenic and reticular fibrils are relatively abundant, but the pattern is that of a carcinoma (fig. 103). The metastatic growth in the axillary lymph node (fig. 104) is similar in histologic pattern to the subcutaneous transplant.

References

Andervont, H. B., and Dunn, T. B. Attempt to detect a mammary tumor-agent in strain C mice by x-radiation. J. Nat. Cancer Inst., 10:1157–1189, 1950.

Bateman, J. C., Leukemoid reactions to transplanted mouse tumors. J. Nat. Cancer Inst., 11:671–687, 1951.

Lippincott, S. W., Edwards, J. E., Grady, H. G., and Stewart, H. L. A review of some spontaneous neoplasms in mice. J. Nat. Cancer Inst., 3:199–210, 1942.

Parotid Gland Tumor L7205. Mouse

DEFINITION. A mixed tumor induced in the parotid gland of a newborn ($C3H_f$ x C3H/Fg)F_1 female mouse by the subcutaneous injection of a centrifugate of lymphomatous tissue from a C3H/Fg mouse.

HISTORY AND DESCRIPTION OF ORIGINAL TUMOR. Parotid Gland Tumor L7205 arose in a 10-month-old female ($C3H_f$ x C3H/Fg)F_1 mouse which, when less than 24 hours old, was inoculated with a centrifugate of neoplastic tissue from another mouse. The experiment was performed in the laboratory of L. W. Law at the National Cancer Institute in Bethesda, Maryland. The mother of the mouse that received the inoculation was a strain $C3H_f$ mouse of a line obtained from W. E. Heston and inbred for 15 generations by Law. The father was a C3H strain mouse of a subline (C3H/Fg) inbred by Frank Figge, of the University of Maryland Medical School in Baltimore. The C3H/Fg mice have a higher incidence of spontaneous leukemia than do mice of other C3H sublines. The centrifugate used for inoculation was prepared by diluting one part of the homogenized spleen, liver, and lymph nodes from a C3H/Fg mouse with four parts of Locke's solution. The donor mouse had a Hodgkin's-like lesion designated by T. B. Dunn as Type B Reticulum-cell Neoplasm. The homogenate was spun three times for 15 minute periods; twice at 3,000 r. p. m. and once at 9,500 r. p. m. in an international PR2 centrifuge. One tenth of a cubic centimeter of the homogenate was injected subcutaneously into each of six newborn littermate mice.

Five of the mice developed parotid gland tumors that were essentially similar in appearance. At the age of eight months, the mouse in which Tumor L7205 arose developed a swelling of the right cervical region. This swelling slowly increased in size for the next two months. The animal was killed and necropsied on November 12, 1954. Tumors were found to be present in both parotid glands. The mass on the right consisted of discrete and conglomerate, sharply outlined, encapsulated nodules varying from 1 to 8 mm. in diameter. The largest of these was composed of soft, grayish white tissue which, on section, exuded a turbid serous fluid. The others were firm, opaque, and

MYOEPITHELIOMA HD. MOUSE

(Histologic sections and tumor-bearing animal courtesy of Dr. T. B. Dunn, National Cancer Institute, Bethesda, Md.)

Figure 94. A low power photomicrograph of original tumor showing the tumor, a portion of the parotid gland, and a cervical lymph node. Hematoxylin and eosin stain. X 75. N. C. I. 8968; A. F. I. P. Acc. No. 219934–95.

Figure 95. Photomicrograph of original tumor. The pattern is that of sheets and cords of cells separated into small alveoli by pale, mucoid connective tissue. Hematoxylin and eosin stain. X 200. N. C. I. 9086; A. F. I. P. Acc. No. 219934–96.

Figure 96. Photomicrograph of original tumor. The tumor is divided into small alevoli by reticular fibers. There is some tendency for the reticular fibers to penetrate within these alveoli. Wilder's silver preparation. X 450. N. C. I. 9070; A. F. I. P. Acc. No. 219934–97.

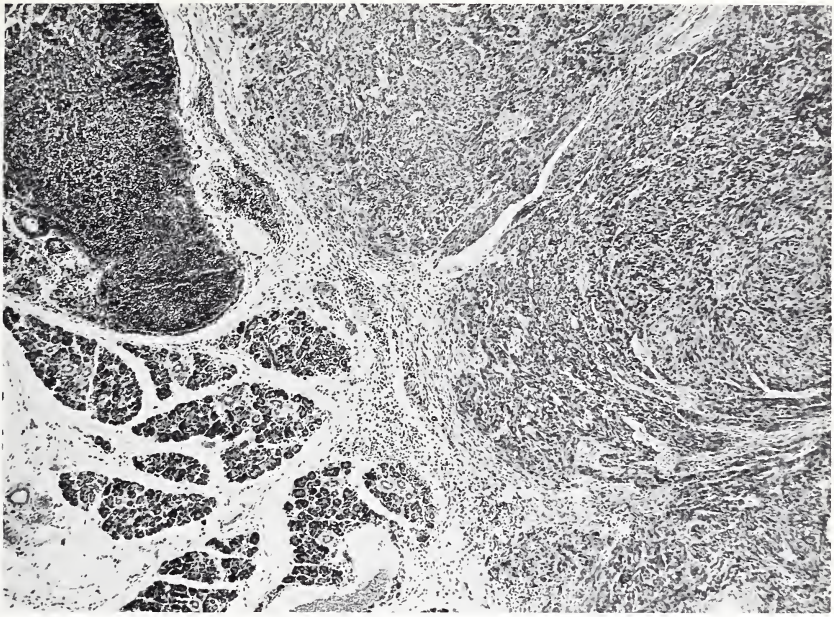

Fig. 94

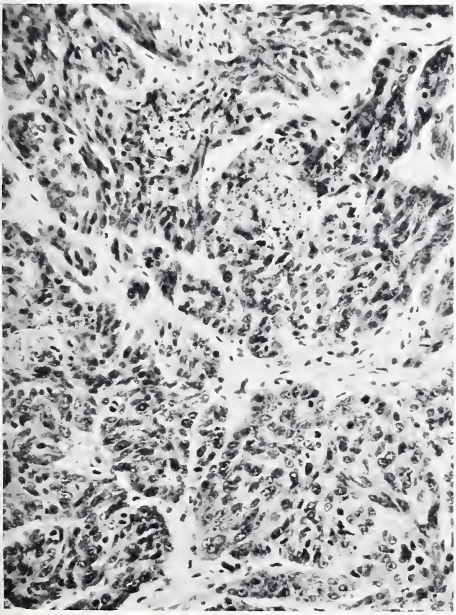

Fig. 95

Fig. 96

MYOEPITHELIOMA HD. MOUSE

Figure 97. Photomicrograph of original tumor. Two epithelial pearls and small spaces suggesting pseudoglandular formation are present. A necrotic area may be seen in the lower right corner of the illustration. Hematoxylin and eosin stain. X 380. N. C. I. 8956; A. F. I. P. Acc. No. 219934–98.

Figure 98. Photomicrograph of transplant tumor. The histologic pattern is similar to that of the primary tumor. The large necrotic area contains mucin. Hematoxylin and eosin stain. X 60. N. C. I. 8970; A. F. I. P. Acc. No. 219934–99.

Figure 99. High power photomicrograph of transplant tumor showing the appearance of the tumor cells. Hematoxylin and eosin stain. X 660. N. C. I. 9066; A. F. I. P. Acc. No. 219934–100.

Figure 100. Photomicrograph of transplant tumor. This is an area in which the connective tissue stroma has a high content of mucin. Hematoxylin and eosin stain. X 200. N. C. I. 8960; A. F. I. P. Acc. No. 219934–101.

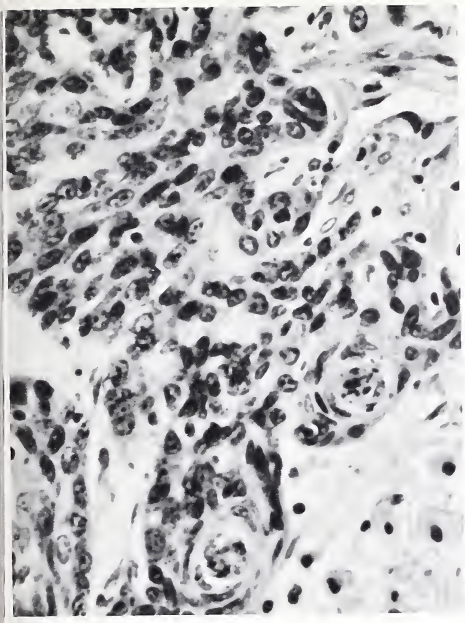

Fig. 97

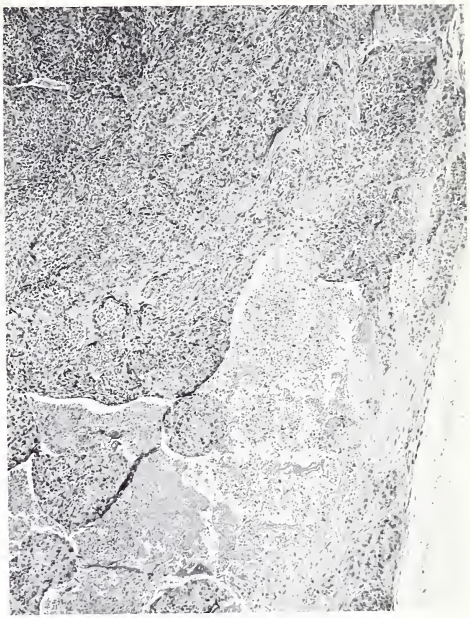

Fig. 98

Fig. 99

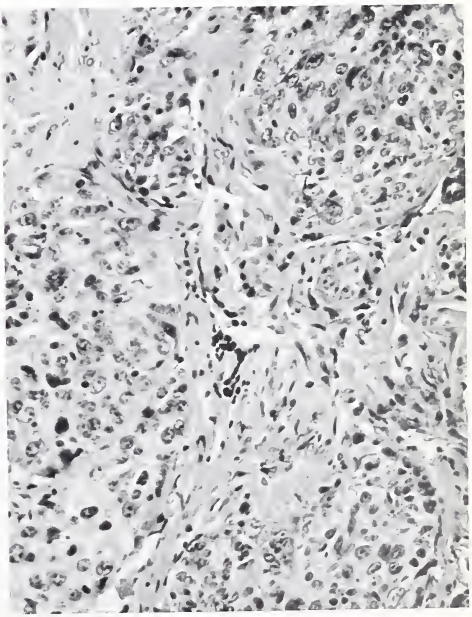

Fig. 100

MYOEPITHELIOMA HD. MOUSE

Figure 101. Photomicrograph of transplant tumor. An area of the tumor which shows fibroglial fibers. Phosphotungstic acid—hematoxylin stain. X 700. N. C. I. 9069; A. F. I. P. Acc. No. 219934–102.

Figure 102. Photomicrograph of transplant tumor. An area of the tumor showing myoglial fibers. Phosphotungstic acid—hematoxylin stain. X 700. N. C. I. 9068; A. F. I. P. Acc. No. 219934–103.

Figure 103. Photomicrograph of transplant tumor. The reticular fibers are relatively abundant, and the pattern is that of a carcinoma. Wilder's silver preparation. X 280. N. C. I. 8962; A. F. I. P. Acc. No. 219934–104.

Figure 104. Section of an axillary lymph node largely replaced by metastatic tumor. The margin of a necrotic cystic area is present in the lower right corner of the illustration. Hematoxylin and eosin stain. X 50. N. C. I. 8967; A. F. I. P. Acc. No. 219934–105.

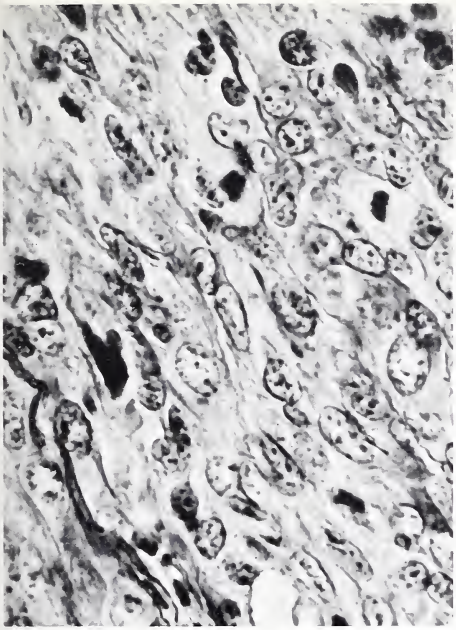

Fig. 101

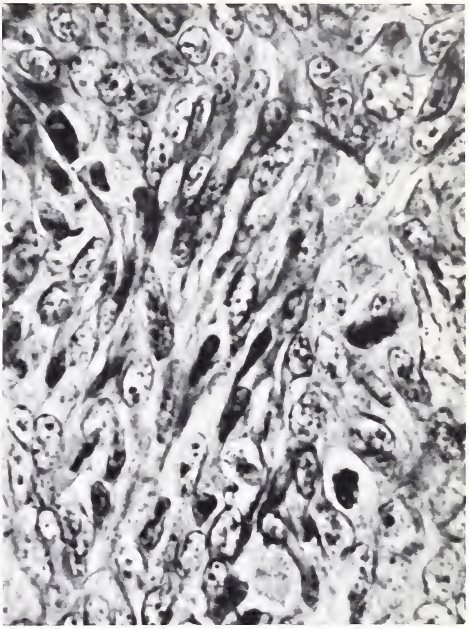

Fig. 102

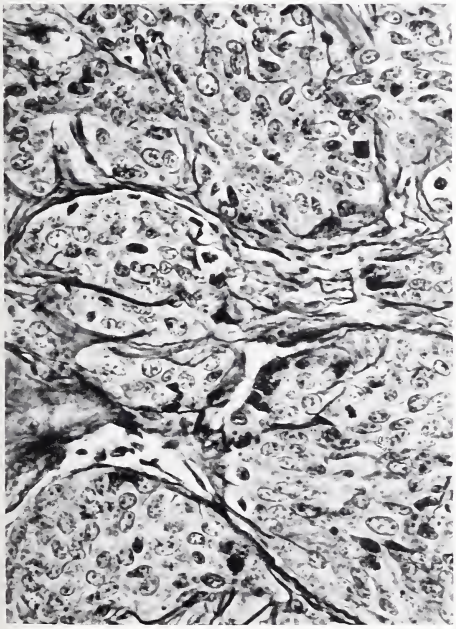

Fig. 103

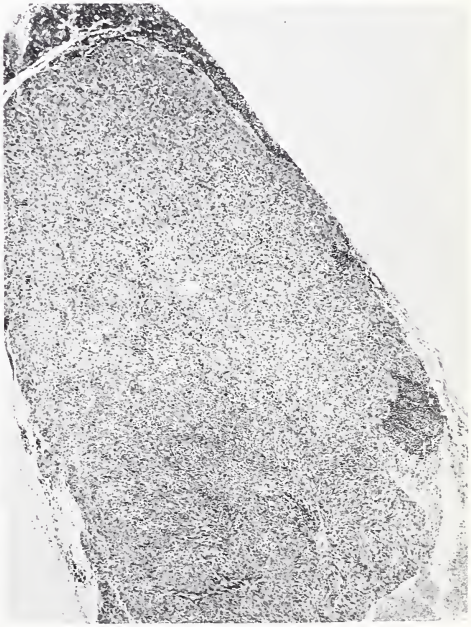

Fig. 104

pearly white. A few small similar tumor nodules measuring 1 to 3 mm. in diameter were present in the left parotid gland. The only other abnormality found at necropsy was a small mammary gland tumor.

Histologic sections of the tumors in the right (fig. 105) and left (fig. 106) parotid glands were kindly made available to us by T. B. Dunn. The pattern of the tumor varies in different nodules and in different areas of the same nodule (figs. 107–110). One pattern, found chiefly in the largest nodule in the right parotid gland, has a mesenchymal appearance (fig. 107). The loosely arranged cells have oval nuclei and delicately branched cytoplasmic processes. A few of them contain periodic acid—Schiff-positive cytoplasmic granules that are not removed by diastase. One mitotic figure, often abnormal in form, is observed in every oil immersion field. The fibrillary processes, which are colored purplish red in periodic acid—Schiff preparations, frequently anastomose so that the cells of the tumor seem to form a syncytium. Between and within the cells are spaces that contain a clear uncolored material as seen in the hematoxylin—eosin, periodic acid—Schiff, van Gieson, and toluidine blue preparations. In some areas the tumor cells are elongated and spindle shaped and are arranged in interlacing bundles suggesting the pattern of fibrosarcoma. Reticular fibrils are short, fine, and few in number; collagenic fibers are coarser and more numerous. Both are increased in the sarcomatous areas. There are only a few blood vessels, and although some of them may be sinusoidal, the majority are of capillary size. The cystic spaces are bordered by necrotic eosinophilic material. Among the mesenchymal cells are here and there single large round or oval cells that resemble oncocytes. These cells have no processes, and the cytoplasm is colored deep red with the hematoxylin and eosin stain and purplish red in the periodic acid—Schiff reaction. These cells are occasionally observed in mitosis.

A second histologic pattern, found chiefly in the smaller nodules of L7205, consists of glandlike structures intermingled with mesenchyme-like cells (fig. 108). The growth in such a nodule appears to be expansile, but the capsule may also be invaded by tumor tissue. The glands, small in the center but distended and often ruptured at the periphery, contain periodic acid—Schiff-positive material. Adjacent to the lumen, the cells often contain a single intracytoplasmic dot that is blackened by silver, and when such cells are closely approximated, the dots appear to merge, forming a continuous black line. This portion of the cytoplasm is not colored in the periodic acid—Schiff preparations, although the lumens of corresponding glands may contain purplish red material.

A third pattern (fig. 109) also found in the small tumor nodules consists of ductlike structures lined by low cuboidal cells and embedded in an eosinophilic hyaline matrix which is colored purplish red in the periodic acid—Schiff reaction, faint to bright pink with van Gieson's stain, green with the trichrome stain, blue with Mallory's aniline blue, and brown with Wilder's

silver. Within the hyaline matrix are found a few spindle-shaped and stellate cells that may be fibroblasts or distorted mesenchymal cells, and a few reticular fibers, collagenic fibers, and capillary-sized blood vessels. One of the small nodules contains a sharply outlined round cyst bordered by flattened squamous cells (fig. 110).

TRANSPLANTATION STUDIES. Pieces of Parotid Gland Tumor L7205 (right parotid gland) were inoculated subcutaneously into three ($C3H_f$ x C3H/Fg)F_1 mice. Four months after inoculation a tumor became palpable at the site of inoculation in one of these mice, and the animal was killed the following month. Histologically, the 1st generation transplant tumor consists chiefly of sheets of mesenchymal cells interspersed in some areas with tubule-like structures lined with epithelial cells (figs. 111, 112). A mouse bearing the 2nd generation transplant tumor and necropsied on September 23, 1955, had a nodular grayish white tumor 1.5 cm. in diameter in the right axilla. The center of the tumor was filled with thick, clear, amber colored fluid. The histologic pattern is chiefly mesenchymal in appearance with a few small glandular structures, the lining cells of which blend with their supporting stellate cells (fig. 113). The tumor is divided into lobules by coarse bands of fibrous connective tissue which are continuous with a capsule that is penetrated by tumor tissue at several points. There are numerous large thin-walled blood vessels and often a striking peritheliomatous arrangement of the tumor cells. Several areas of necrosis are present. The few reticular and collagenic fibers are found chiefly around blood vessels and in the connective tissue septa. The fibrillar processes of the stellate cells which form an anastomosing network stain faintly bluish with phosphotungstic acid—hematoxylin and resemble fibroglia. Among the stellate cells are many oval and round cells with deeply acidophilic cytoplasm like those noted in the original tumor. Many more mitotic figures are found both in the acidophilic cells and in the stellate cells in the 2nd generation transplant than in the original tumor.

COMMENT. Gross and Stewart, working independently, induced tumors of the parotid glands of strain C3H mice by inoculating them with cell-free extracts of organs or of neoplastic tissue of mice of the same or of different strains. This discovery was confirmed and extended by the studies of Law and associates of the National Cancer Institute, who kindly made their records and histologic sections of Parotid Gland Tumor L7205 available to us. The extracts used for inoculation have consisted of filtrates or centrifugates of leukemic tissues of the high leukemia AKR, C58, and C3H/Fg strains, cell-free extracts of embryonic tissue of AKR mice, and tissues of adult C3H mice with and without lymphoma. A critical condition for inducing parotid gland tumors of this type is the age at which the mice are inoculated. Mice less than 24 hours old when inoculated yield an over-all incidence of 10 percent of parotid gland tumor.

PAROTID GLAND TUMOR L7205. MOUSE

(Histologic sections courtesy of Dr. T. B. Dunn, National Cancer Institute, Bethesda, Md.)

Figure 105. Section of right parotid gland area of the original tumor-bearing mouse. Three tumor nodules are present. The largest is on the left; it is composed of mesenchymal type tissue and contains a cyst lined with and containing necrotic material. The tumor nodule at the lower right contains many epithelial tubules separated by mesenchymal tissue. The tumor nodule at the upper right contains small duct structures supported by pale stroma that in places has a hyaline appearance. A small cyst is also present. Parotid glandular tissue is present to the right of and below the center. Above the center there is fibrofatty tissue and a lymph node. Hematoxylin and eosin stain. X 23. N. C. I. 9751B; A. F. I. P. Acc. No. 219934–106.

Figure 106. Section of left parotid gland area of the original tumor-bearing mouse. Two tumor nodules are present, both of which are composed chiefly of ductlike structures. A hyaline substance separates the ductlike structures in most of the smaller and in a portion of the larger tumor nodule. The larger nodule is surrounded by a cuff of lymphocytes. Below it on the right and on the left are portions of parotid gland. In the lower portion of the illustration are fibrofatty and muscular tissue and a few mammary gland ducts. Hematoxylin and eosin stain. X 32. N. C. I. 9752A; A. F. I. P. Acc. No. 219934–107.

Figure 107. Section of a large tumor nodule in right parotid gland of original tumor-bearing mouse showing mesenchymal type tissue. Hematoxylin and eosin stain. X 290. N. C. I. 9760; A. F. I. P. Acc. No. 219934–108.

Fig. 105

Fig. 106

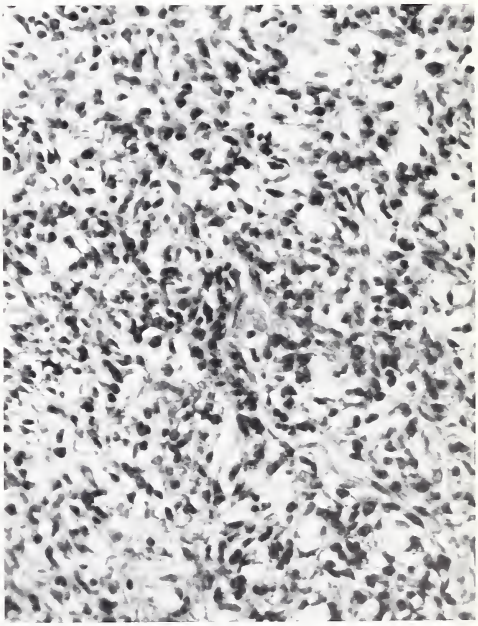

Fig. 107

PAROTID GLAND TUMOR L7205. MOUSE

Figure 108. Section of a small tumor nodule in right parotid gland of original tumor-bearing mouse showing epithelial tubular structures separated by mesenchymal type tissue. Hematoxylin and eosin stain. X 290. N. C. I. 9761; A. F. I. P. Acc. No. 219934–109.

Figure 109. Section of a tumor nodule in left parotid gland of original tumor-bearing mouse. Ductlike epithelial structures separated by hyalin. Hematoxylin and eosin stain. X 290. N. C. I. 9757; A. F. I. P. Acc. No. 219934–110.

Figure 110. Section of a small tumor nodule in right parotid gland of original tumor-bearing mouse showing wall of cyst lined with flattened squamous cells. Hematoxylin and eosin stain. X 290. N. C. I. 9762; A. F. I. P. Acc. No. 219934–111.

Figure 111. Photomicrograph of 1st generation transplant tumor. The tumor has a nodular appearance, and the nodules are separated by coarse bundles of connective tissue. There are multiple cystic areas. Hematoxylin and eosin stain. X 22. N. C. I. 9753; A. F. I. P. Acc. No. 219934–112.

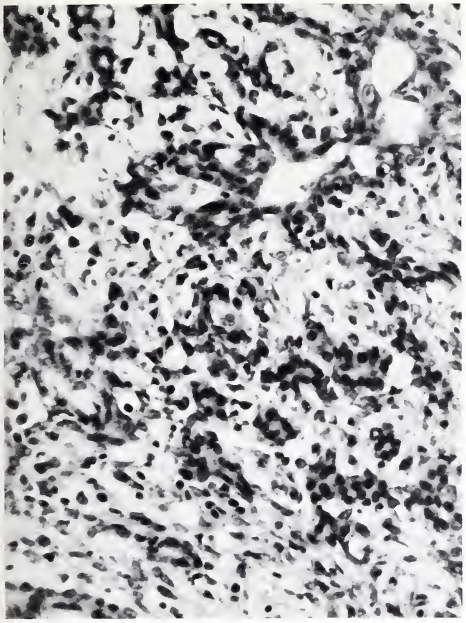

Fig. 108

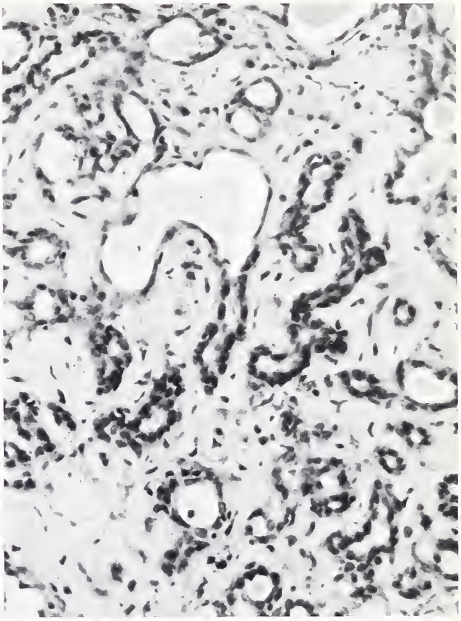

Fig. 109

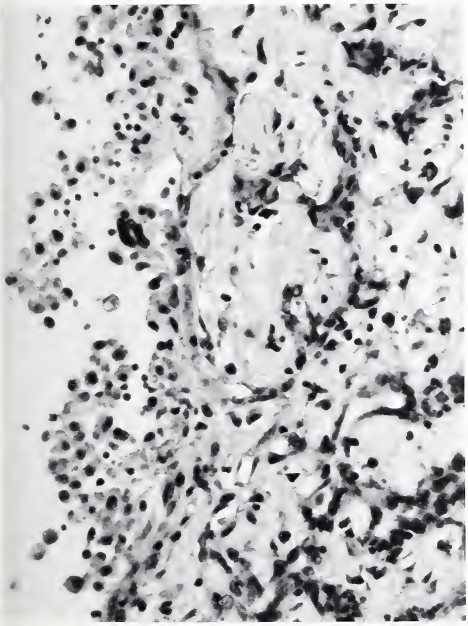

Fig. 110

Fig. 111

PAROTID GLAND TUMOR L7205. MOUSE

Figure 112. Photomicrograph of 1st generation transplant tumor. An area of the tumor shown in figure 111. On the right, the cells are loosely arranged in a delicate fibrillar matrix in which there are many empty spaces. To the left of center and adjacent to the blood vessels, the tumor cells are more densely packed, and there is a suggestion of palisading. Hematoxylin and eosin stain. X 290. N. C. I. 9756; A. F. I. P. Acc. No. 219934–113.

Figure 113. Photomicrograph of 2nd generation transplant tumor showing an area composed of mesenchymal tissue and glandular structures that contain secretory material. Van Gieson stain. X 290. N. C. I. 9772; A. F. I. P. Acc. No. 219934–114.

Figure 114. Gross photograph of bilateral parotid gland tumors in a strain C3H female mouse five months of age. Shortly after birth the mouse received an injection of a filtrate of leukemic tissue from an AKR mouse. There are multiple nodules of different sizes in both parotid glands. The larger nodules are soft and grayish white and may contain small cysts. The smaller nodules are pearly white and firm. X 4. N. C. I. 9764; A. F. I. P. Acc. No. 219934–115.

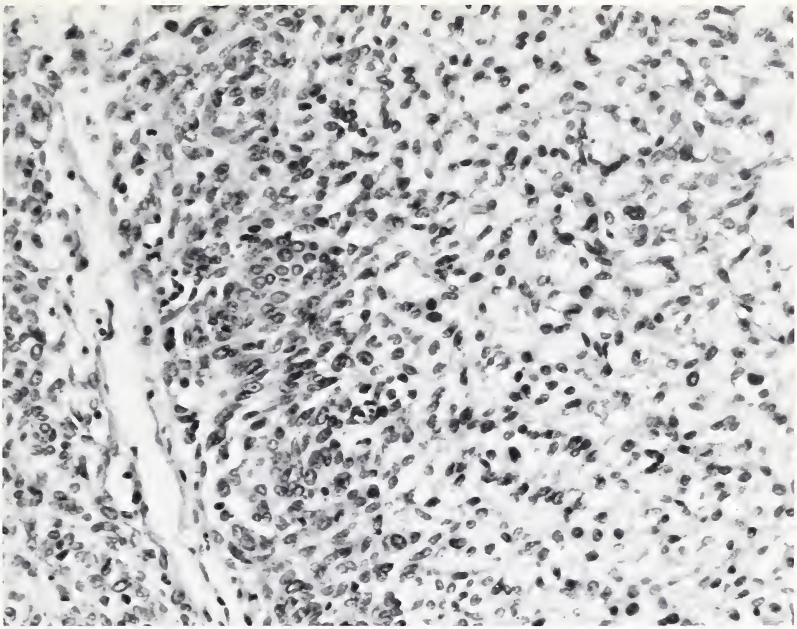

Fig. 112

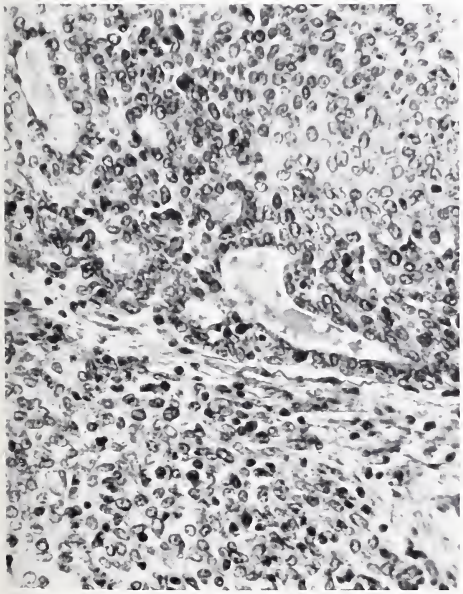

Fig. 113

Fig. 114

The induced parotid gland tumors like L7205 differ from the spontaneous myoepithelioma in several respects. Although both tumors arise in the parotid gland, the induced tumors are often bilateral (fig. 114), whereas the spontaneous tumor is always unilateral. The myoepithelioma, although not common, has been found repeatedly in mice of strains BALB/c and A but not of strain C3H in which the induced tumors arise. Although both types of tumor may become cystic, the contents of the cysts have physical differences which are characteristic for each neoplasm. The cysts of the induced parotid gland tumors contain serous material, in contrast to the thick, viscid, mucoid contents of the cysts of the myoepithelioma. In time, the cystic areas of the myoepithelioma may become so large that only a thin shell of viable tumor tissue remains. The spontaneous and induced tumors also differ in histologic structure. The spontaneous tumor consists of sheets of spindle-shaped cells, with here and there pearl formation and focal keratinization. Both fibroglia and myoglia are demonstrable in association with the spindle-shaped cells of the myoepithelioma, whereas only fibroglia has been found in the induced tumors. The several histologic patterns of the induced tumors resemble more closely those found in some mixed tumors of the salivary gland in man than they do those of the myoepithelioma. The intermingling of small glandlike structures with mesenchymal elements is especially characteristic of the induced parotid gland tumors. Such a pattern is not duplicated in the spontaneous myoepithelioma, and indeed is seen in only a few other tumors of the mouse—in the teratoma or in unusual tumors of the mammary gland.

Mice bearing transplanted myoepitheliomas regularly develop a leukemoid reaction. Several transplant lines of the induced parotid gland tumor have been studied, but we have heard of only one which is associated with a leukemoid reaction in the host. Mice bearing this transplant tumor line are said to develop hypervolemia also. The spontaneous myoepithelioma maintains the histologic pattern of the original tumor through many transplant generations. On the other hand, the induced parotid gland tumors, while they may reproduce the pattern of the original growths for a few generations (figs. 111–113), may ultimately change to become rapidly growing fibrosarcomas.

References

Gross, L. "Spontaneous" leukemia developing in C3H mice following inoculation, in infancy, with AK-leukemic extracts, or AK-embryos. Proc. Soc. Exper. Biol. & Med., 76:27–32, 1951.

_____. Neck tumors, or leukemia, developing in adult C3H mice following inoculation, in early infancy, with filtered (Berkefeld N), or centrifugated (144,000 x g), AK-leukemic extracts. Cancer, 6:948–957, 1953.

_____. A filtrable agent, recovered from AK leukemic extracts, causing salivary gland carcinomas in C3H mice. Proc. Soc. Exper. Biol. & Med., 83:414–421, 1953.

Figge, F. H. J. Appearance of lymphatic leukemia in a colony of C3H mice. Proc. Am. Assoc. for Cancer Research, 1:13–14, 1954.

Law, L. W., Dunn, T. B., and Boyle, P. J. Neoplasms in the C3H strain and in F_1 hybrid mice of two crosses following introduction of extracts and filtrates of leukemic tissues. J. Nat. Cancer Inst., 16:495–539, 1955.

Lippincott, S. W., Edwards, J. E., Grady, H. G., and Stewart, H. L. A review of some spontaneous neoplasms in mice. J. Nat. Cancer Inst., 3:199–210, 1942.

Stewart, S. E. Neoplasms in mice inoculated with cell-free extracts or filtrates of leukemic mouse tissues. I. Neoplasms of the parotid and adrenal glands. J. Nat. Cancer Inst., 15:1391–1415, 1955.

———, Neoplasms in mice inoculated with cell-free extracts or filtrates of leukemic mouse tissues. II. Leukemia in hybrid mice produced by cell-free filtrates. J. Nat. Cancer Inst., 16:41–53, 1955.

———, and Borgese, N. G. Histologic "hypervolemia" in mice carrying transplanted parotid gland tumors. Proc. Am. Assoc. for Cancer Research, 2:150, 1956.

TUMORS OF THE FORESTOMACH

Squamous-cell Carcinoma G8755. Mouse

DEFINITION. A spontaneous squamous cell carcinoma of the forestomach of a mouse of the $C3H_f$/He strain.

HISTORY AND DESCRIPTION OF ORIGINAL TUMOR. The tumor arose spontaneously in 1949 in a 22-month-old strain $C3H_f$/He mouse in the laboratory of W. E. Heston at the National Cancer Institute, Bethesda, Maryland. At necropsy, the forestomach was found to be greatly enlarged. The serosal surface was irregular, and the wall of the viscus considerably thickened. The mucosal surface appeared hyperkeratotic. There were no metastases. The neoplasm, located in the forestomach near the limiting ridge, infiltrated all coats of the viscus and extended onto the peritoneal surface. The carcinomatous tissue had spread along the serosa of the glandular stomach and had secondarily infiltrated the muscularis of this chamber (fig. 115). The mucous membrane of the forestomach adjoining the carcinoma showed acanthosis and hyperkeratosis. The invading tumor tissue was composed of cords, nests, and sheets of neoplastic cells. There were epithelial pearls and cystlike structures lined with neoplastic cells and filled with keratin and parakeratotic material (figs. 116, 117). The pattern was that of a well differentiated squamous cell carcinoma. Several mitotic figures were found in each oil immersion field examined. The stroma consisted of granulation tissue with numerous inflammatory cells of various types.

TRANSPLANTATION STUDIES. The tumor has been transplanted only to $C3H_f$/He host mice. Transplants grow successfully without regression in 100 percent of the hosts. Transplanted tumors become palpable at about 21 days following subcutaneous inoculation. Forty days after inoculation the tumor measures approximately 1.5 cm. in diameter, and it kills the host in about 60 days. There has been no change in histologic pattern following repeated transplantation. The tumor was in the 46th transplant generation on Septem-

SQUAMOUS-CELL CARCINOMA G8755. MOUSE

(Histologic sections and tumor-bearing animal courtesy of Dr. W. E. Heston, National Cancer Institute, Bethesda, Md.)

Figure 115. Low power photomicrograph of original tumor in the forestomach of the mouse. Most of the specimen consists of glandular stomach (above) with the remains of the limiting ridge and forestomach below. The limiting ridge is almost completely replaced by neoplastic tissue which spreads along the serosa of this large segment of the glandular stomach. Note the numerous keratinized cystic structures of the tumor. Hematoxylin and eosin stain. X 7. N. C. I. 8289; A. F. I. P. Acc. No. 219934–116.

Figure 116. Photomicrograph of original tumor in the forestomach of the mouse. An area of the muscular wall of the stomach permeated by neoplastic tissue. Hematoxylin and eosin stain. X 100. N. C. I. 8228; A. F. I. P. Acc. No. 219934–117.

Figure 117. Photomicrograph of original tumor in the forestomach of the mouse. Much of the tumor is composed of cystlike structures lined by neoplastic cells and filled with keratin and parakeratotic epithelium. Hematoxylin and eosin stain. X 37. N. C. I. 8271; A. F. I. P. Acc. No. 219934–118.

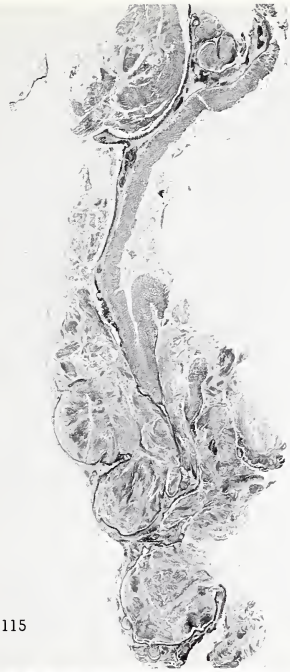

Fig. 115

Fig. 116

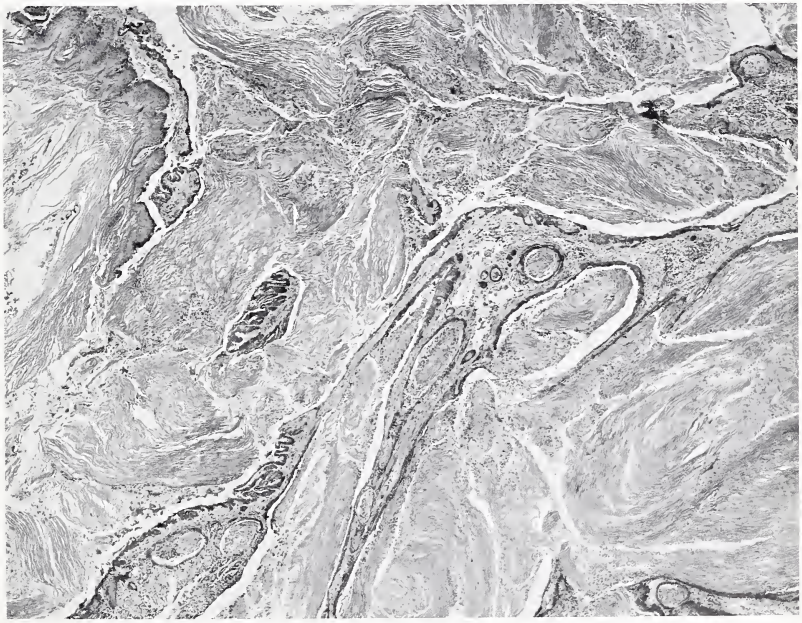

Fig. 117

SQUAMOUS-CELL CARCINOMA G8755. MOUSE

Figure 118. Photomicrograph of 22nd generation transplant tumor. The tumor is composed of sheets, nodules, and nests of malignant epithelial cells. Hematoxylin and eosin stain. X 76. N. C. I. 7455; A. F. I. P. Acc. No. 219934–119.

Figure 119. Photomicrograph of 22nd generation transplant tumor. This shows pearl formation in a sheet of tumor cells. Hematoxylin and eosin stain. X 300. N. C. I. 7449; A. F. I. P. Acc. No. 219934–120.

Figure 120. Photomicrograph of 22nd generation transplant tumor showing tonofibrils. Phosphotungstic acid—hematoxylin stain. X 570. N. C. I. 8252; A. F. I. P. Acc. No. 219934–121.

Fig. 118

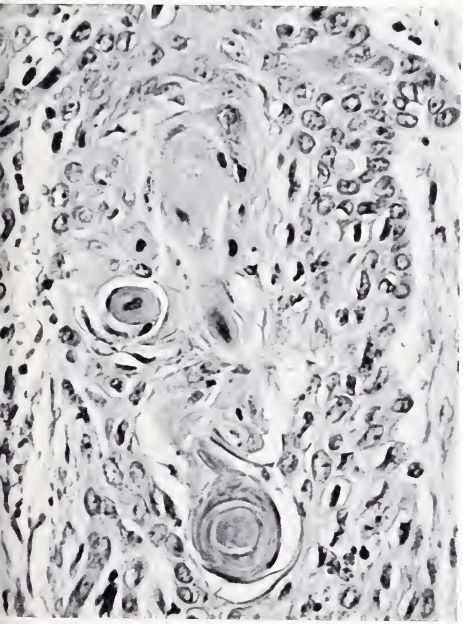

Fig. 119

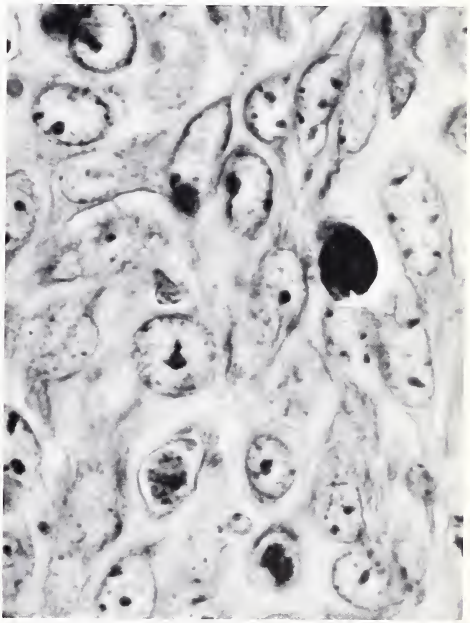

Fig. 120

ber 25, 1954. (Many of these data were obtained in personal interview with Dr. W. E. Heston of the National Cancer Institute, Bethesda, Md.)

DESCRIPTION OF CURRENT TUMOR. The tumor of the 22nd transplant generation measures 1.5 x 1 x 1 cm., four and a half weeks after subcutaneous inoculation. It is firm in consistency and is surrounded by compressed host tissue. The cut surface is yellowish gray, slightly friable, and shows virtually no evidence of necrosis.

The transplanted Squamous-cell Carcinoma G8755 is not confined by the capsule but invades the surrounding skeletal muscle and areolar tissue as well as the perivascular and perineural tissues of the host. The tumor is composed of sheets, nodules, and nests of malignant epithelial cells surrounded and separated from each other by stroma (fig. 118). The neoplastic cells are hyperchromatic and vary in shape. They may be round, polygonal, flat, elongated, and spindle shaped. Keratin occurs diffusely in the large sheets of tumor cells and is also seen within the numerous epithelial pearls (fig. 119). There is also single cell keratinization. This squamous cell tumor possesses many tonofibrils in the form of the spiral fibrils of Herxheimer and finer intracellular fibrils, both of which are demonstrated by the phosphotungstic acid—hematoxylin stain (fig. 120). The tumor cell has a large nucleus with a heavily stained nuclear membrane and from 1 to 3 nucleoli. The nucleus has a delicate linin network containing finely granular chromatin that is often concentrated near the nuclear membrane. As many as 13 mitotic figures have been counted in a single high power field, and almost all of them are fairly regular in appearance. Most of the tumor tissue is viable. The largest area of necrosis does not fill a low power field, and only two such areas of this size are observed. There is very little evidence of hemorrhage.

In some areas the stroma is collagenous, and in other areas it is composed of young fibroblasts with a few thin-walled blood vessels. The stroma is abundant at the periphery of some parts of the tumor, suggesting a desmoplastic reaction. It is sometimes difficult to distinguish stroma cells from tumor cells on an individual basis, because the neoplastic cells are often spindle shaped and the stroma is desmoplastic. In most parts of the tumor the reticular and collagenic fibers are confined to the stroma. However, the amount and distribution of the reticulum vary in those areas of the tumor that are composed of spindle-shaped cells. In such areas reticular fibers may be completely absent or intermingled with the spindle-shaped cells.

References

Stewart, H. L. Experimental cancer of the alimentary tract. In: Homburger, F., and Fishman, W. H. (eds.). The Physiopathology of Cancer, pp. 3–45. New York: Paul B. Hoeber, Inc., 1953.

Wells, H. G., Slye, M., and Holmes, H. F. Comparative pathology of cancer of the alimentary canal, with report of cases in mice. Am. J. Cancer, 33:223–238, 1938.

TUMORS OF THE GLANDULAR STOMACH

Gastric Adenocarcinoma 303. Mouse

DEFINITION. An adenocarcinoma induced in a strain C3H mouse by the injection of 20-methylcholanthrene into the wall of the glandular stomach.

HISTORY AND DESCRIPTION OF ORIGINAL TUMOR. The tumor was induced by injection of 0.015 cc. of an aerosol-methocel suspension containing 30 mg. per cc. of 20-methylcholanthrene at each of two adjacent sites in the anterior wall of the gastric antrum. The injections were made on October 21, 1948, in the laboratory of H. L. Stewart at the National Cancer Institute in Bethesda, Maryland. The animal was killed on July 14, 1949, at which time it had a palpable abdominal mass. At necropsy there were perigastric adhesions. The distal portion of the glandular stomach was involved by a tumor 1.5 cm. in diameter which was in part nodular and firm, and in part soft, dark, and yellow. The neoplasm was elevated on the mucosal surface and extended through all coats of the wall of the stomach onto the serosa, infiltrating the pancreas, liver, and lesser omentum. Due to pyloric obstruction, there was secondary dilatation of the stomach. The intestine contained fresh blood. No distant metastases were found.

Microscopically, the tumor was a mixed growth, the result of the collision of two tumors—an adenocarcinoma and a sarcoma (figs. 121, 122). The wall of the stomach was extensively permeated by tumor, and there were several ulcers on the mucosal surface. The greater portion of the tumor that exhibited a carcinomatous pattern was present on the mucosal surface and infiltrated all coats of the wall of the stomach, the liver, and the pancreas. This epithelial portion of the growth was composed of acini, cords, and sheets of cells supported by thin strands of mature fibrous tissue having more reticular than collagenic fibers. The tumor possessed few blood vessels, and these were of capillary size. The cells of the carcinoma were cuboidal, columnar, and polygonal, with an average diameter of 20 microns, and they were fairly uniform in size, shape, and staining capacity. There was almost no periodic acid—Schiff-positive material in these cells. The cell generally possessed one nucleus that was round or oval and hyperchromatic. It contained several deeply colored chromatin granules, and in nearly every case there were two nucleoli near the periphery. As many as six mitotic figures were found in a single high power field.

Most of that portion of the tumor which exhibited a sarcomatous pattern was separate and distinct from the carcinomatous portion, but the two types of tissue were intermingled at their junction. The sarcoma was composed of interlacing bundles of spindle-shaped cells with an average diameter of 5 microns and an average length of 30 microns. Almost every cell was enmeshed in a network of reticular fibrils. There was usually one elongated basophilic nucleus which contained an acidophilic nucleolus. The cytoplasm

GASTRIC ADENOCARCINOMA 303. MOUSE

Figure 121. Photomicrograph of original tumor. The primary tumor from which Gastric Adenocarcinoma 303 was derived was a mixed growth, the result of the collision of two tumors—one an adenocarcinoma, shown on the left, and the other a sarcoma, shown on the right. In this field the tumor has replaced the wall of the stomach and infiltrated the pancreas. Hematoxylin and eosin stain. X 66. N. C. I. 6470; A. F. I. P. Acc. No. 219934–122.

Figure 122. A higher power photomicrograph of original tumor. This is a portion of the field shown in figure 121 at the junction of the adenocarcinoma and the sarcoma. Hematoxylin and eosin stain. X 280. N. C. I. 6487; A. F. I. P. Acc. No. 219934–123.

Figure 123. Section of intravascular deposit of tumor in the lung of a mouse bearing a subcutaneous transplant tumor of the 14th generation. Hematoxylin and eosin stain. X 200. N. C. I. 6483; A. F. I. P. Acc. No. 219934–124.

Figure 124. Section of a metastasis in the axillary lymph node of a mouse bearing a subcutaneous transplant tumor of the 14th generation. Hematoxylin and eosin stain. X 55. N. C. I. 3343; A. F. I. P. Acc. No. 219934–125.

Fig. 121

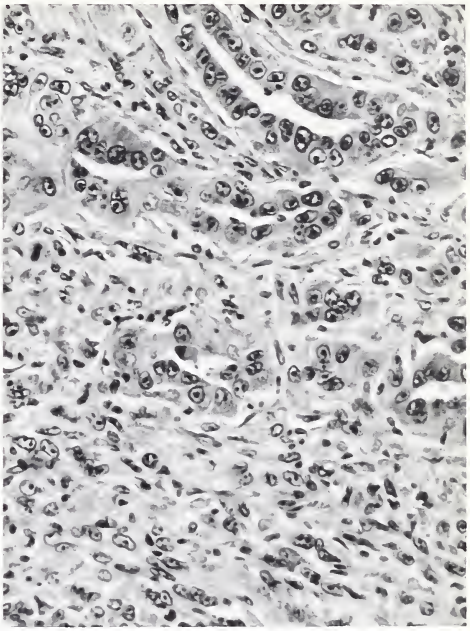

Fig. 122

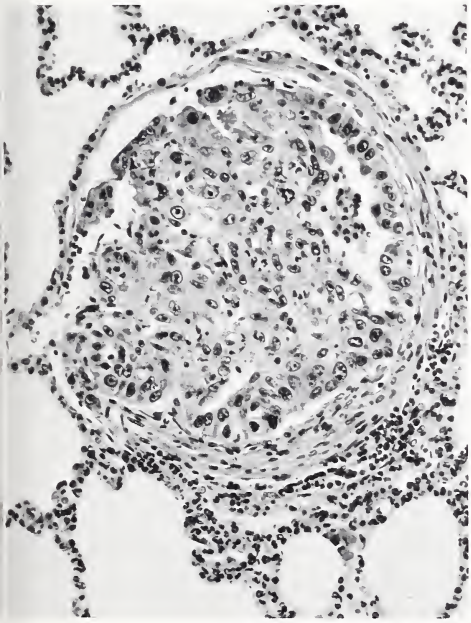

Fig. 123

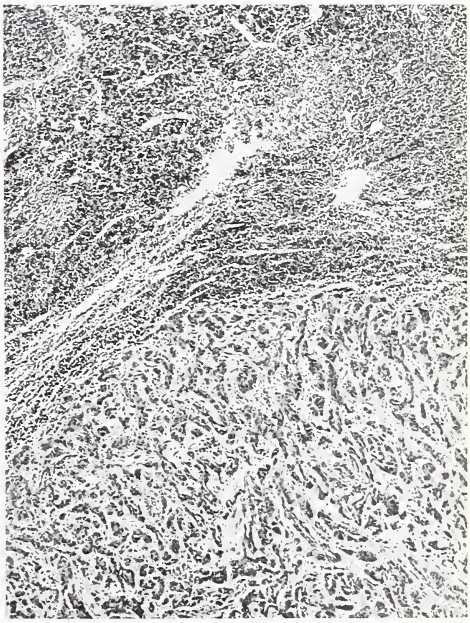

Fig. 124

was abundant and homogeneous. There was an average of two mitotic figures in each high power field. The blood vessels were sinusoidal. Although reticular fibers were numerous, there were not many collagenic fibers, and there was little connective tissue stroma.

TRANSPLANTATION STUDIES. Fragments of the original tumor were transplanted subcutaneously into C3H mice. Six weeks after the transfer, the transplanted tumors measured on the average 20 x 15 x 10 mm. and had metastasized to the lungs. Since the 5th generation, the tumor has been carried in $C3H_f$ mice. The tumor transplant grew successfully without regression in nearly 100 percent of mice of both the C3H and $C3H_f$ strains. With repeated transfer, the growth rate increased so that by the 20th generation the transplanted tumor became palpable in about 10 days, had a diameter of 1.5 cm. at 21 days, and killed the host in from 90 to 100 days after transfer. Metastases were often observed in the lungs (fig. 123), and occasionally in lymph nodes (fig. 124) and kidneys. Mice bearing transplanted tumors frequently developed widespread amyloidosis. Transplantation to mice of strains A, DBA, or C57BL was unsuccessful.

Mice with transplanted tumors of the 11th and 14th generations were allowed to live as long as possible to allow full opportunity for metastasis to occur. After three and a half months the animals were killed. A portion of each of these transplanted tumors consisted of several small hard compact nodules, which microscopically proved to be foci of sarcoma. The remainder of the tumor and the metastases in the lymph nodes and lungs exhibited the pattern of adenocarcinoma. On August 30, 1954, the tumor was in its 76th generation. With the exception of transplants of the 11th and 14th generations, sarcoma has not been observed.

DESCRIPTION OF CURRENT TUMOR. A transplanted tumor in the subcutaneous tissue of the axilla grew rapidly and reached a diameter of 2 cm. in four weeks. At necropsy, there is an incomplete capsule of connective tissue through which the tumor tissue extends into the adjacent host tissue. The tumor tissue is grayish pink and granular, and in the center there are hemorrhage and liquefaction necrosis.

Microscopically, the capsule of the tumor is composed of connective tissue, within which are dilated thin-walled blood vessels that sometimes contain tumor thrombi. There are only a few blood vessels within the tumor, and they are all of capillary type. The neoplastic cells are arranged in sheets, cords, and acini. The acini are irregular in shape and are lined with a single layer of cells. The cells in the transplanted tumor are similar to those of the original tumor. They are generally cuboidal and have only a little cytoplasm and a single nucleus. Abnormal mitotic figures are not uncommon. Mitotic activity is more marked in the transplanted than in the primary tumor, and the connective tissue stroma and reticulum are also more abundant.

References

Stewart, H. L. Experimental cancer of the alimentary tract. In: Homburger, F., and Fishman, W. H. (eds.). The Physiopathology of Cancer, pp. 3–45. New York: Paul B. Hoeber, Inc., 1953.

_____, Hare, W. V., and Bennett, J. G. Tumors of the glandular stomach induced in mice of six strains by intramural injection of 20-methylcholanthrene J. Nat. Cancer Inst., 14:105–125, 1953.

Gastric Adenocarcinoma 328. Mouse

DEFINITION. An adenocarcinoma, induced in a strain C57BL mouse by the injection of 20-methylcholanthrene into the wall of the glandular stomach, which causes hypervolemia in animals bearing transplanted tumors.

HISTORY AND DESCRIPTION OF ORIGINAL TUMOR. The tumor was induced by two injections of 0.015 cc. of an aerosol-methocel suspension containing 30 mg. per cc. of 20-methylcholanthrene. The injections were made into the anterior wall of the antrum of the glandular stomach at each of two adjacent sites. The animal, a 3-month-old male mouse, received the injections June 13, 1949, in the laboratory of H. L. Stewart at the National Cancer Institute, Bethesda, Maryland. The mouse was killed on December 20, 1949, following the development of a palpable abdominal tumor.

The distal portion of the glandular stomach was encircled by tumor tissue which extended into the pancreas, the lesser omentum, and the liver. There were also local inflammatory adhesions. Upon opening the stomach, which was distended, the mucosa of the glandular chamber was found to be ulcerated and distorted by tumor tissue. The forestomach showed hyperkeratosis (fig. 125).

Microscopically, the tumor was a well differentiated papillary adenocarcinoma, supported by mature connective tissue (figs. 126, 127). The growth was made up chiefly of simple or complex acini and a few nests and cords of cells (fig. 128). The cellular lining of the more complicated acini was folded and papillary. There was no periodic acid—Schiff-positive material either in the cytoplasm of the tumor cells or within the lumen of the glands. The lumen occasionally contained desquamated tumor cells and leukocytes.

The prevailing cell type of the carcinoma was a tall columnar cell, usually measuring 5 x 8 microns, and resembling the surface epithelial cell of the normal glandular stomach. Other cells were cuboidal or flattened. The cytoplasm was homogeneous or faintly granular and deeply acidophilic. The nucleus was elongated and centrally located. It contained several heavy chromatin bars and rarely, a nucleolus. Mitotic figures varied in number from 1 to 4 per high power field and appeared normal.

The blood vessels were few in number and were confined to the stroma, which was composed of fibrous tissue having some reticular and collagenic fibers. There were a few areas of necrosis, hemorrhage, and inflammatory change.

GASTRIC ADENOCARCINOMA 328. MOUSE

Figure 125. Gross photograph of original tumor of stomach showing the forestomach below and the glandular stomach above, separated by the limiting ridge. The esophagus enters the stomach from the left, and above it is the duodenum. The antrum is thickened by a carcinoma which extends through all coats of the viscus. There is ulceration of the mucosa. N. C. I. 1905; A. F. I. P. Acc. No. 219934–126.

Figure 126. Photomicrograph of original tumor. This shows extension of the gastric neoplasm into the wall of the glandular stomach just lateral to the area of ulceration. The neoplastic cells are growing in the form of acini, cords, and nests. Hematoxylin and eosin stain. X 130. N. C. I. 6712; A. F. I. P. Acc. No. 219934–127.

Figure 127. Section of pancreas of the original tumor-bearing mouse. Note infiltration by neoplastic tissue. Hematoxylin and eosin stain. X 66. N. C. I. 6685; A. F. I. P. Acc. No. 219934–128.

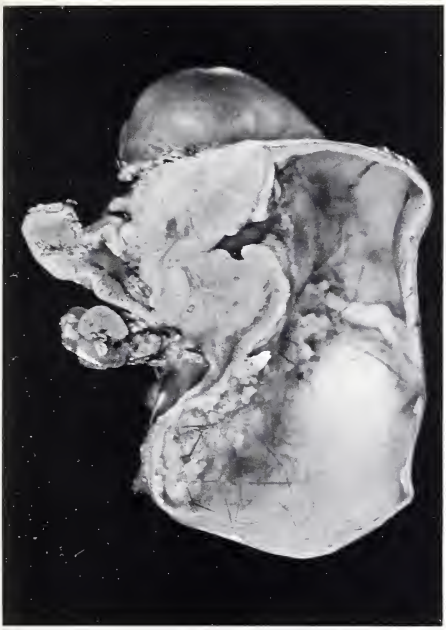

Fig. 125

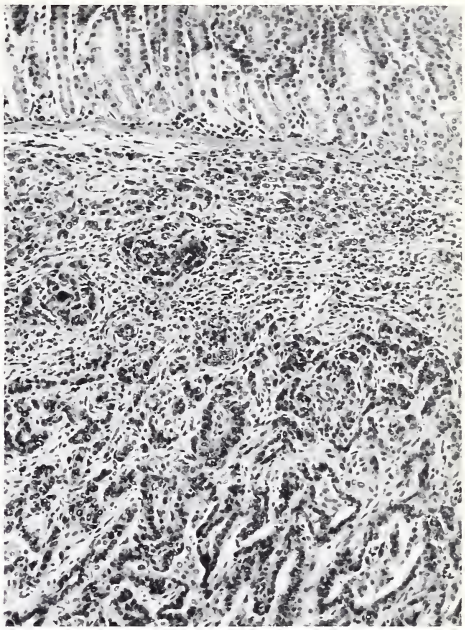

Fig. 126

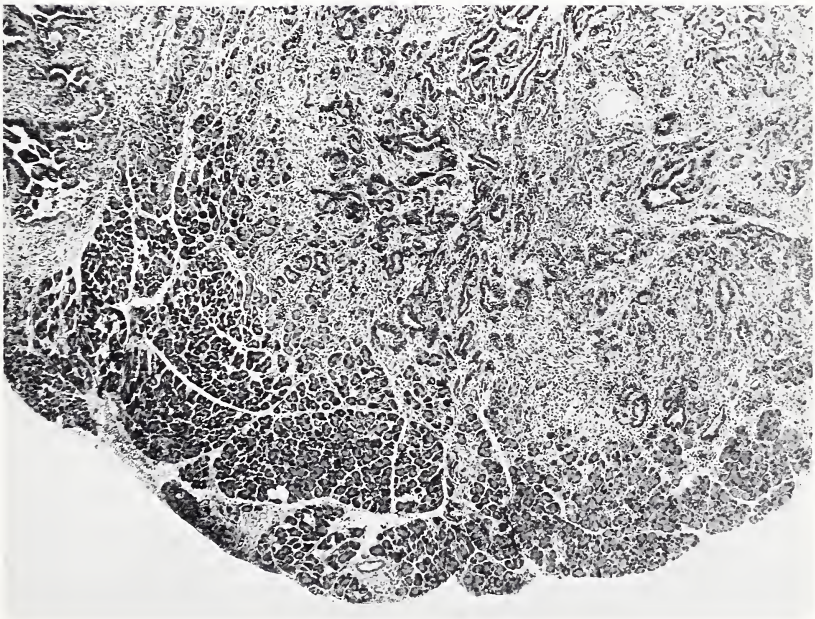

Fig. 127

GASTRIC ADENOCARCINOMA 328. MOUSE

Figure 128. Photomicrograph of original tumor. This is a portion of the neoplasm from the wall of the glandular stomach showing the character of the neoplastic cells. Hematoxylin and eosin stain. X 225. N. C. I. 6713; A. F. I. P. Acc. No. 219934–129.

Figure 129. Section of metastasis in axillary lymph node of a mouse bearing a subcutaneous transplant of 7th generation tumor. Hematoxylin and eosin stain. X 80. N. C. I. 6681; A. F. I. P. Acc. No. 219934–130.

Figure 130. Section of metastasis in the lung of a mouse bearing a subcutaneous transplant of 7th generation tumor. Hematoxylin and eosin stain. X 85. N. C. I. 6682; A. F. I. P. Acc. No. 219934–131.

Figure 131. Section of an adrenal gland of a mouse bearing a subcutaneous transplant of 22nd generation tumor. This animal had hypervolemia. Hematoxylin and eosin stain. X 58. N. C. I. 6678; A. F. I. P. Acc. No. 219934–132.

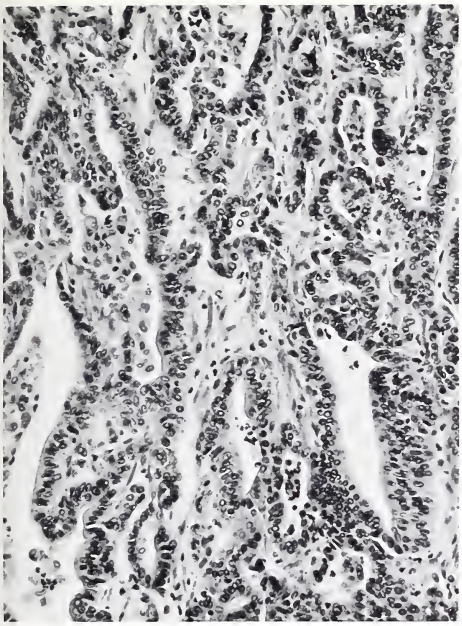

Fig. 128

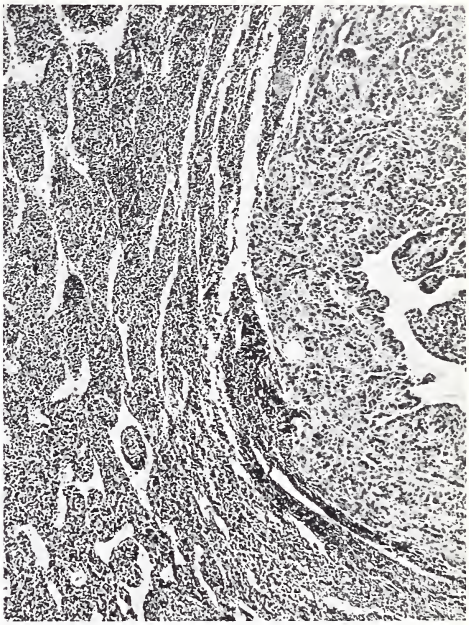

Fig. 129

Fig. 130

Fig. 131

GASTRIC ADENOCARCINOMA 328. MOUSE

Figure 132. Section of liver of a mouse bearing a subcutaneous transplant of 37th generation tumor. This animal had hypervolemia. Hematoxylin and eosin stain. X 280. N. C. I. 7638; A. F. I. P. Acc. No. 219934–133.

Figure 133. Section of heart of a mouse bearing a subcutaneous transplant of 37th generation tumor. This animal had hypervolemia. The chambers of the heart are dilated and the walls of the ventricles are hypertrophied. Hematoxylin and eosin stain. X 15. N. C. I. 7642; A. F. I. P. Acc. No. 219934–134.

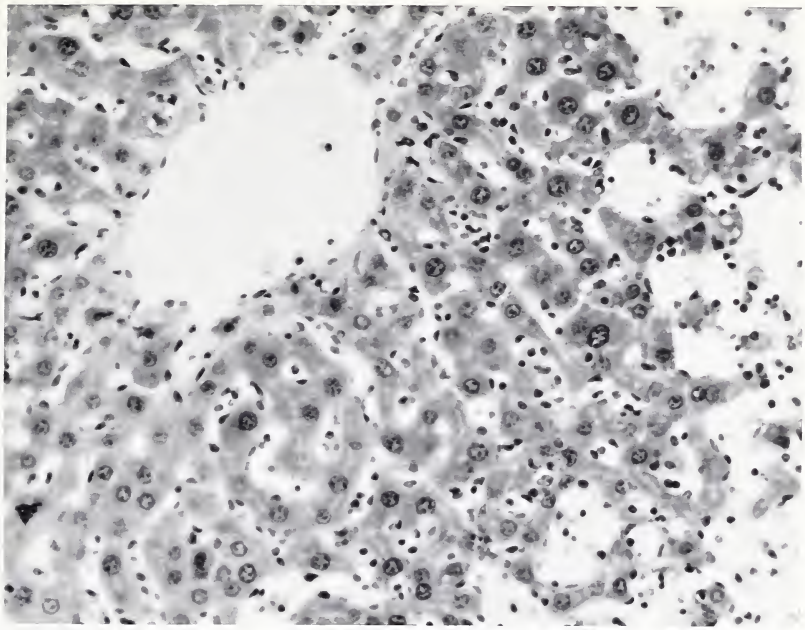

Fig. 132

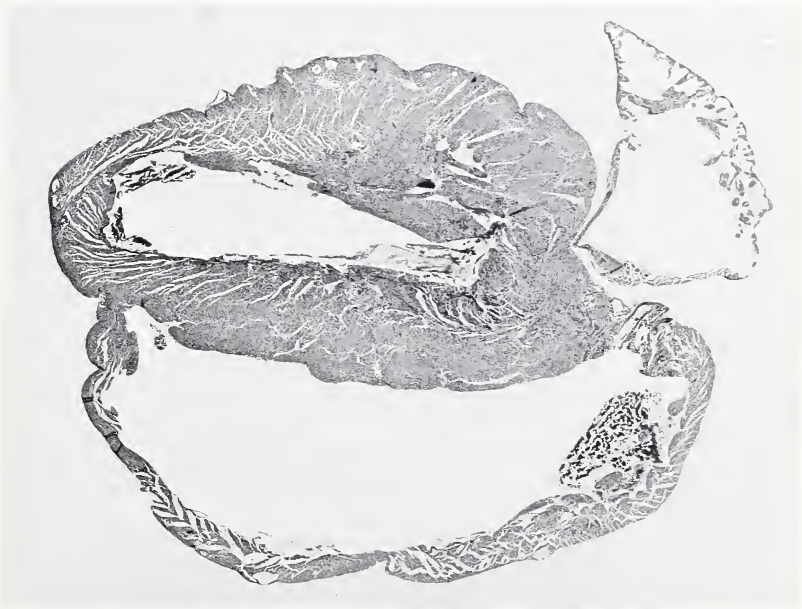

Fig. 133

TRANSPLANTATION STUDIES. Pieces of the tumor were transplanted subcutaneously to C57BL mice, and two months later the resulting growths had an average diameter of 10 mm. From the outset, the tumor grew progressively without regression in nearly 100 percent of animals inoculated. The tumor is now transplanted at intervals of four weeks. It has metastasized to regional lymph nodes (fig. 129), lungs (fig. 130), liver, diaphragm, and chest wall. Although in some early experiments 60 percent of the animals inoculated showed metastases, recently fewer metastases have been observed. On August 24, 1954, the tumor was in its 53rd transplant generation.

The most striking effect of the growing transplanted tumor on the host has been the occurrence of hypervolemia. While hypervolemia has been known to develop in animals with certain transplantable tumors that originated in the ovary and the mammary gland, its association with a transplantable gastric adenocarcinoma has not been previously described. In the host animals bearing the transplanted adenocarcinoma, visceral manifestations of hypervolemia were observed in the liver (fig. 132), adrenal glands (fig. 131), spleen, bone marrow, kidneys, and lungs. The heart was greatly enlarged due to hypertrophy and dilatation (fig. 133).

DESCRIPTION OF CURRENT TUMOR. A subcutaneous transplant of Gastric Adenocarcinoma 328 measures 2 cm. in diameter four weeks after inoculation. It is lobulated and surrounded by a thin capsule of connective tissue. On section, the tumor tissue is grayish pink and friable, with a central area of necrosis.

The transplanted tumor is more anaplastic than the primary tumor. Although acini are few in number, the pattern of adenocarcinoma is still recognizable. Solid areas predominate and are composed of sheets and cords of hyperchromatic polygonal cells having relatively large nuclei. The reticulum is more abundant than in the primary tumor and more frequently distributed around single cells and small groups of cells. Mitotic figures are more numerous and more abnormal in appearance in the transplanted tumor than in the primary tumor. Periodic acid—Schiff-positive material is present in the lumen of acini and occasionally in intracytoplasmic vacuoles. There are numerous discrete and confluent areas of necrosis, many of which are peripheral.

References

Gottschalk, R. G., and Furth, J. Polycythemia with features of Cushing's syndrome produced by luteomas. Acta haemat., 5:100–123, 1951.

Slye, M., Holmes, H. F., and Wells, H. G. Comparative pathology of cancer of the stomach with particular reference to the primary spontaneous malignant tumors of the alimentary canal in mice. Studies on the incidence and inheritability of spontaneous tumors in mice. J. Cancer Research, 2:401–425, 1917.

Sobel, H., and Furth, J. Hypervolemia in mice bearing granulosa cell growths; time of onset and some associated physiological and chemical changes. Endocrinology, 42:436–447, 1948.

Stewart, H. L. Experimental cancer of the alimentary tract. In: Homburger, F., and Fishman, W. H. (eds.). The Physiopathology of Cancer, pp. 3–45. New York: Paul B. Hoeber, Inc.. 1953.

———, Hare, W. H., and Bennett, J. G. Tumors of the glandular stomach induced in mice of six strains by intramural injection of 20-methylcholanthrene. J. Nat. Cancer Inst., 14:105–125, 1953.

Wolstenholme, J. T., and Gardner, W. U. Sinusoidal dilatation occurring in livers of mice with a transplanted testicular tumor. Proc. Soc. Exper. Biol. & Med., 74:659–661, 1950.

Gastric Carcinoma 342. Rat

DEFINITION. A carcinoma derived from a mixed carcinosarcoma induced in a Marshall 520 strain rat by the injection of 20-methylcholanthrene into the wall of the glandular stomach.

HISTORY AND DESCRIPTION OF ORIGINAL TUMOR. An injection of 0.02 cc. of a glycerin suspension containing approximately 1.32 mg. of 20-methylcholanthrene was made at two sites in the ventral wall of the glandular stomach of a 3-month-old male rat. One site was the distal antrum; the other, the acid-secreting portion of the glandular stomach near the limiting ridge. The injections were made on June 8, 1949, in the laboratory of H. L. Stewart at the National Cancer Institute, Bethesda, Maryland. The animal developed a palpable abdominal mass and was killed on September 1, 1950.

At necropsy, there was a smooth firm pearl-gray tumor, measuring 35 x 28 x 20 mm., involving the ventral surface of the glandular stomach and extending into the left lobe of the liver (fig. 134). All coats of the glandular stomach were infiltrated with tumor tissue, and the mucosa was extensively ulcerated. No metastases were observed.

Microscopically, the tumor exhibited a mixed carcinomatous and sarcomatous pattern (fig. 135) and was considered to be a collision tumor. The tumor replaced the entire wall of the stomach, invaded the liver, and encroached upon the omental adipose tissue. The carcinomatous portion of the tumor (fig. 136) consisted of small clusters and nests of epithelial cells, and rarely of acini. The supporting stroma appeared to be sarcomatous. The cells of the carcinoma were round or polygonal and measured from 10 to 15 microns in diameter. They possessed a small amount of deeply acidophilic cytoplasm and one large oval or lobate nucleus. The deeply stained nuclear membrane enclosed a delicate chromatin network and one small dark nucleolus. Two or three mitotic figures were observed in every high power field.

The remainder of the tumor had a sarcomatous pattern consisting of interlacing bundles of spindle-shaped cells and a few giant tumor cells (fig. 137). The spindle-shaped cell had an average length of 25 microns. It had homogeneous, pale, acidophilic cytoplasm, and a plump, oval, hyperchromatic, centrally located nucleus containing heavy chromatin bars and 2 or 3 nucleoli. The tumor was richly supplied with small blood vessels. There were also

GASTRIC CARCINOMA 342. RAT

Figure 134. Gross photograph of original tumor. A view of the internal surface of the stomach. The limiting ridge extends from right to left beginning just below the entrance of the esophagus on the right. The chamber of the glandular stomach occupies the lower portion of the specimen terminating in the duodenum at the right lower portion of the illustration. Two areas of ulceration are present in the glandular stomach. Continuous with these is a large tumor mass. A portion of the adherent liver is present at the lower margin. The incised wall of the glandular stomach is markedly thickened by neoplasm. X 1.5. N. C. I. 3243; A. F. I. P. Acc. No. 219934–135.

Figure 135. A low power photomicrograph of original tumor. This section is through one of the ulcers in the glandular stomach. The base of the ulcer is lined by sarcoma above and by mixed carcinoma and sarcoma below. Hematoxylin and eosin stain. X 50. N. C. I. 8973; A. F. I. P. Acc. No. 219934–136.

Figure 136. Photomicrograph of original tumor. Note nests of carcinoma cells lying in a sarcomatous stroma. Hematoxylin and eosin stain. X 650. N. C. I. 9079; A. F. I. P. Acc. No. 219934-137.

Fig. 134

Fig. 135

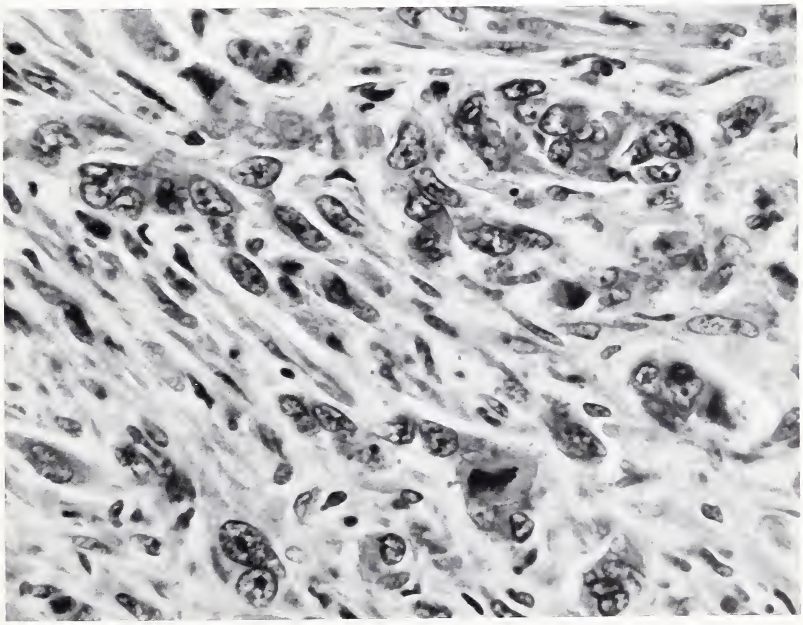

Fig. 136

GASTRIC CARCINOMA 342. RAT

Figure 137. Photomicrograph of original tumor showing a sarcomatous area. Hematoxylin and eosin stain. X 97. N. C. I. 8980; A. F. I. P. Acc. No. 219934–138.

Figure 138. Photomicrograph of 31st generation subcutaneous transplant tumor. The tumor is composed of nests, anastomosing cords, and sheets of epithelial cells. The capsule is shown above. Hematoxylin and eosin stain. X 58. N. C. I. 8981; A. F. I. P. Acc. No. 219934–139.

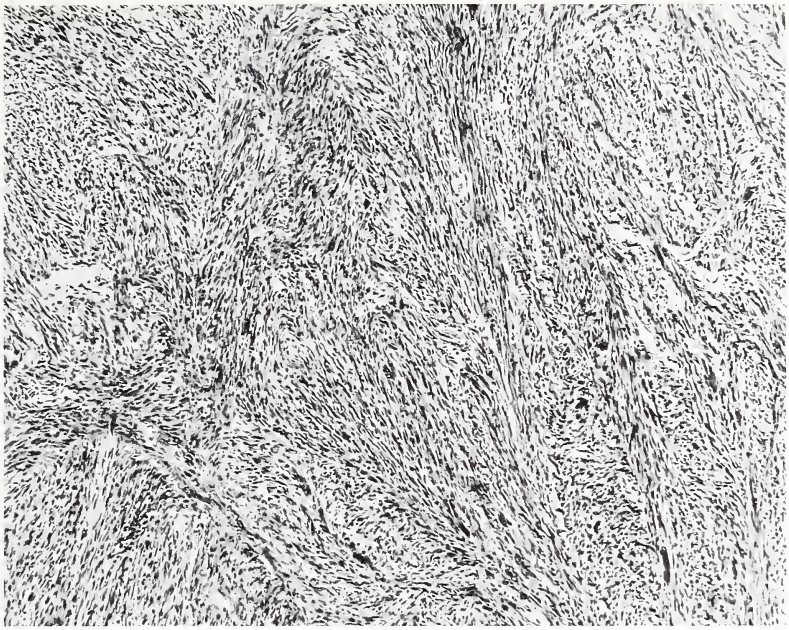

Fig. 137

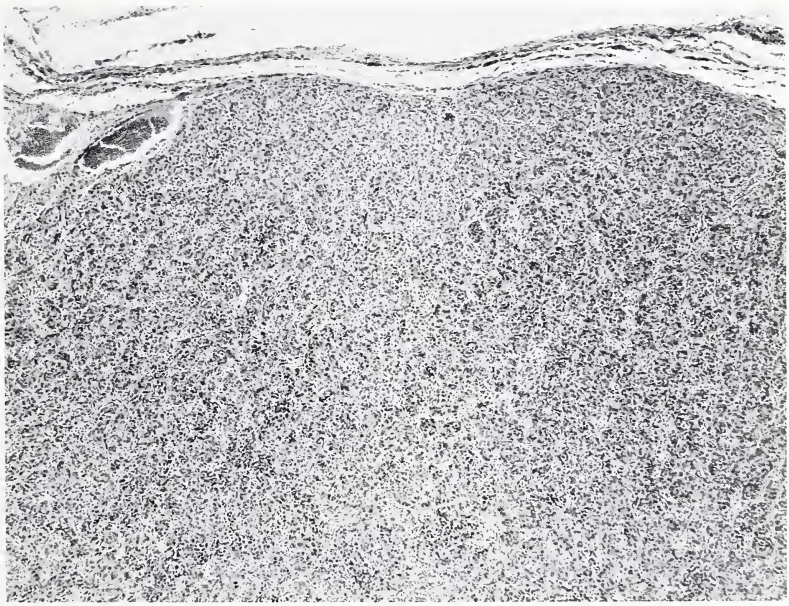

Fig. 138

GASTRIC CARCINOMA 342. RAT

Figure 139. Photomicrograph of 31st generation subcutaneous transplant tumor. There are nests of tumor cells separated from each other by pale stroma. Note the character and appearance of the tumor cells. Hematoxylin and eosin stain. X 400. N. C. I. 9074; A. F. I. P. Acc. No. 219934–140.

Figure 140. Photomicrograph of 31st generation subcutaneous transplant tumor showing nests of epithelial cells circumscribed by collagenic and reticular fibrils. Wilder's silver preparation. X 400. N. C. I. 9073; A. F. I. P. Acc. No. 219934–141.

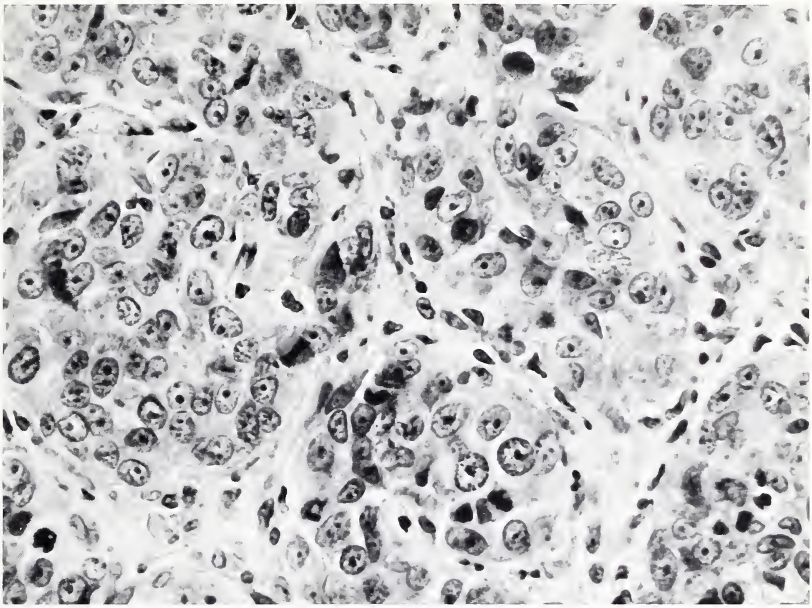

Fig. 139

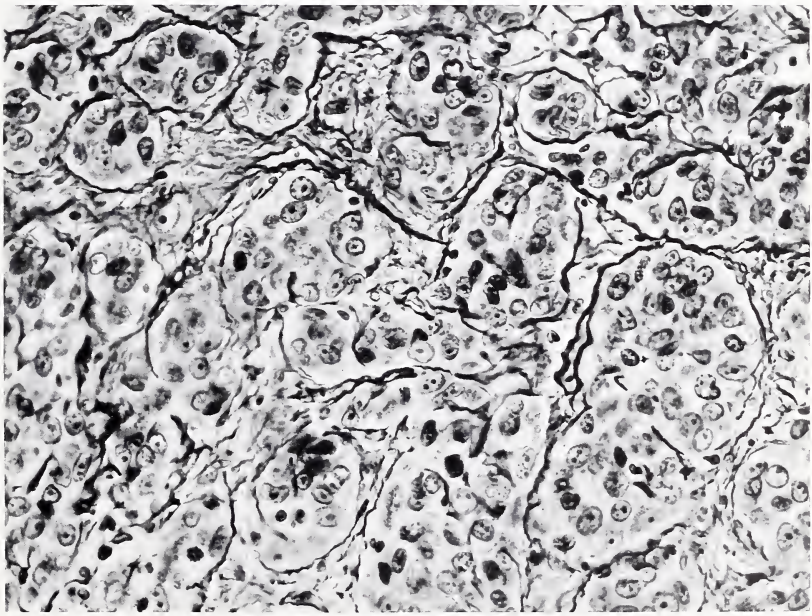

Fig. 140

numerous large dilated thin-walled vessels. There was relatively little necrosis or hemorrhage.

TRANSPLANTATION STUDIES. Subcutaneous transplants of fragments of the primary tumor measured 18 mm. in diameter two months following inoculation. With repeated transfer the growth rate increased, so that at present the transplanted tumor becomes palpable in two weeks and kills the host in 90 days. The transplanted tumor has grown successfully with no regressions and no metastases in nearly 100 percent of the animals inoculated. The sarcomatous elements of the tumor diminished following the first transplantation and entirely disappeared by the 4th generation. On September 14, 1954, the tumor was in its 35th transplant generation.

DESCRIPTION OF CURRENT TUMOR. A 4-week-old subcutaneous transplant tumor of the 31st generation has a thin fibrous capsule. The tumor measures 24 mm. in diameter, and is yellowish, firm, and smooth. There is no visible necrosis or hemorrhage.

Microscopically, the tumor is composed of nests, anastomosing cords, and sheets of epithelial cells (fig. 138). These cells are generally round or polygonal and fairly uniform in size, shape, and staining capacity (fig. 139). One third of the cell consists of acidophilic cytoplasm. The nucleus is round, has a heavily stained membrane enclosing fine, punctate, evenly distributed chromatin granules, and one basophilic nucleolus. There is an average of three mitotic figures in each high power field, and many of the figures are bizarre. The stroma surrounds nests and cords of epithelial cells and constitutes at least 30 percent of the tumor. It consists of a sparse cellular component of fibroblasts, small lymphocytes, a few granulocytes, and a large amount of eosinophilic hyalin composed of collagenic and reticular fibers (fig. 140). Immediately around each epithelial nest and cord is a thick wavy band of collagenic fibers. With the periodic acid—Schiff reaction, both the fibrillar and hyaline components of the stroma stain reddish purple, but unstained vacuoles are present. Degenerated and necrotic neoplastic cells are usually located in the center of the tumor, associated with a pronounced increase in the stroma. In the center of the tumor the hyalinized stroma often resembles osteoid tissue, but no bone or cartilage has been observed. The vessels, lined by a single layer of endothelial cells, are slitlike and not numerous. Peripherally, the tumor is sharply separated from the host tissues by a thin capsule of dense connective tissue.

References

Hare, W. V., Stewart, H. L., Bennett, J. G., and Lorenz, E. Tumors of the glandular stomach induced in rats by intramural injection of 20-methylcholanthrene. J. Nat. Cancer Inst., 12:1019–1055, 1952.

Stewart, H. L. Experimental cancer of the alimentary tract. In: Homburger, F., and Fishman, W. H. (eds.). The Physiopathology of Cancer, pp. 3–45. New York: Paul B. Hoeber, Inc., 1953.

Osteogenic Sarcoma 344. Rat

DEFINITION. An osteogenic sarcoma induced in a Marshall 520 rat by the intramural injection of 20-methylcholanthrene into the wall of the glandular stomach.

HISTORY AND DESCRIPTION OF ORIGINAL TUMOR. A 3-month-old male rat of the Marshall 520 strain received two injections of 0.02 cc. of a glycerin suspension containing approximately 1.32 mg. of 20-methylcholanthrene in the ventral wall of the glandular stomach. One injection was made into the distal antrum and the other into the acid-secreting portion near the limiting ridge. The injections were made on June 8, 1949, in the laboratory of H. L. Stewart at the National Cancer Institute, Bethesda, Maryland. The animal was killed 18 months later because of the presence of a large abdominal mass.

At necropsy, there was a nodular tumor involving the ventral surface of the stomach (figs. 141–143). The tumor was mottled gray, white, and brown and measured 6.5 x 5 x 3 cm. It distorted and displaced the stomach and the left half of the liver but did not infiltrate the perigastric structures. On section, the neoplasm was lobulated, partly cystic, partly solid, gray-white, and extensively hemorrhagic. There was an ulcer, bordered by neoplastic tissue, on the anterior mucosal surface of the glandular stomach. No metastases were found.

Microscopically, the solid areas of the tumor were composed of sheets, whorls, and interlacing bundles of spindle-shaped cells, pleomorphic cells, and giant tumor cells. Interspersed with these cells were foci of osteoid, bone, and cartilaginous tissue (figs. 144–149). The cystic areas were located near the peritoneal extension of the tumor and were exceedingly vascular. A section through the large ulcer in the glandular stomach revealed the entire thickness of the viscus at this level to be replaced by tumor tissue continuous with the mass that extended into the peritoneal cavity (fig. 143). Lateral to the ulcer, the wall of the stomach was infiltrated by neoplastic tissue, which at several points penetrated the mucosa and the muscularis mucosae.

The spindle-shaped cells measured about 15 x 60 microns and were sometimes multipolar (figs. 144, 148). The cytoplasm was dense and deeply acidophilic, and there was usually one nucleus to a cell. The nuclear membrane was heavily stained and enclosed dense, peripherally situated chromatin bars and 1 to 4 nucleoli. The pleomorphic cells and the giant tumor cells varied considerably in form, and the latter were usually multinucleated. Mitotic figures were numerous and frequently abnormal in form. The numerous deposits of osteoid, bone, and cartilage were sometimes isolated and sometimes intermingled (figs. 144, 146, 149). The osteoid appeared as a matrix containing lacunae occupied by tumor cells and showing calcareous deposits. Collagenic fibers were abundant throughout but were most plentiful in the areas of osteoid, bone, and cartilage. In the cytoplasm of some

of the giant tumor cells, there were focal deposits of hyalin that stained faintly for collagen. The reticulum was abundant, formed a delicate mesh about each cell, and was especially heavy and coarse in the areas of cartilage. In silver preparations, no reticular fibers could be found in the areas of the brownish purple and granular osteoid. Fibroglial fibers were demonstrated in the spindle cell areas of the growth. Parts of the tumor showed a myxomatous change.

Portions of the tumor had a hemangiomatous pattern with numerous dilated, often telangiectatic blood vessels, sometimes side by side or sometimes separated by only a narrow strip of tumor tissue (fig. 145). Most of these blood vessels were thin-walled and lined with a single layer of endothelial cells. Others were lined with neoplastic cells and appeared to constitute a hemangioendotheliomatous component of the tumor (fig. 147). A few vessels contained thrombi. Although necrosis and inflammatory change were not prominent features, some areas of the tumor containing thrombosed vessels were infarcted. Necrotic material was present in a few large cysts that were lined in part or in whole with a single layer of cuboidal or flattened cells. Whether these cells were endothelial cells of vessels, mesothelial cells from peritoneal inclusions, or modified tumor cells was not clear.

TRANSPLANTATION STUDIES. Fragments of the tumor were transplanted intraperitoneally to Marshall 520 rats, and six months later all animals had large tumors within the abdominal cavity. Beginning with the 5th generation, the tumor has been transplanted subcutaneously. It has grown successfully without regression in 100 percent of the host rats. No metastases have ever been found. A tumor becomes palpable at the site of inoculation within one week, measures 3 cm. in diameter at three weeks, and kills the host in from 6 to 7 weeks after inoculation. On May 26, 1955, the tumor was in its 52nd transplant generation.

DESCRIPTION OF RENAL AND OTHER EARLY TRANSPLANT TUMORS. Beginning with the initial transplant generation, the tumor has been composed histologically of polygonal and spindle-shaped cells. Bone and cartilage have not been formed in subcutaneous and intraperitoneal transplants, although hyaline deposits, considered to be osteoid, were observed in early generations. In histologic sections of the 13th transplant generation stained for alkaline phosphatase, the enzyme was concentrated in the walls of the blood vessels and in both the cytoplasm and the nucleus of nearby tumor cells. A few of the tumor cells at a distance from the vessels also gave the reaction for alkaline phosphatase. In the sections stained for acid phosphatase, both the nucleus and the cytoplasm of the majority of the tumor cells stained positively, but the blood vessels remained unstained.

Pieces of tissue from an 18th generation transplant tumor were inoculated beneath the renal capsule of several rats at the suggestion of Dr. A. H. Hilberg.

The tumors that grew in this location resembled histologically the original growth in the stomach in that they possessed numerous giant tumor cells and areas of osteoid, bone, and myxomatous change (figs. 150–153). The amount and distribution of acid and alkaline phosphatase in the renal transplants were similar to those of the subcutaneous transplant tumors.

DESCRIPTION OF CURRENT TUMOR. A 3-week-old subcutaneous transplant tumor of the 47th generation measures 3 x 2 x 2 cm. and is surrounded by a well defined fibrous capsule. On section, the tumor is firm and pinkish gray and has a central area of necrosis and hemorrhage.

Microscopically, the tumor is composed of interlacing bundles and whorls of fairly uniform spindle-shaped cells about three times the size of a smooth muscle cell (fig. 154). Some of these cells, cut in cross section, appear to be polygonal. The cytoplasm is faintly basophilic, generally homogeneous, and rarely fibrillar. The nucleus is centrally placed and may be large, oval, umbilicated, or elongated. It contains 1 to 4 deeply acidophilic nucleoli, surrounded by clumps of chromatin granules (fig. 155). There are 10 to 15 mitotic figures in each high power field. The blood vessels are not numerous and consist of small sinusoidal structures scattered fairly uniformly throughout the tumor (fig. 156). Most of the collagenic fibers appear to be concentrated on the outside of the thin-walled blood vessels. Virtually every tumor cell is surrounded by reticular fibrils (fig. 157).

There is a pronounced amount of acid phosphatase in the nucleus and cytoplasm of the cells of this tumor. The fibrillar matrix of the tumor is heavily impregnated with acid phosphatase, and this enzyme appears to persist in the fibrillar material even in areas in which the cells are necrotic and have lost their capacity for staining for acid phosphatase. There is virtually no alkaline phosphatase present except for a small amount in the contents of the blood vessels.

Even though the present subcutaneous transplant tumor produces no bone or cartilage, we are classifying this neoplasm as an osteogenic sarcoma, because the cells and fibrillar matrix of the present transplant tumor contain the acid phosphatase enzyme in large amounts, and transplants grown beneath the capsule of the kidney produce bone. The original tumor of the stomach clearly possessed the features of an osteogenic sarcoma and is an example of such a tumor arising in soft parts, a phenomenon occasionally seen in man.

References

Hare, W. V., Stewart, H. L., Bennett, J. G., and Lorenz, E. Tumors of the glandular stomach induced in rats by intramural injection of 20-methylcholanthrene. J. Nat. Cancer Inst., 12:1019–1055, 1952.

Hilberg, A. W. Morphologic variations in an osteogenic sarcoma of the mouse when transplanted to the kidney. J. Nat. Cancer Inst., 16:951–959, 1956.

OSTEOGENIC SARCOMA 344. RAT

Figure 141. Gross photograph of original tumor and posterior aspect of the stomach. Much of the glandular stomach and part of the forestomach are surrounded by tumor. Note the duodenum at "A"; esophagus at "B"; left border of the forestomach at "C." N. C. I. 3577; A. F. I. P. Acc. No. 219934–142.

Figure 142. Gross photograph of original tumor. This is a section through the stomach and the tumor showing the interior view of the anterior aspect of the stomach. Note the duodenum at "A"; left border of the forestomach at "B"; limiting ridge separating the forestomach on the left from the glandular stomach on the right at "C." There is a large ulcer occupying at least one third of the anterior wall of the stomach. The cross section of the several tumor masses reveals the gross characteristics of the neoplasm. X 1.5. N. C. I. 3581; A. F. I. P. Acc. No. 219934–143.

Figure 143. Section through the original tumor to show the ulcer and underlying tumor. The arrows point to the gastric mucous membrane. The area of ulceration lies between these two points. Hematoxylin and eosin stain. X 2. N. C. I. 4050; A. F. I. P. Acc. No. 219934–144.

Figure 144. Photomicrograph of original tumor showing bundles of spindle-shaped cells interspersed with pleomorphic cells and cartilage. Hematoxylin and eosin stain. X 100. N. C. I. 4029; A. F. I. P. Acc. No. 219934–145.

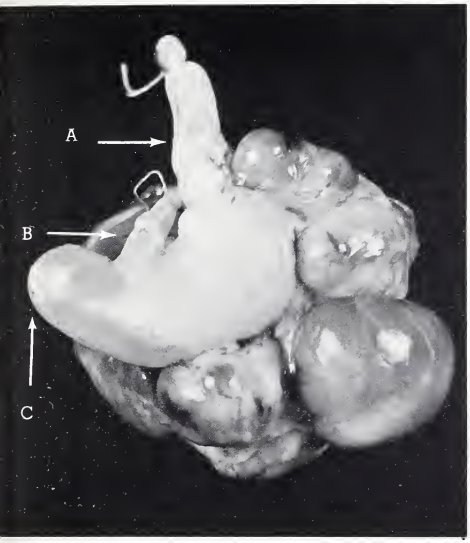

Fig. 141

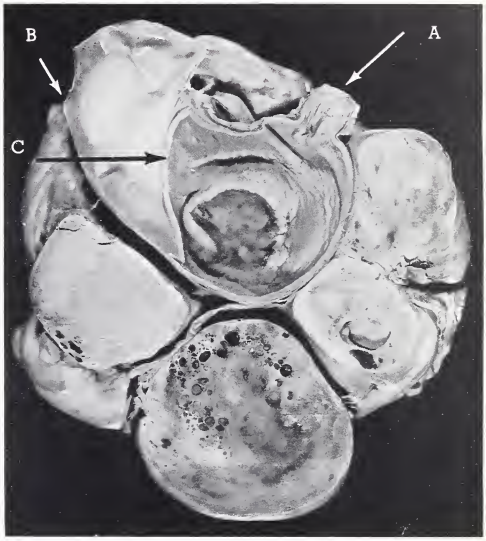

Fig. 142

Fig. 143

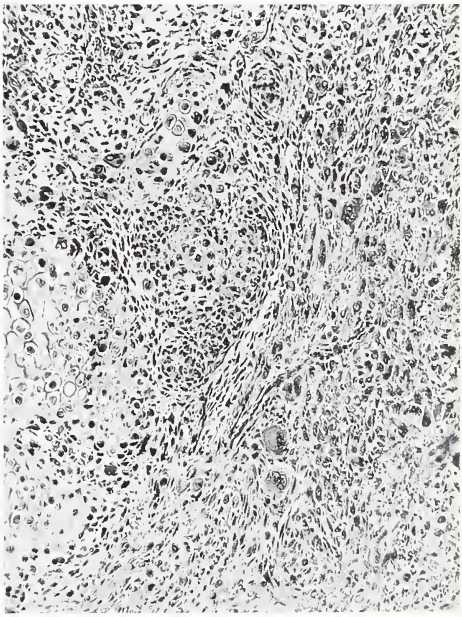

Fig. 144

OSTEOGENIC SARCOMA 344. RAT

Figure 145. Photomicrograph of original tumor showing dilated vessels in an area of the sarcoma. Hematoxylin and eosin stain. X 100. N. C. I. 4037; A. F. I. P. Acc. No. 219934–146.

Figure 146. Photomicrograph of original tumor showing area of cartilage, bone, and osteoid. Hematoxylin and eosin stain. X 100. N. C. I. 4043; A. F. I. P. Acc. No. 219934–147.

Figure 147. Photomicrograph of original tumor showing an hemangioendotheliomatous area with tumor deposits within blood vessels. Despite this, there were no metastases. Periodic acid—Schiff preparation. X 100. N. C. I. 4031; A. F. I. P. Acc. No. 219934–148.

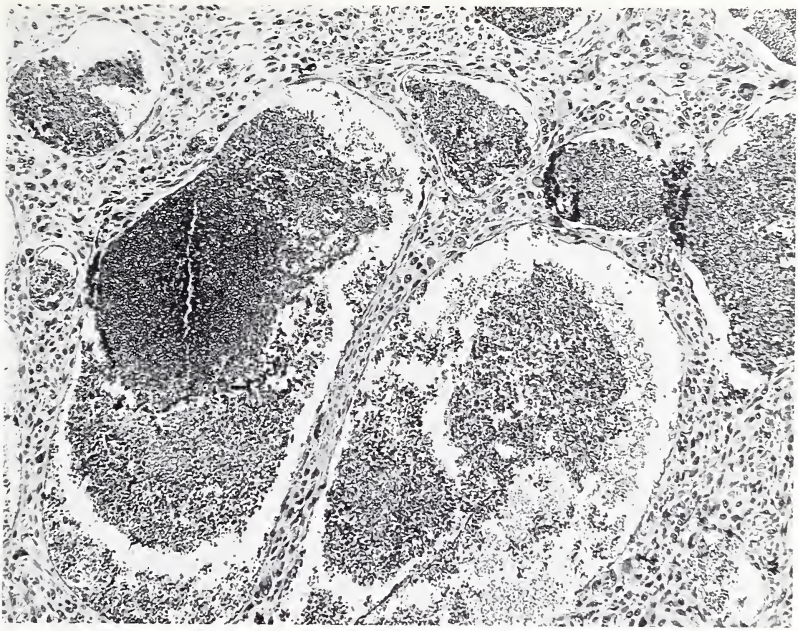

Fig. 145

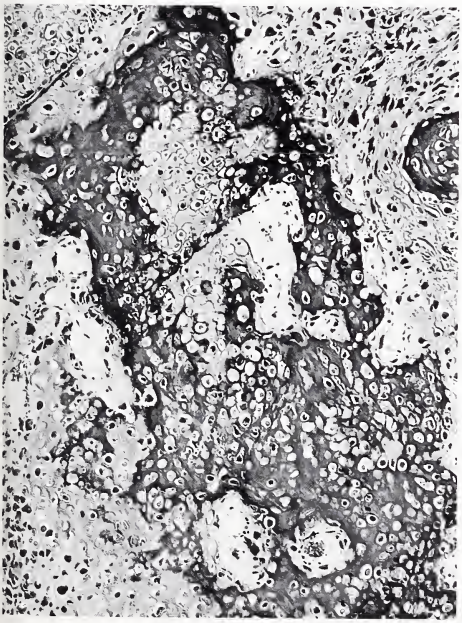

Fig. 146

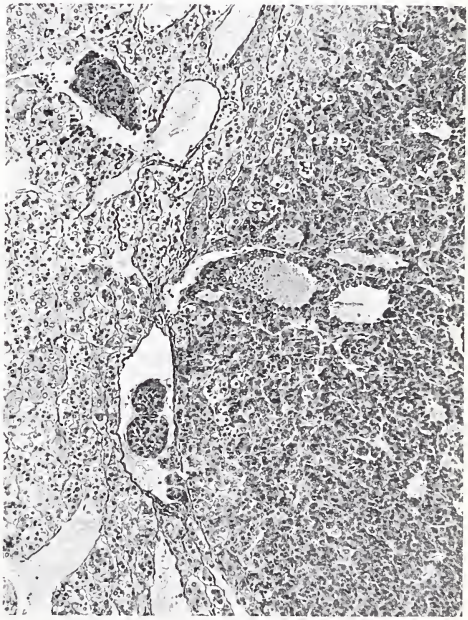

Fig. 147

OSTEOGENIC SARCOMA 344. RAT

Figure 148. Photomicrograph of original tumor showing pronounced variation in the cells. Hematoxylin and eosin stain. X 380. N. C. I. 4196; A. F. I. P. Acc. No. 219934–149.

Figure 149. Photomicrograph of original tumor. The neoplastic cells are embedded in a hyaline matrix. Hematoxylin and eosin stain. X 380. N. C. I. 4193; A. F. I. P. Acc. No. 219934–150.

Figure 150. Photomicrograph of 18th generation transplant tumor growing in the region of the kidney. Parts of the tumor are composed of interlacing bundles of spindle-shaped cells; other portions have deposits of bone. Hematoxylin and eosin stain. X 20. N. C. I. 6477; A. F. I. P. Acc. No. 219934–151.

Figure 151. Photomicrograph of 18th generation transplant tumor growing in the region of the kidney. A higher power view from a portion of the transplant shown in figure 150. Note spicules of bone. Hematoxylin and eosin stain. X 280. N. C. I. 6482; A. F. I. P. Acc. No. 219934–152.

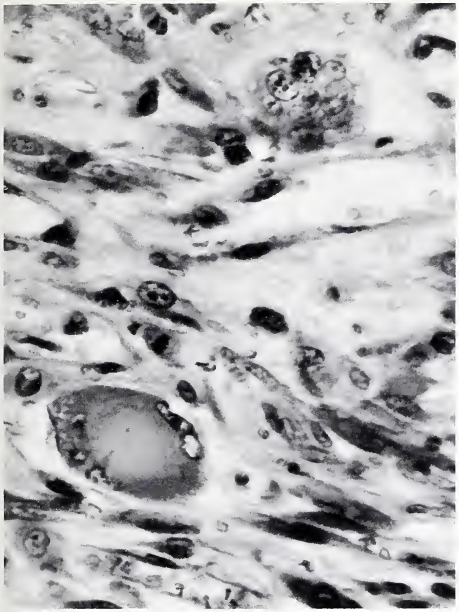

Fig. 148

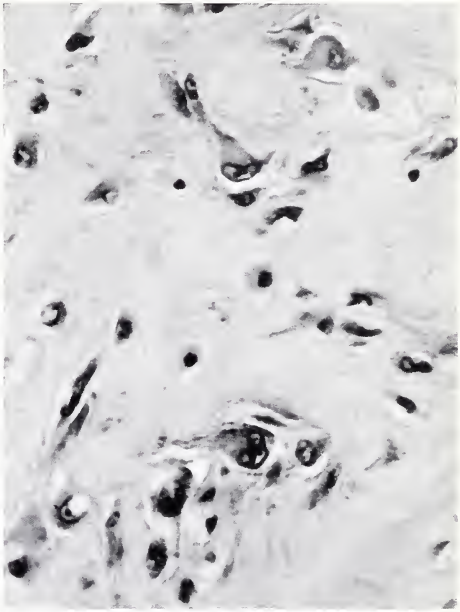

Fig. 149

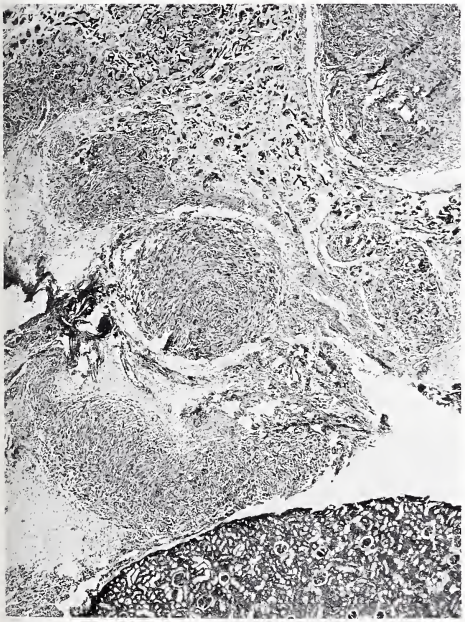

Fig. 150

Fig. 151

OSTEOGENIC SARCOMA 344. RAT

Figure 152. Photomicrograph of 18th generation transplant tumor growing in the region of the kidney. There is a large amount of alkaline phosphatase deposited chiefly in the vicinity of the blood vessels. Alkaline phosphatase preparation. X 75. N. C. I. 6131; A. F. I. P. Acc. No. 219934–153.

Figure 153. Photomicrograph of 18th generation transplant tumor growing in the region of the kidney. Both the nucleus and the cytoplasm of many of the cells stain positively for acid phosphatase. Acid phosphatase preparation. X 75. N. C. I. 6132; A. F. I. P. Acc. No. 219934–154.

Figure 154. Photomicrograph of 47th generation transplant tumor. This subcutaneous transplant tumor is composed of interlacing bundles of spindle-shaped cells. Hematoxylin and eosin stain. X 98. N. C. I. 8988; A. F. I. P. Acc. No. 219934–155.

Figure 155. Photomicrograph of 47th generation transplant tumor. High power view of cells that compose the subcutaneous transplant tumor. Hematoxylin and eosin stain. X 895. N. C. I. 8993; A. F. I. P. Acc. No. 219934–156.

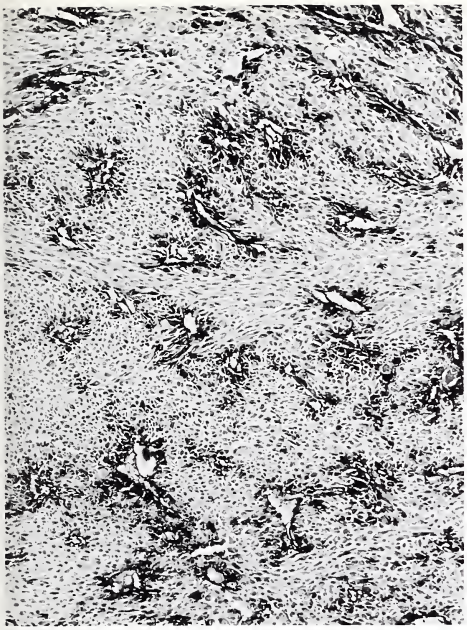

Fig. 152

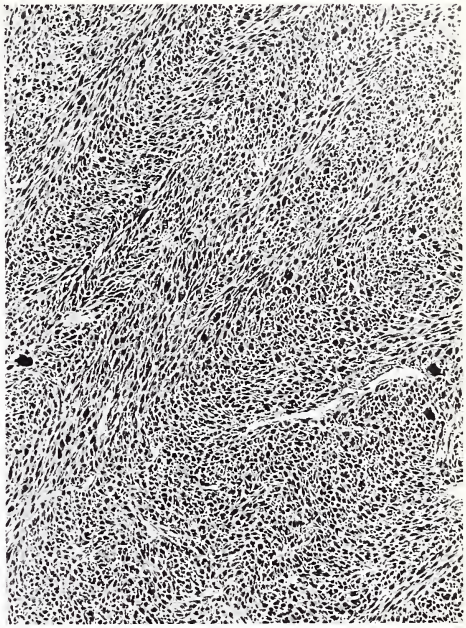

Fig. 153

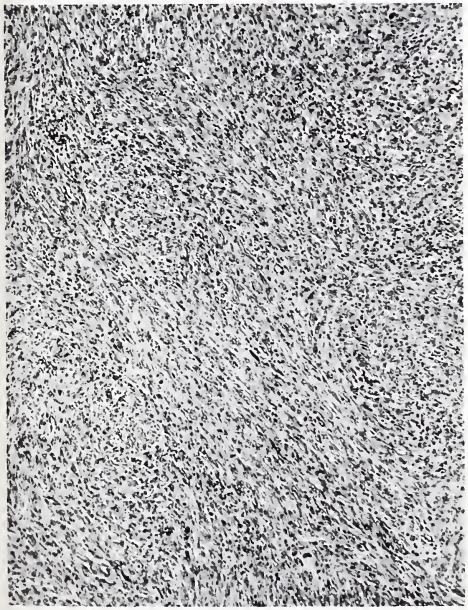

Fig. 154

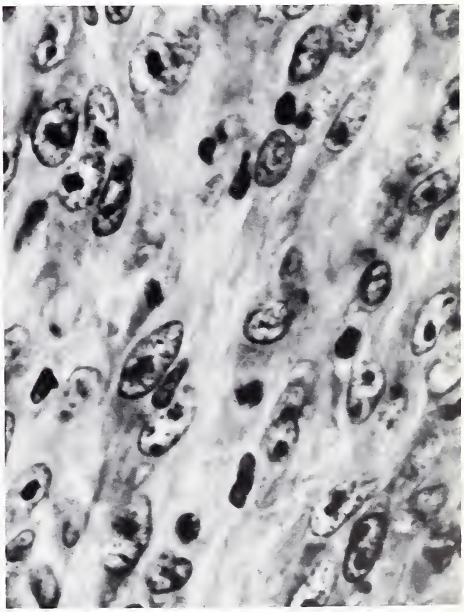

Fig. 155

OSTEOGENIC SARCOMA 344. RAT

Figure 156. Photomicrograph of 47th generation transplant tumor showing the capsule and dilated vessels in the peripheral portion of the subcutaneous transplant tumor. Hematoxylin and eosin stain. X 80. N. C. I. 8986; A. F. I. P. Acc. No. 219934–157.

Figure 157. Photomicrograph of 47th generation transplant tumor. Virtually every cell is invested with reticular fibrils. Wilder's silver preparation. X 520. N. C. I. 8991; A. F. I. P. Acc. No. 219934–158.

Fig. 156

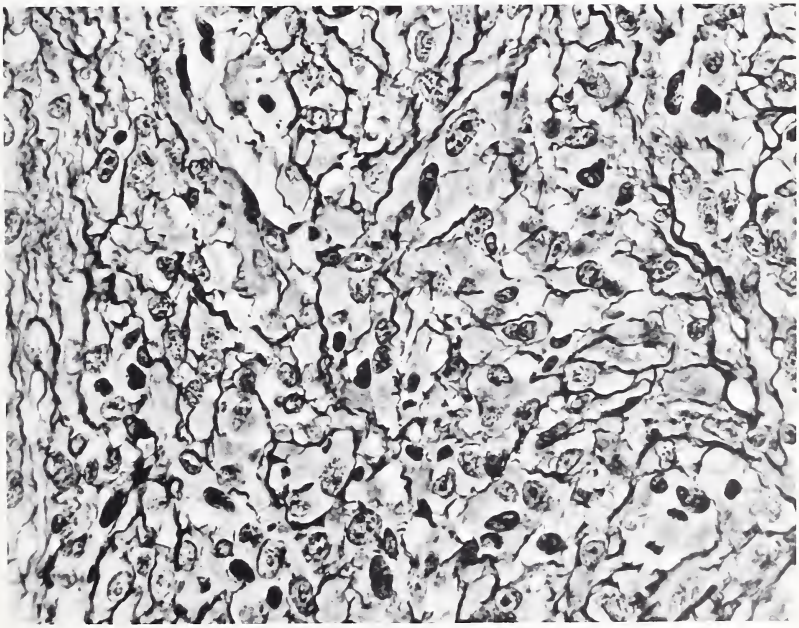

Fig. 157

TUMORS OF THE LIVER

Hepatoma 98/15. Mouse

DEFINITION. A spontaneous hepatoma of a C3H mouse.

HISTORY AND DESCRIPTION OF ORIGINAL TUMOR. Hepatoma 98/15 was found at necropsy of a 17-month-old male C3H strain mouse on September 12, 1940, in the laboratory of H. B. Andervont at the National Cancer Institute, Bethesda, Maryland. The animal had received no treatment and was in apparent good health when killed.

The tumor was a nonencapsulated, globular, solitary mass, 1.2 cm. in diameter, situated in one of the major lobes of the liver. It was sharply circumscribed, soft, and pale yellow. The external surface was covered by a smooth intact Glisson's capsule. The remainder of the liver and the other organs of the animal showed no abnormalities. No metastases or peritoneal implants were observed.

Hepatoma 98/15 had the histologic structure of a well differentiated hepatoma with cords of epithelial cells alternating regularly with endothelial-lined blood sinusoids of varying diameter (fig. 158). The liver tissue at a distance from the tumor showed no cellular abnormality and no increase in connective tissue. The epithelial cells of the neoplasm bore a striking resemblance to hepatic parenchymal cells, with well defined cell membranes, granular cytoplasm, and relatively large vesicular nuclei containing 1 to 3 large prominent basophilic nucleoli (fig. 159). The cells of the tumor could be distinguished from those of the liver by their greater size and basophilic cytoplasm. The cords of epithelial cells were not arranged in lobule formation, and no pigment granules were found within the tumor cells. A few bile ducts were found here and there, usually at the periphery of the tumor, arranged in such a way that they almost certainly represented remnants of hepatic parenchyma included within the tumor. A few mitotic figures were present in the neoplasm.

Globular bodies about the size of an average nucleus were scattered unevenly throughout the growth, usually within the cytoplasm of the tumor cells. As a rule, these bodies were acidophilic, but occasionally they were basophilic or faintly green in the hematoxylin—eosin preparation. They were reddish brown in the phosphotungstic acid—hematoxylin preparation. Mallory's aniline blue connective tissue stain revealed a blue central core, an intermediate colorless zone, and a blue outer margin.

TRANSPLANTATION STUDIES. Fragments of the hepatoma were transplanted subcutaneously by trocar into four male mice of the C3H strain. Two of these transplants grew. A tumor was found to be present in one animal at eight months and in the other at 13 months following transplantation. With successive transplantation, the growth rate of Hepatoma 98/15 has become accelerated, so that it now becomes palpable within 17 to 21 days following

inoculation and kills the host in from 4 to 6 months. In December 1954, the tumor was in its 98th transplant generation. No metastases have ever been found in any mice carrying transplants of this hepatoma.

DESCRIPTION OF CURRENT TUMOR. A 6-week-old subcutaneous transplant tumor of the 78th generation of Hepatoma 98/15 measures 1.5 cm. in diameter. It consists of confluent nodules of soft, yellowish pink tissue surrounded by a capsule. The surrounding tissue is compressed, and the tumor is supplied by numerous thin-walled blood vessels. On section, there are multiple cystic areas, some showing papillary formation.

Microscopically, the thin connective tissue capsule shows a mild inflammatory reaction and numerous dilated blood vessels (fig. 160). Aside from a few scattered areas of necrosis, the tumor tissue is well preserved. The histologic pattern resembles that of hepatic tissue with alternating cords of cells and sinusoidal vessels, but there is no lobule formation. The thickness of the cords and the width of the sinusoids vary in different areas (fig. 161). Occasionally, a central sinusoid is surrounded by a narrow cuff of viable tumor tissue beyond which the tissue is necrotic. There are microcysts of varying size, sometimes empty, sometimes containing granular acidophilic material or blood, and occasionally there are papillary structures. There is only a small amount of stroma, and it consists chiefly of reticular fibers that are concentrated in the region of the vessels and along the borders of the cords of neoplastic cells.

The tumor cell may be round, oval, polygonal, angular, elongated, or stellate and measures 7 to 80 microns in diameter (fig. 162). The cytoplasm is basophilic, sometimes finely or coarsely vacuolated, and contains basophilic granules and threadlike structures. Round hyaline bodies staining like those of the primary tumor are present. The nuclei vary in size as do the cells. The smallest nuclei have a heavily stained nuclear membrane containing one basophilic nucleolus and fine chromatin granules dispersed on the linin network (fig. 163). Nuclei of intermediate size may be round, indented, or elongated, and contain as many as five basophilic nucleoli. The largest nuclei, which are least numerous, are deeply hyperchromatic. In addition to basophilic nucleoli, they contain one to several round acidophilic inclusions surrounded by a deeply stained basophilic membrane. A large intranuclear vacuole is sometimes present, and the remaining nuclear structures appear to be degenerated and compressed between the vacuole and the nuclear membrane. Only one mitotic figure could be found in 6 to 10 high power fields.

Approximately 50 percent of the cells of Hepatoma 98/15 contain deep reddish purple granular cytoplasmic material as seen with the periodic acid—Schiff reaction. Almost all of the red-purple color can be removed by diastase and is therefore presumably glycogen. The vacuoles of some of the nuclei also contain periodic acid—Schiff-positive material. Frozen sections stained with Sudan IV reveal large numbers of fine granules or solitary globules of

HEPATOMA 98/15. MOUSE

(Animal bearing transplant tumor courtesy of Dr. A. J. Dalton, National Cancer Institute, Bethesda, Md.)

Figure 158.* Photomicrograph of original tumor. The primary growth has the structure of a well differentiated hepatoma with cords of epithelial cells alternating regularly with endothelial-lined blood sinuses of varying diameter. Hematoxylin and eosin stain. X 210. N. C. I. 4751; A. F. I. P. Acc. No. 219934–159.

Figure 159.* Photomicrograph of original tumor. The epithelial cells have a striking resemblance to hepatic parenchymal cells with well-defined cytoplasmic membranes, granular cytoplasm, and relatively large vesicular nuclei containing 1 to 3 large, prominent, basophilic nucleoli. Hematoxylin and eosin stain. X 1760. N. C. I. 4748; A. F. I. P. Acc. No. 219934–160.

Figure 160. Photomicrograph of 78th generation transplant tumor showing a solid area of the tumor. The tumor is surrounded by a capsule of connective tissue. Hematoxylin and eosin stain. X 80. N. C. I. 9201; A. F. I. P. Acc. No. 219934–161.

Figure 161. Photomicrograph of 78th generation transplant tumor. Another area of the tumor composed of dilated sinusoids and thick cords of hepatic cells. The capsule may be seen below. Hematoxylin and eosin stain. X 90. N. C. I. 7495; A. F. I. P. Acc. No. 219934–162.

---

* From Edwards, J. E., Dalton, A. J., and Andervont, H. B. Pathology of a transplantable spontaneous hepatoma in a C3H mouse. J. Nat. Cancer Inst., 2:555–563, 1941–42. Figures 158 and 159 are taken from figure 1, A and B.

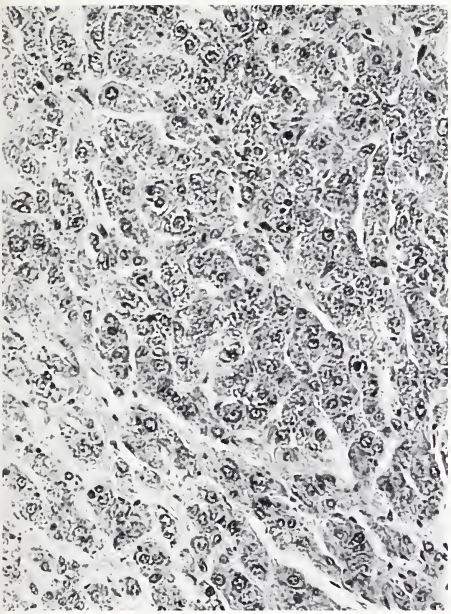

Fig. 158

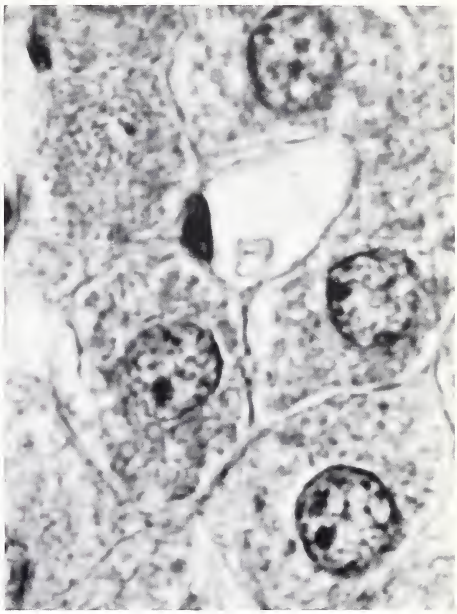

Fig. 159

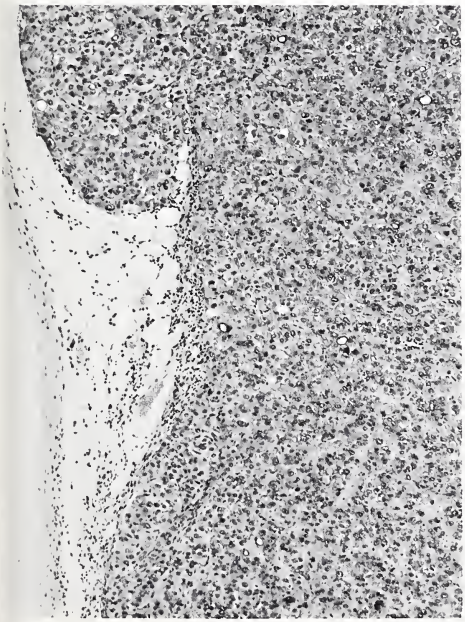

Fig. 160

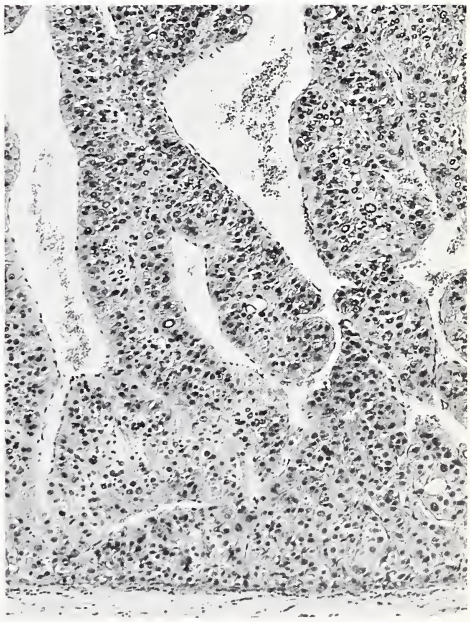

Fig. 161

HEPATOMA 98/15. MOUSE

Figure 162. Photomicrograph of 78th generation transplant tumor. This area of the tumor is composed of hepatic cells that vary moderately in size, shape, and staining capacity. Some cells have vacuoles in the cytoplasm and in the nucleus. The sinusoidal structures between the cords of hepatic cells are compressed. Hematoxylin and eosin stain. X 235. N. C. I. 9247; A. F. I. P. Acc. No. 219934–163.

Figure 163. Photomicrograph of 78th generation transplant tumor showing a cordlike structure of neoplastic cells. Note the endothelial cell lining of the sinusoid above. Hematoxylin and eosin stain. X 900. N. C. I. 7497; A. F. I. P. Acc. No. 219934–164.

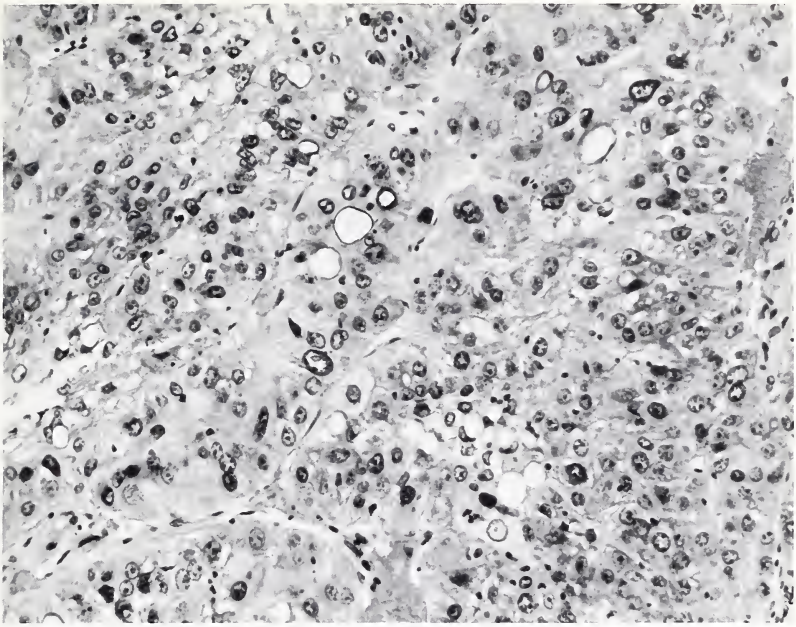

Fig. 162

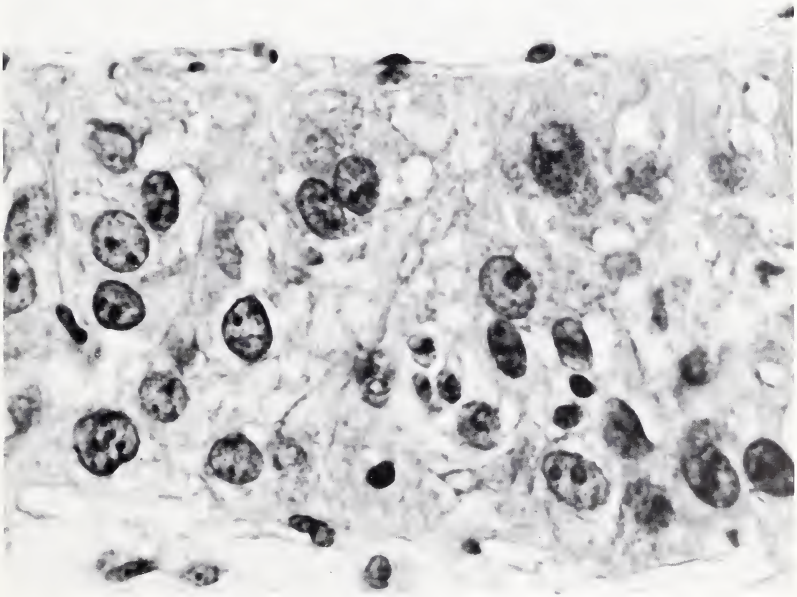

Fig. 163

lipoidal material. Both the lipoidal material and the glycogen are concentrated most heavily in the cells that border the sinusoids. Much lipoidal material can be found in the areas of necrosis.

Various studies have been concerned with the **transplantation of other hepatomas.** Andervont and Dunn (1952) described the morphologic and transplantation characteristics of primary hepatic tumors of the mouse including those that were spontaneous and those induced by o-aminoazotoluene, 3:4:5:6-dibenzcarbazole, and carbon tetrachloride. They found that the primary tumors of the liver that were most atypical in histologic structure were those induced by o-aminoazotoluene. Hepatomas induced by carbon tetrachloride resembled normal hepatic tissue even more closely than did the spontaneous hepatomas. In this experiment, pieces from 81 primary tumors of the liver were inoculated subcutaneously into mice of the same strain as the animal in which the given tumor arose. The three hepatomas induced with 3:4:5:6-dibenzcarbazole and the eight induced with carbon tetrachloride failed to grow in transplant. Thirteen of 19 hepatomas that arose spontaneously in C3H male mice were transplantable. Of 51 primary hepatomas induced with o-aminoazotoluene, 23 grew in transplant. The latent period of transplantation varied within wide limits. During the first few generations, 12 months were frequently required for the tumor to reach a diameter of 1.0 cm., while succeeding generations were usually transplantable within 2 to 10 weeks following inoculation. As in the case of other tumors described in this fascicle, the tumors that grew at the site of inoculation of several of the hepatomas that were serially transplanted differed in histologic structure from that of the original tumor. The final histologic status of 10 of the hepatomas was as follows: an osteogenic sarcoma, a reticulum cell sarcoma, a cholangioma, an unclassified form of carcinoma, and six hemangioendotheliomas. All of the hemangioendotheliomas developed at the site of inoculation of hepatomas induced by o-aminoazotoluene in strain BALB/c mice. Once this change had taken place, the tumors did not revert to their original hepatomatous pattern.

References

Andervont, H. B. Studies on the occurrence of spontaneous hepatomas in mice of strains C3H and CBA. J. Nat. Cancer Inst., 11:581–592, 1950.

_____, and Dunn, T. B. Transplantation of spontaneous and induced hepatomas in inbred mice. J. Nat. Cancer Inst., 13:455–503, 1952.

_____, and Dunn, T. B. Transplantation of hepatomas in mice. J. Nat. Cancer Inst. (suppl.), 15:1513–1524, 1955.

_____, Grady. H. G., and Edwards, J. E. Induction of hepatic lesions, hepatomas, pulmonary tumors, and hemangio-endotheliomas in mice with o-aminoazotoluene. J. Nat. Cancer Inst., 3:131–153, 1942.

Burns, E. L., and Schenken, J. R. Spontaneous primary hepatomas in mice of strain C3H. A study of incidence, sex distribution and morbid anatomy. Am. J. Cancer, 39:25–35, 1940.

Edwards, J. E., and Dalton, A. J. Induction of cirrhosis of the liver and of hepatomas in mice with carbon tetrachloride. J. Nat. Cancer Inst., 3:19–41, 1942.

_____, Dalton, A. J., and Andervont, H. B. Pathology of a transplantable spontaneous hepatoma in a C3H mouse. J. Nat. Cancer Inst., 2:555–563, 1942.

Gorer, P. A. The incidence of tumours of the liver and other organs in a pure line of mice (Strong's CBA strain). J. Path. & Bact., 50:17–24, 1940.

Lippincott, S. W., Edwards, J. E., Grady, H. G., and Stewart, H. L. A review of some spontaneous neoplasms in mice. J. Nat. Cancer Inst., 3:199–210, 1942.

Miyaji, T. Some observations on the volume of the nucleus of spontaneous hepatomas in mice. J. Nat. Cancer Inst., 13:627–645, 1952.

TUMORS OF THE KIDNEY

Renal Adenocarcinoma. Frog

DEFINITION. An adenocarcinoma that arises spontaneously in the kidney of the leopard frog.

HISTORY AND DESCRIPTION. Spontaneous renal adenocarcinomas were first observed by Balduin Lucké in 1932 in about 2 percent of the leopard frogs (Rana pipiens) used by students working in the laboratories of physiology and pharmacology at the University of Pennsylvania in Philadelphia. The tumor was found to be more than twice as frequent in males as in females. Following Lucké's initial observation, which was published in 1934, he and his associates worked intensively with this tumor for many years. They described the renal adenocarcinoma as ivory-white and generally somewhat firmer in consistency than the surrounding renal tissue. The tumors ranged in size from tiny nodules to large masses that had destroyed all but small portions of the kidney, displacing the neighboring organs and nearly filling the abdominal cavity (pl. III). Although such large tumors were found to be common, the mean diameter, in unselected series of naturally occurring tumors, was 4 to 6 mm.; that is, approximately one-third to one-half the size of the normal kidney. About half of the tumors were found to be solitary and the other half multiple.

Metastasis often occurred when the tumors were unusually large, and this process was apparently accelerated in well fed frogs. While metastatic growths were more frequent in the liver and lungs, they were also observed in various other locations such as the peritoneum, ovaries, pancreas, urinary bladder, and retroperitoneal tissues. The temperature of the environment also evidently influenced metastasis. Lucké observed metastatic growths in 54 percent of tumor-bearing frogs kept at a constant high temperature of 28° C. for approximately 50 days, whereas at the lower temperatures of 7° or 18° C., metastasis occurred in only 6 percent. At 28° C., the number of metastases in each frog was greater, and the growths were more widely disseminated than in frogs kept under more natural conditions of environmental temperature. The fact that the metastatic growths were of nearly equal size suggested simultaneous dissemination.

The following histologic description of the renal adenocarcinoma of the frog is based largely upon material examined at the National Cancer Institute, supplemented by reports from the literature. The tumor has a papillary glandular structure (figs. 164–166) and, although not encapsulated, is sharply de-

marcated from the surrounding kidney. Most of the acini are large and complex with numerous papillary projections; a few of them are simple and are lined by a layer of cells 2 or 3 deep. A few solid sheets of tumor cells may be found. The papillary processes vary in size and number from small single or multiple excrescences to elongated, branched, frondlike structures (fig. 167). There is a thick basement membrane to which the epithelial cells are anchored by short processes. This basement membrane has a striated appearance and is bright purplish red with the periodic acid—Schiff reaction (fig. 168). At points of apposition with the adjacent collagenic and reticular fibers, the basement membrane exhibits a saw-toothed edge. The papillary structures of the tumor are supported by a small amount of compact stroma. In other areas the stroma is more abundant, loose, edematous, and infiltrated with inflammatory cells (fig. 169). The tumor contains a few narrow thin-walled blood vessels. Although some tumor cells are flat or cuboidal, the majority are tall and columnar. The cytoplasm is granular. The round or oval nuclei are hyperchromatic, with numerous chromatin granules and 1 or 2 prominent eosinophilic nucleoli. In some tumors, a large number of mitotic figures are found; in others, only a few. Frequently several mitotic figures may be seen in a single neoplastic tubular structure.

HISTOGENESIS. Lucké, in his first study of the Renal Adenocarcinoma, noted multiple tumors in a single kidney in a number of frogs. Since the growths were of nearly equal size, and continuity between individual tumors studied histologically in serial sections often could not be demonstrated, he thought it probable that the tumors arose from several separate foci. He described transition stages between relatively benign appearing and highly malignant looking structures. Lucké (1952, p. 1096) summarized his observations as follows:

"In a relatively small group of the tumors, the component cells are less atypical and arranged in a more orderly fashion. These growths resemble adenomas rather than adenocarcinomas. Commonly, such growths are cystic in parts, with pronounced papillary ingrowths. All gradations are found between the frankly malignant, invasive and destructive adenocarcinoma and the structurally benign adenoma, cystadenoma and papillary cystadenoma. In general, the larger tumors have a malignant appearance, although many of the minute nodules are also obviously carcinomatous. . . . It is probable that all these tumors are at least potentially cancerous and that they go through evolutionary phases in their progress toward ultimate malignancy."

Virus etiology and transplantation studies. The question whether the renal adenocarcinoma of the frog is caused by a virus has been debated for more than twenty years. Fawcett recently described particles in the nucleus and cytoplasm of tumor cells and also outside the cells as revealed by electron micrographs of the frog tumor. These particles were of two types, and he regarded one or both of them as the tumor agent. He noted a similarity

PLATE III

RENAL ADENOCARCINOMA. FROG

A. Gross photograph of a solitary spontaneous tumor in the right kidney of a male frog. A cyst is present in the left kidney. The gastrointestinal tract has been removed and the paired testicles are visible above the tumor. N. C. I. H2121; A. F. I. P. Acc. No. 219934–296.

B. Gross photograph of bilateral spontaneous tumors in a female frog. A portion of the intestine has been removed. The coiled oviducts lie below the kidneys, and the ovaries occupy the upper coelom. N. C. I. H8122; A. F. I. P. Acc. No. 219934–297.

C. Gross photograph of kidneys seen in figure A. The dissected kidneys show the solitary tumor nodule of the right kidney. The adrenal gland is represented by the longitudinal orange streak on each kidney. N. C. I. H2121; A. F. I. P. Acc. No. 219934—298.

D. Gross photograph of bilateral renal tumors seen in figure B. Note remnant of kidney at the lower margin of each tumor. N. C. I. H8122; A. F. I. P. Acc. No. 219934–299.

A

B

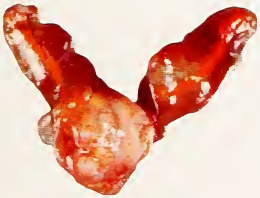

C

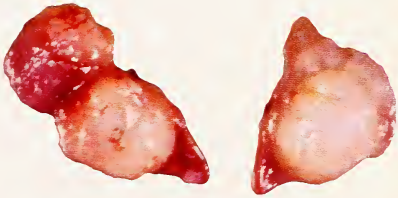

D

Plate III

between one type of particle and the virus of herpes simplex. Much earlier, Lucké had described what he considered to be an eosinophilic nuclear inclusion body, indicating to him that the tumor was caused by a virus. In histologic material examined at the National Cancer Institute, the apparently healthy tumor cell contains an eosinophilic nucleolus. In degenerated cells in our material, the nucleolus fragmentizes, and the parts stain even more intensely red in the hematoxylin and eosin preparation than does the intact nucleolus. An examination of Lucké's illustrations and descriptions of the tumor cells containing what he regarded as nuclear inclusions leaves little doubt that such cells were degenerated and necrotic. A question might be raised therefore whether the eosinophilic objects regarded by Lucké as inclusion bodies could be merely fragmented nucleoli of degenerated cells.

When Lucké injected pieces of the renal tumor into the kidney and eye of other frogs, local tumor growth ensued. About 75 percent of the intraocular transplants became established, and about half of them grew to such size that they completely filled the anterior chamber. Lucké and Schlumberger studied the progressive growth of these transplants using the slit lamp microscope and described three distinct patterns of growth: membranous, invasive acinar, and tubulopapillary. Once established in the eye, the tumors could then be transplanted serially into the eyes of other frogs for a number of generations.

Briggs transplanted Renal Adenocarcinoma into 163 tadpoles and found that the larval environment neither inhibited the growth nor altered the structure of the implanted tumor. The transplants developed into growing tumors in the subcutaneous tissue of the trunk in 17 percent of tadpoles, in the dorsal tail fin in 50 percent, in the perirenal tissue in 8 percent, in the liver in 5 percent, and in the body cavity in 5 percent. Six of the hosts which had completed metamorphosis and which had failed to develop a tumor at the site of inoculation (liver, body cavity, or tissues adjacent to the kidneys) had multiple tumors in the kidneys.

Fresh, glycerolated, or desiccated tumor tissue inoculated by Lucké into the muscles of the thigh, the peritoneal cavity, the liver, the brain, or the lymph sacs of frogs, underwent resorption, and no tumors developed at these sites of inoculation. However, after six months, there was a higher than expected incidence of renal tumors in frogs of all of these groups except those inoculated by the intramuscular route. From these observations, Lucké concluded that he was dealing with a viral agent, organotropic for the kidney. The virus etiology of the frog tumor has also been accepted by other investigators. Tweedell reported that he induced tumors in the kidney of Rana pipiens from both Vermont and Wisconsin by the intraocular inoculation of renal carcinomatous tissue. Rose serially transplanted renal carcinomatous tissue from a frog into newts and other frogs and induced what he regarded as neoplastic lesions histologically different from the original tumor and at sites other than

the kidney in both species. Rose believed that an agent from the renal carcinoma of the frog could be modified by passage through salamanders and would thereafter induce these extrarenal types of growth. Duryee described atypical masses of desoxyribonucleic acid (Feulgen-positive), that resemble the inclusion bodies of virus-infected tissues, in the nucleoli of spontaneous adenocarcinomas of the kidney of the frog, as well as in the cells of the kidney, following injection into the kidney of cell-free filtrates of the renal tumor. He also found these bodies in the cells of the renal tumor cultures in vitro. He believed that the intranuclear inclusion body gave rise to similar cytoplasmic bodies by extrusion of them from the nucleus in living cells.

The concept that the frog tumor is caused by a virus has not been accepted in all quarters. Some investigators feel that the results obtained so far would be more acceptable and more valid had procedures like those used in experiments with mice been observed. When dealing with a type of growth that may vary from a single atypical tubule lined with hyperplastic cells that may or may not be the first manifestation of carcinoma of the kidney to a massive renal tumor that has metastasized, criteria for the diagnosis of tumor must be established and kept constant in all experiments. Since the incidence and growth of the renal tumor may be affected by the age, sex, and geographic source of the frog, its diet and state of nutrition and the environmental temperature, it is important to control these factors in experiments with this tumor. A colony of laboratory-bred frogs sacrificed at stated intervals has not to our knowledge been used in determining the incidence of spontaneous renal tumors. In such a colony, the incidence of this tumor could be more accurately determined than by the present method of examining frogs of unknown age selected from swamps and ponds by animal dealers. Indeed, it has been suggested that the location and amount of sewage in a particular pond may affect the tumor incidence of its inhabitants, and dealers in frogs have been known to select and supply them to laboratories on the basis of the presence or absence of a palpable intra-abdominal tumor. It is difficult to assess the role of a virus as the etiologic agent of the frog carcinoma until carefully controlled experiments, such as those suggested, have been carried out.

References

Briggs, R. Transplantation of kidney carcinoma from adult frogs to tadpoles. Cancer Research, 2:309–323, 1942.

Duryee, W. R. Precancer cells in amphibian adenocarcinoma. In: Cancer Cytology and Cytochemistry. Ann. New York Acad. Sc., 63 (art. 6):1280–1302, 1956.

Fawcett, D. W. The cytopathology of the Lucké renal carcinoma of Rana pipiens studied with the electron microscope. Anat. Rec., 122:488, 1955.

Lucké, B. A neoplastic disease of the kidney of the frog, Rana pipiens. Am. J. Cancer, 20:352–379, 1934.

———. Kidney carcinoma in the leopard frog: a virus tumor. In: Viruses as Causative Agents in Cancer. Ann. New York Acad. Sc., 54 (art. 6):1093–1109, 1952.

———, and Schlumberger, H. The manner of growth of frog carcinoma, studied by direct microscopic examination of living intraocular transplants. J. Exper. Med., 70:257–268, 1939.

———, and Schlumberger, H. Induction of metastasis of frog carcinoma by increase of environmental temperature. J. Exper. Med., 89:269–278, 1949.

Rose, S. M. Interaction of tumor agents and normal cellular components in amphibia. In: Viruses as Causative Agents in Cancer. Ann. New York Acad. Sc., 54 (art. 6):1110–1119, 1952.

Tweedell, K. S. Adaptation of an amphibian renal carcinoma in kindred races. Cancer Research, 15:410–418, 1955.

RENAL ADENOCARCINOMA. FROG

(Histologic sections courtesy of Dr. Joseph Leighton, Pittsburgh, Pa.; formerly of National Cancer Institute, Bethesda, Md.)

Figure 164. Section of spontaneous tumor in the kidney of a frog showing the papillary glandular structure. The tumor is sharply demarcated from the surrounding renal tissue. Hematoxylin and eosin stain. X 60. N. C. I. 7869; A. F. I. P. Acc. No. 219934–165.

Figure 165. Section of spontaneous tumor in the kidney of a frog. The papillary projections of the tumor are supported by a small amount of connective tissue stroma. With this stain the basement membrane is not colored. Compare with figure 168. Van Gieson stain. X 210. N. C. I. 7866; A. F. I. P. Acc. No. 219934–166.

Figure 166. Section of spontaneous tumor in the kidney of a frog showing a small focus of tumor in the cortex of the kidney. Some distance from this focus there is a larger tumor mass. This small focus may represent either a tumor developing at a new site or an extension of the large tumor. Hematoxylin and eosin stain. X 230. N. C. I. 7867; A. F. I. P. Acc. No. 219934–167.

Fig. 164

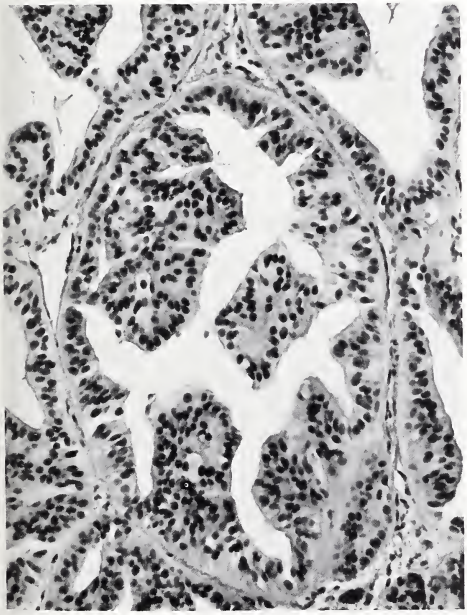

Fig. 165

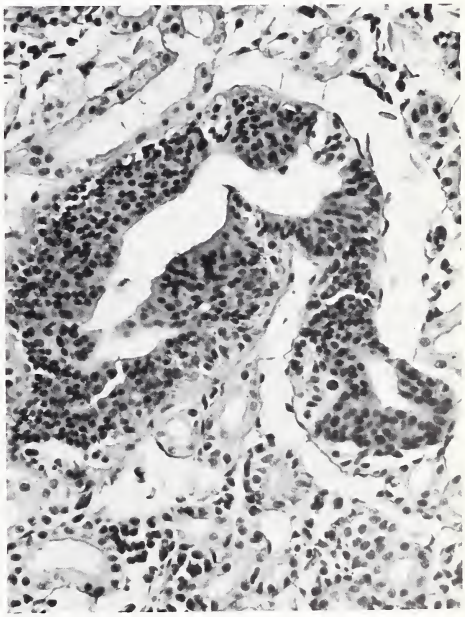

Fig. 166

RENAL ADENOCARCINOMA. FROG

Figure 167. Section of spontaneous tumor in the kidney of a frog showing the histologic pattern and cellular detail of one of the papillary processes. Hematoxylin and eosin stain. X 640. N. C. I. 7844; A. F. I. P. Acc. No. 219934–168.

Figure 168. Section of spontaneous tumor in the kidney of a frog showing the wall of a ductlike structure with a distinctly colored basement membrane. Periodic acid—Schiff reaction. X 830. N. C. I. 7846; A. F. I. P. Acc. No. 219934–169.

Figure 169. Section of spontaneous tumor in the kidney of a frog showing the character and number of reticular fibers in the tumor and their relationship to the neoplastic cells. Wilder's silver preparation. X 680. N. C. I. 7847; A. F. I. P. Acc. No. 219934–170.

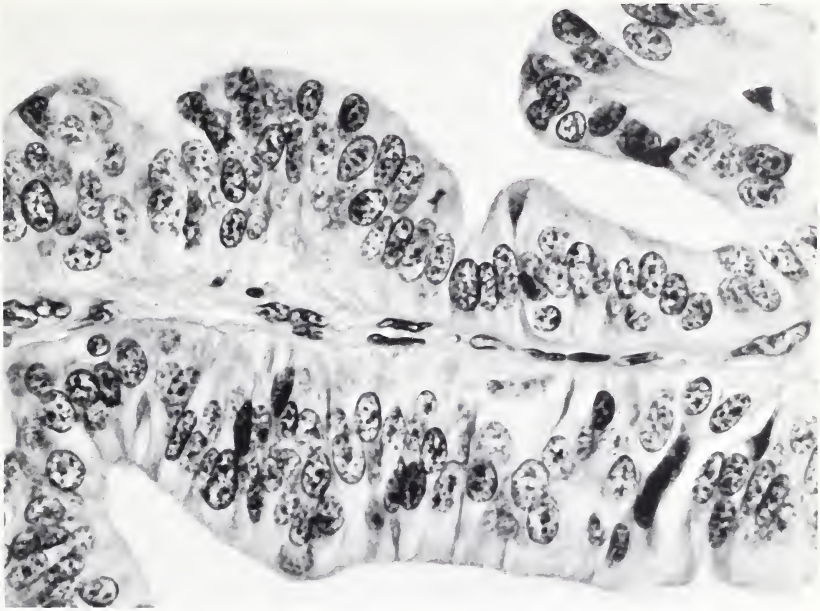

Fig. 167

Fig. 168

Fig. 169

TUMORS OF THE REPRODUCTIVE ORGANS

TUMORS OF THE TESTIS

Leydig-cell Tumor (Furth). Mouse

SYNONYM: Interstitial cell testicular tumor of the mouse.

DEFINITION. A spontaneous malignant tumor of the interstitial cells of the testis of a RF/Fu strain mouse.

HISTORY AND DESCRIPTION OF ORIGINAL TUMOR. The Leydig-cell Tumor was found in a 17-month-old untreated mouse of the RF/Fu strain in 1951 in the laboratory of Jacob Furth at Oak Ridge National Laboratory, Oak Ridge, Tennessee. At necropsy, a soft tumor mass, 1.5 cm. in diameter, was present in the right testicle. The tumor was yellow or pinkish yellow and glistening. Metastatic growths were found in the intra-abdominal lymph nodes.

Microscopically, the bulk of the tumor taken for sectioning was found to be necrotic. The few tumor cells that survived were located around the blood vessels. An intra-abdominal lymph node was almost completely replaced by tumor tissue. Furth stated that the appearance of the neoplastic cells in both the primary and the metastatic tumor was similar in general to that of the transplanted tumor.

TRANSPLANTATION STUDIES. In the first passage, transplantation was successful in 5 of 14 mice of the homologous strain RF/Fu inoculated with the tumor. In the early transplant generations, the tumor transplants grew successfully in from 10 to 50 percent of the hosts. The tumor became palpable 30 to 65 days after transplantation. It grew slowly and killed the host within 120 to 240 days. Exsanguinating hemorrhage in the vicinity of the aorta was often the apparent cause of death. After three years of serial transplantation, the tumor grew in approximately 75 percent of host mice inoculated, the latent period had become somewhat reduced, and the animal died earlier. The tumor is now transplanted at intervals of two months.

DESCRIPTION OF CURRENT TUMOR. A 4-month-old transplant tumor measures about 3 cm. in diameter. It is yellowish brown with areas of necrosis and hemorrhage. The transplanted tumor has an incomplete capsule of connective tissue that reveals a minimal inflammatory reaction. The tumor invades the adjacent areolar tissue and skeletal muscle of the host (fig. 170). About half of the transplant is composed of necrotic and hemorrhagic areas, within and around which are found pigment-containing macrophages, inflammatory cells, and clumps of bacteria that indicate infection of the tumor.

The tumor tissue is divided into large irregular compartments separated by connective tissue septa that are continuous with the capsule. The septa contain thin-walled dilated blood vessels and numerous macrophages filled with pigment that is periodic acid—Schiff-positive. Small foci of myeloid cells and scattered mast cells are present. The pattern is that of cords and sheets of neoplastic cells surrounded by reticular and collagenic fibers in which fibroblasts and numerous sinusoidal and capillary-like blood vessels may be found (fig. 171). Near the capsule, the reticulum surrounds almost every tumor cell. Deep within the tumor the reticular fibers are sparse; they may even be absent in relatively large areas (fig. 172).

The tumor cell is large and irregular in shape; most frequently it is polygonal (fig. 173). The nucleus occupies roughly one third of the volume of the cell and is round, oval, or kidney shaped. It may be indented at several points. The nuclear membrane is a sharply etched thin line enclosing finely granular chromatin. The chromatin granules may be evenly distributed, or they may be aligned against the nuclear membrane. There are often 1 or 2 basophilic nucleoli and sometimes a large round nuclear inclusion. One mitotic figure may be found in every three or four oil immersion fields. The cytoplasm is acidophilic, granular, and often finely vacuolated. It sometimes contains faint light brown pigment. The average diameter of the tumor cells is 30 microns, but varies between 15 and 60 microns.

A frozen section stained with Sudan IV reveals numerous tiny globules and granules of lipoidal material in the cytoplasm of viable tumor cells and in macrophages. In the large areas of necrosis, there are considerable quantities of stainable lipoid lying free or within the ghostlike outlines of the tumor cells. Under crossed Nicol prisms, very little doubly refractile material is present, and most of this is confined to necrotic areas.

SPECIAL FEATURES. The transplanted tumor exhibits evidence of hormonal activity. Tumor-bearing mice of both sexes become obese, and the cortex of the adrenal gland undergoes atrophy. In the male tumor-bearing mouse, there may be enlargement of the kidneys, seminal vesicles, and prostate gland. Special features of this tumor not manifested by Leydig-cell tumors described by others include (1) the frequent formation of deciduomas in the greatly thickened uterine horns and (2) exsanguinating hemorrhage of unknown pathogenesis about the cardiac auricles and the aorta. After repeated transfer of the Leydig-cell Tumor of Furth, it appeared less well differentiated in form and its production of hormones diminished. Interstitial cell tumors of the testis similar to this Leydig-cell Tumor of Furth can be induced in mice with estrogens. The resulting tumors, like tumors of other hormone-sensitive tissues, at first show evidence of incomplete autonomy. However, after successive transplantation, they are capable of metastasizing and killing the host. (Data on the original tumor, transplantation, and special features were kindly contributed by Dr. Jacob Furth of the Children's Cancer Research Foundation, Boston, Mass.)

LEYDIG-CELL TUMOR (FURTH). MOUSE

(Fixed tissue courtesy of Dr. Jacob Furth, Children's Cancer Research Foundation, Boston, Mass.)

Figure 170. Photomicrograph of transplant tumor. The periphery of the tumor shows invasion of skeletal muscle. A large part of the tumor is hemorrhagic and necrotic. Hematoxylin and eosin stain. X 46. N. C. I. 8727; A. F. I. P. Acc. No. 219934–171.

Figure 171. Photomicrograph of transplant tumor. The tumor is exceedingly cellular, and the cells are arranged in large sheets with only a small amount of stroma. Hematoxylin and eosin stain. X 430. N. C. I. 8785; A. F. I. P. Acc. No. 219934–172.

Figure 172. Photomicrograph of transplant tumor showing the distribution of the small amount of reticulum in an area of the tumor at some distance from the capsule. Wilder's silver preparation. X 565. N. C. I. 8788; A. F. I. P. Acc. No. 219934–173.

Figure 173. Photomicrograph of transplant tumor showing the character of the neoplastic cells. Hematoxylin and eosin stain. X 1050. N. C. I. 8784; A. F. I. P. Acc. No. 219934–174.

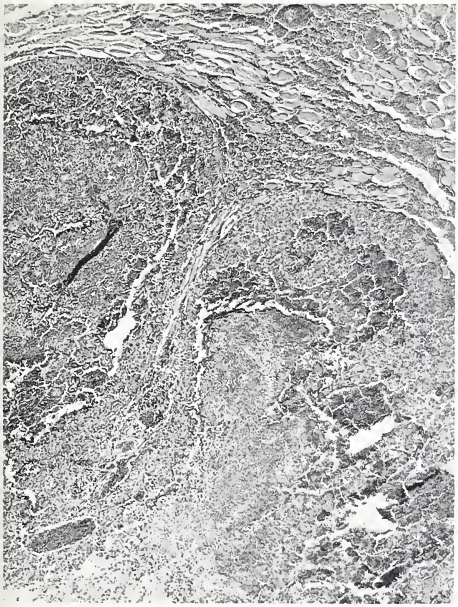

Fig. 170

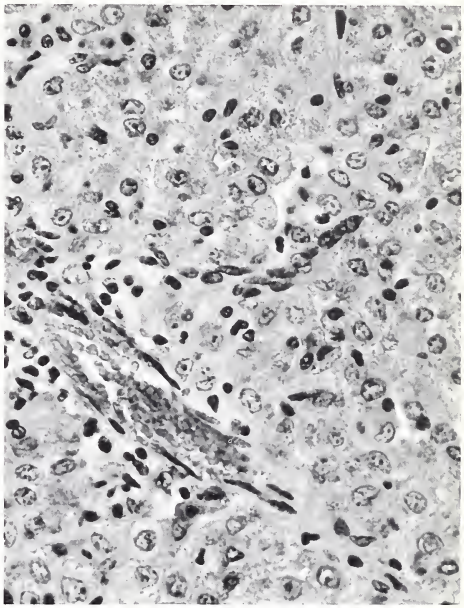

Fig. 171

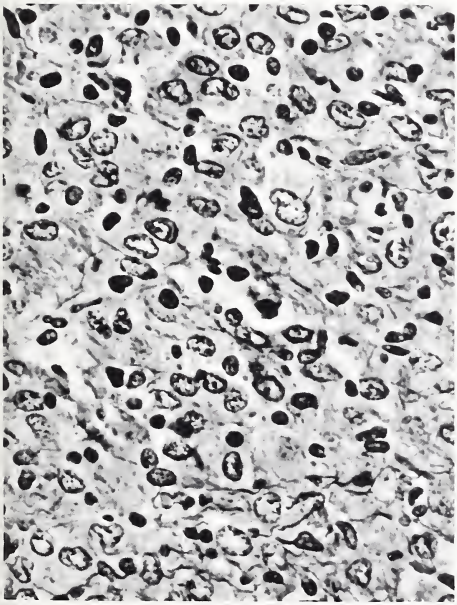

Fig. 172

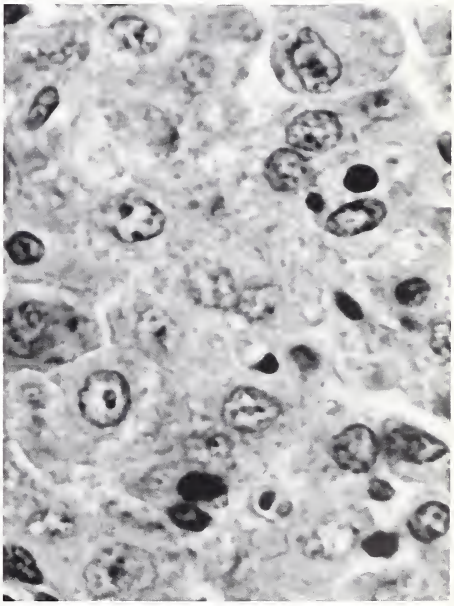

Fig. 173

References

Angevine, D. M., and Furth, J. A fatal disease of middle-aged mice characterized by myocarditis associated with hemorrhage in the pleural cavity. Am. J. Path., 19:187–195, 1943.

Bonser, G. M. Mammary and testicular tumours in male mice of various strains following oestrogen treatment. J. Path. & Bact., 56:15–26, 1944.

Firminger, H. I. Testicular tumors. In: Homburger, F., and Fishman, W. H. (eds.). The Physiopathology of Cancer, pp. 149–164. New York: Paul B. Hoeber, Inc., 1953.

TUMORS OF THE OVARY

Granulosa-cell Tumor XIV. Mouse

DEFINITION. A granulosa cell tumor that arose in the ovary of an RF x AK mouse following total body irradiation.

HISTORY AND DESCRIPTION OF ORIGINAL TUMOR. Furth, in 1947, found bilateral ovarian tumors in a 30½-month-old RF x AK hybrid mouse that had been exposed at 47 days of age to a single dose of total body roentgen ray irradiation (87 r) and had developed myeloid leukemia. The uterus was hyperplastic and the endometrium cystic. The mammary glands were lactating. The tumor of the right ovary was 12 mm. in diameter, spherical, and grayish pink. The tumor of the left ovary was 6 mm. in diameter and yellowish gray. No metastases were observed. No record of the histologic appearance of the tumors is available.

TRANSPLANTATION STUDIES. The tumor of the 1st transplant generation histologically resembled a granulosa cell tumor. Some portions of the growth were composed of masses of undifferentiated cells, follicular structures, and occasional tubular structures. These tubules were lined with a single layer of cylindrical cells, some of which were tall and showed a fibrillary structure toward the lumen. Some tumors of the 1st generation possessed an abundant stroma, which in some areas contained an intercellular substance of mucinous character. Many cells were found to resemble those of the theca externa. In the 2nd transplant generation, a cross section of the tumor had the appearance of watered silk. In subsequent passages, the tumor retained these characteristics, one or another of the structures described being predominant. Furth described a tendency to dedifferentiation and a decrease in the amounts of hormones secreted by the tumor.

The tumor, transplanted into male or female RF x AKR hybrid mice 2 to 3 months of age, at first grew better in gonadectomized mice. In later transplant generations, it grew successfully in 50 to 75 percent of intact mice of either sex and measured 22 x 14 mm., 45 days after inoculation. At present, the tumor is usually transplanted when it reaches a diameter of 2 or 3 cm. It usually does not invade the surrounding tissues and does not metastasize. The tumor has been successfully transplanted in the liver, spleen, skeletal muscle, subcutaneous tissue, and anterior chamber of the eye.

DESCRIPTION OF CURRENT TUMOR. Granulosa-cell Tumor XIV is gray and soft. Areas of necrosis are common in tumors that exceed 2 cm. in diameter. The tumor is coarsely lobulated, and the thick interlobular trabeculae of stroma frequently contain large nerves, blood vessels, and skeletal muscle fibers of the host (fig. 174). Small round cells and pigmented phagocytes in the stroma are the only indication of an inflammatory reaction. The lobules of the tumor are composed of thick anastomosing cords of cells which, in cross section, appear as spherical masses. This pattern varies, for the tumor lobule may contain narrow cords 2 or 3 cells in thickness, small nests of 6 to 12 tumor cells, and small acini (fig. 175). Each of these histologic units is surrounded by a thin strand of reticular fibers (fig. 176). The reticular fibers are more numerous than the collagenic fibers. The tumor possesses little connective tissue stroma aside from the thick interlobular trabeculae already mentioned. Blood vessels are numerous and consist chiefly of narrow thin-walled capillaries which may form dilated sinusoidal spaces at the periphery of the growth. The capsule of connective tissue is often edematous and may contain small islands of tumor cells. Small tumors reveal little hemorrhage and necrosis, and these areas are located near the capsule.

At the periphery of a cord or a nodule of tumor cells, those cells nearest the enveloping reticulum are generally cuboidal or columnar, whereas the remaining cells are round (fig. 177). The tumor cell possesses a small round or oval nucleus with a sharply outlined nuclear membrane. The nucleus contains small chromatin particles aligned against its nuclear membrane. A fine linin network radiates from one central nucleolus. One mitotic figure may be found in every two high power fields.

The cytoplasm of the cuboidal and columnar cells is faintly eosinophilic and granular with an indistinct cytoplasmic membrane. The more centrally placed round or oval tumor cells are loosely arranged and sometimes appear to be degenerated.

SPECIAL FEATURES. Mice bearing the tumor grafts may exhibit an oligocythemic hypervolemia. Tumor-bearing female mice are continually in estrus, and the endometrium of the uterus is hyperplastic, revealing the estrogenic effect of the tumor. The seminal vesicles and testes of tumor-bearing male mice are atrophied. However, not all tumor-bearing hosts exhibit these alterations. It is possible for a tumor-bearing animal to exhibit both hypervolemia and the effects of estrogenic stimulation, or one or the other of these features may be manifested independently. (Data on the original tumor, transplantation characteristics, and special features were kindly contributed by Dr. Jacob Furth of the Children's Cancer Research Foundation, Boston, Mass.)

References

Bali, T., and Furth, J. Morphological and biological characteristics of x-ray induced transplantable ovarian tumors. Cancer Research, 9:449–472, 1949.

GRANULOSA CELL TUMOR XIV. MOUSE

(Fixed tissue courtesy of Dr. Jacob Furth, Children's Cancer Research Foundation, Boston, Mass.)

Figure 174. Photomicrograph of transplant tumor. The tumor has a coarsely lobulated appearance, being divided into large compartments by thick trabeculae of stroma. A cross section of a nerve may be seen in the center of the illustration. Hematoxylin and eosin stain. X 70. N. C. I. 8332; A. F. I. P. Acc. No. 219934-175.

Figure 175. Photomicrograph of transplant tumor. This area consists of spherical masses and of cords and nests of tumor cells. Hematoxylin and eosin stain. X 400. N. C. I. 8318; A. F. I. P. Acc. No. 219934-176.

Figure 176. Photomicrograph of transplant tumor. The cords and rounded masses of tumor cells are surrounded by delicate reticular fibrils which do not penetrate to any extent between the tumor cells. Wilder's silver preparation. X 480. N. C. I. 8327; A. F. I. P. Acc. No. 219934-177.

Figure 177. Photomicrograph of transplant tumor. At the periphery of the rounded nodule the tumor cells are cuboidal and columnar, while in the center the cells are more round. Hematoxylin and eosin stain. X 820. N. C. I. 8326; A. F. I. P. Acc. No. 219934-178.

Fig. 174

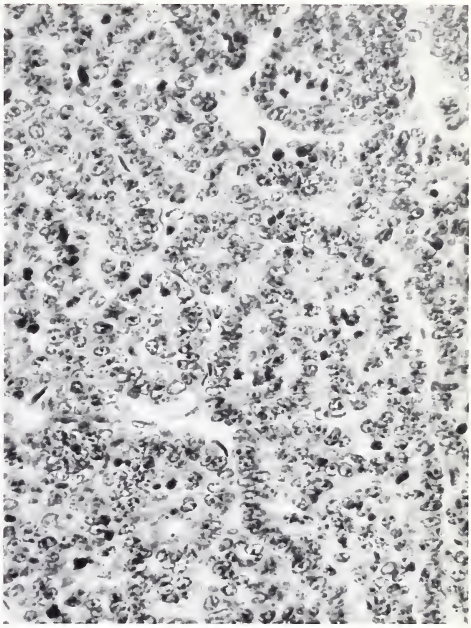

Fig. 175

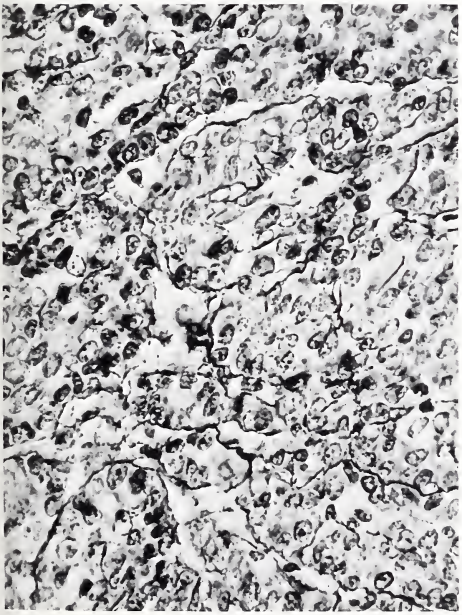

Fig. 176

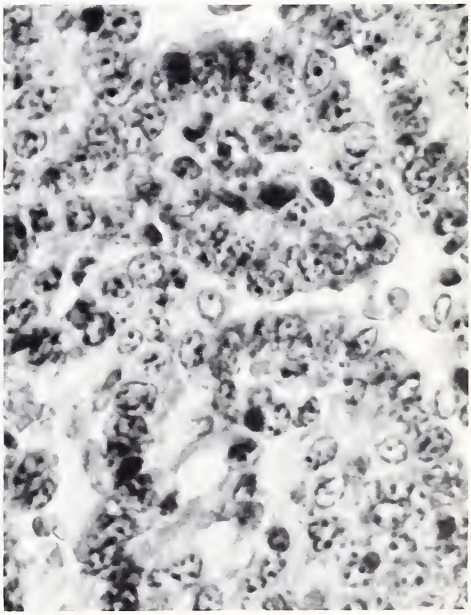

Fig. 177

Furth, J. Transplantability of induced granulosa cell tumors and of luteoma in mice. Secondary effects of these growths. Proc. Soc. Exper. Biol. & Med., 61:212–214, 1946.

_____, and Butterworth, J. S. Neoplastic diseases occurring among mice subjected to general irradiation with x-rays. II. Ovarian tumors and associated lesions. Am. J. Cancer, 28:66–95, 1936.

_____, and Sobel, H. Hypervolemia secondary to grafted granulosa-cell tumor. J. Nat. Cancer. Inst., 7:103–113, 1946.

Luteoma IX. Mouse

SYNONYM: Ovarian Tumor IX, lutein-cell type.

DEFINITION. A luteoma induced in the ovary of an RF x AKR hybrid mouse by total body irradiation.

HISTORY AND DESCRIPTION OF ORIGINAL TUMOR. Furth and Boon, in 1945, found a tumor of the left ovary of an RF x AKR hybrid mouse that had been exposed one year previously, at five weeks of age, to total body roentgen ray irradiation. One week following the exposure to roentgen rays, a 1 percent solution of 20-methylcholanthrene in benzene had been painted twice on the skin. The experiment was carried out in the laboratory of pathology at Cornell University Medical College, New York City. The tumor of the left ovary was removed at laparotomy. It was yellow, soft, and rubbery, and measured 1.8 x 1.5 cm. At the time of surgical operation, the right ovary appeared normal. The left horn of the uterus was thickened.

Furth and Sobel described the histologic appearance of the ovarian tumor and stated that the tumor was composed of cells resembling lutein cells that showed variation in the size of the nuclei and in the amount of cytoplasm. There was only a small amount of stroma between the tumor cells. Calcareous deposits were found in an area of degeneration.

TRANSPLANTATION STUDIES. Small pieces of the tumor removed at laparotomy were inoculated subcutaneously into untreated and into previously irradiated RF x AKR hybrid mice. During the first few transplant generations, tumors grew in some irradiated and in some untreated hosts of both sexes. However, the degree of success of growth of these early transplants varied from 0 to 100 percent. The latent period of tumor growth was shorter in the irradiated hosts. In subsequent generations, the tumor transplant grew successfully in 50 to 75 percent of the hosts. The latent period ranged from 20 to 80 days in untreated mice but was shorter in previously irradiated mice. Transplants once established did not regress, and the tumor-bearing animal usually died within 30 to 90 days. Transplantation of the tumor has been accomplished by intrasplenic, subcutaneous, and intramuscular inoculation into hosts two or three months of age. The transplanted tumor did not exhibit the deep yellow color of the primary growth, and microscopically it appeared to be more anaplastic. Metastases were present in the liver of some mice with intrasplenic transplants but were absent in mice with subcutaneous transplants.

DESCRIPTION OF CURRENT TUMOR. The transplanted luteoma is smooth, glistening, faintly yellow, soft, and rubbery. The capsule of the tumor is incomplete and consists of a thick bundle of fibrous connective tissue containing a few inflammatory cells and pigment-containing histiocytes. The tumor cells are arranged in small nodules surrounded by thin strands of reticular and collagenic fibers interspersed with a few fibroblasts (figs. 178, 179). The thin-walled blood vessels that lie within the stroma are sinusoidal and branched, and they may be congested. Each nodule of the tumor consists of solidly packed cells between which are a very few collagenic and reticular fibers. The cytoplasmic membrane of the tumor cell is sharply outlined. Cells that lie in apposition to each other are closely fitted together, giving the appearance of pavement epithelium. Most of the tumor cells measure about 40 microns in diameter. The nucleus generally occupies one third of the volume of the cell and is round or oval. It contains 1 or 2 round, hyperchromatic nucleoli, and rarely as many as 6. The nuclear membrane is sharply outlined and encloses fine chromatin granules. One to three mitotic figures may be found in every high power field. The cytoplasm is finely granular and acidophilic, especially in preparations of Masson's trichrome stain. The cytoplasm of the viable tumor cell contains no periodic acid—Schiff-positive material, although some of the necrotic cells are periodic acid—Schiff-positive. There are a few giant tumor cells measuring about 100 microns in diameter. Many of the nuclei of these giant tumor cells possess one enormous, round, eosinophilic inclusion. The tumor tissue is remarkably well preserved. However, isolated necrotic cells are scattered throughout the tumor, and a few small foci of necrosis and hemorrhage are present. Furth and Sobel stated that viable cells contain smaller quantities of sudanophilic lipoids than degenerated cells.

SPECIAL FEATURES. This luteoma is hormonally active and apparently secretes progesterone. Tumor-bearing mice of both sexes become obese and develop polycythemic hypervolemia. The thymus gland and the cortex of the adrenal gland both undergo atrophy. In addition, tumor-bearing female mice show hyperplasia of the uterus, enlargement of the clitoris, absence of corpora lutea, atrophy of the vaginal epithelium, and anestrus. The seminal vesicles of tumor-bearing castrated male hosts do not undergo the usual atrophy. (Data on the original tumor, transplantation characteristics, and special features were contributed by Dr. Jacob Furth of the Children's Cancer Research Foundation, Boston, Mass.)

References

Bali, T., and Furth, J. Morphological and biological characteristics of x-ray induced transplantable ovarian tumors. Cancer Research, 9:449–472, 1949.

Furth, J., and Boon, M. C. Induction of ovarian tumors in mice by x-rays. Cancer Research, 7: 241–245, 1947.

LUTEOMA IX. MOUSE

(Fixed tissue courtesy of Dr. Jacob Furth, Children's Cancer Research Foundation, Boston, Mass.)

Figure 178. Photomicrograph of transplant tumor. The tumor cells are arranged in rounded nodules that are surrounded by a few reticular fibers. Wilder's silver preparation. X 300. N. C. I. 8324; A. F. I. P. Acc. No. 219934–179.

Figure 179. Photomicrograph of transplant tumor. The tumor cells are closely packed together, and most of them are fairly uniform in size. A few giant tumor cells are present. Hematoxylin and eosin stain. X 735. N. C. I. 8328; A. F. I. P. Acc. No. 219934–180.

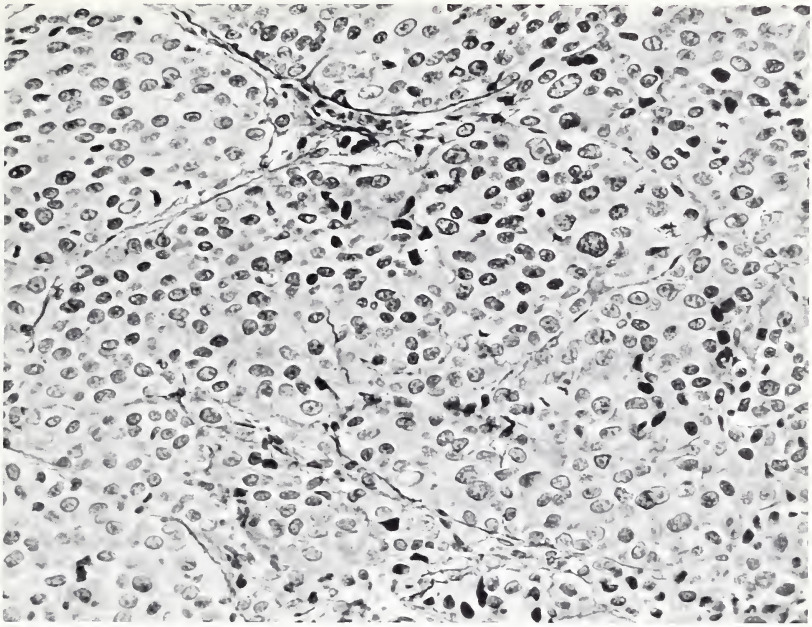

Fig. 178

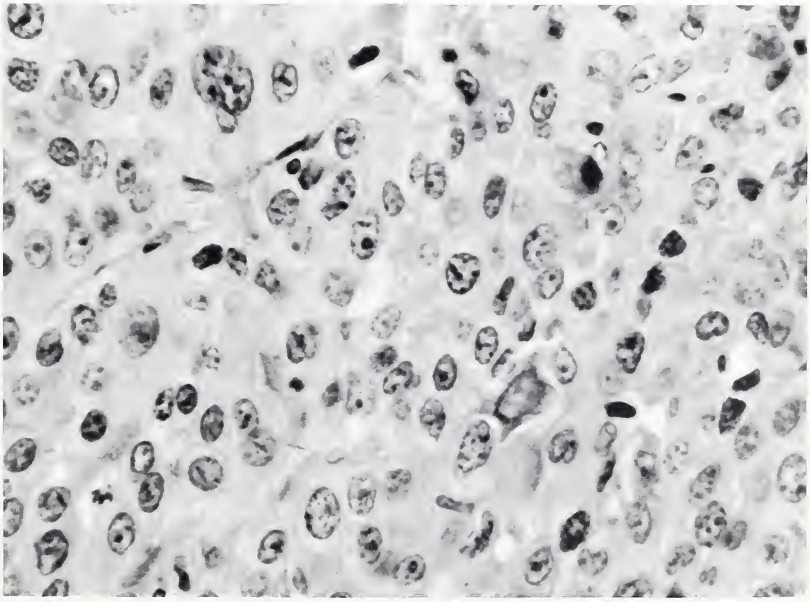

Fig. 179

———, and Butterworth, J. S. Neoplastic diseases occurring among mice subjected to general irradiation with x-rays. II. Ovarian tumors and associated lesions. Am. J. Cancer, 28:66–95, 1936.

———, and Sobel, H. Transplantable luteoma in mice and associated secondary changes. Cancer Research, 7:246–262, 1947.

Gottschalk, R. G., and Furth, J. Polycythemia with features of Cushing's syndrome produced by luteomas. Acta haemat., 5:100–123, 1951.

Li, M. H., and Gardner, W. U. Further studies on pathogenesis of ovarian tumors in mice. Cancer Research, 9:35–41, 1949.

Teratoma E6496. Mouse

DEFINITION. A tumor containing elements from the three germ layers and originating in the ovary of a mouse of the $C3H_eB$ substrain.

HISTORY AND DESCRIPTION OF ORIGINAL TUMOR. Teratoma E6496 was found in a mouse necropsied by E. Fekete on March 9, 1951, at the Roscoe B. Jackson Memorial Laboratory, Bar Harbor, Maine. Fekete and Ferrigno (p. 438) described the tumor as follows:

"The tumor occurred in a mouse of the $C3H_eB$ substrain. This line was developed by transferring ova of a mouse of the C3H inbred strain, 2 days after fertilization, into the uterus of a C57BL/6 female. The descendants of the young born to the C57BL/6 mother, and nursed by her, were continued to be inbred by brother-sister matings, and constitute the $C3H_eB$ substrain.

"The animal had a palpable abdominal tumor and was killed at the age of 216 days. The left ovary was greatly enlarged and measured approximately 10 x 15 x 20 mm. The right ovary was normal. Parts of the enlarged left ovary were fixed and prepared for sectioning, and parts of it were used for transplantation.

"Microscopic examination showed that the ovarian tumor was composed of undifferentiated 'embryonal' cells and many types of differentiated tissue. Remains of the ovary were present and contained a few atretic follicles and at least one normal follicle with ovum. Some of the undifferentiated cells were round or oval-shaped and were arranged in small nests . . . ; others showed more varied forms and were scattered irregularly. Both types revealed mitotic figures. The differentiated tissues included nervous tissue . . . , hyaline cartilage, bone, striated muscle fibers . . . , and the following kinds of epithelia: stratified squamous, cuboidal, ciliated, simple columnar, and goblet cells. These epithelial cells formed the lining of cysts of various sizes. Small groups of alveoli formed by cuboidal epithelium and occasionally surrounded by smooth muscle fibers were seen. At some areas abundant amounts of pigment granules were present in epithelial cells and in stellate cells. Mitotic figures were rare. The various tissues intermingled without evidence of organization. The tumor was designated as E6496 and was diagnosed a teratoma."

TRANSPLANTATION STUDIES. The transplant tumor grows in nearly 100 percent of mice of strains $C3H_c$, C3H, and $C3H_f$ as well as in the F_1 generation of C57BL/6 x C3H. A subcutaneous transplant of the tumor is of palpable size 7 to 9 days after inoculation and kills the host within 6 to 7 weeks. It does not metastasize. During the course of transplantation, the histologic elements in the tumor have, in general, remained the same. On July 22, 1954, the tumor was in its 32nd transplant generation at the Jackson Memorial Laboratory.

Intraperitoneal transplantation of the tumor has also been found to be successful. Using this route, generous amounts of tissue are transplanted by trocar at intervals of 3 to 4 weeks. The growth of the intraperitoneal transplant on the omentum is accompanied by the accumulation of a hemorrhagic ascitic fluid that contains freely floating tumor cells.

DESCRIPTION OF CURRENT SUBCUTANEOUS TRANSPLANT. A 60-day-old subcutaneous transplant tumor of Teratoma E6496 in the axillary region of a $C3H_f$/He mouse measures 2 x 1 x 1 cm. It is firm, lobulated, yellowish tan and on section shows varying shades of gray, black, and tan.

Single and multiple sections of subcutaneous transplants from the 14th to the 20th transplant generations have been studied histologically. There may be wide variation in the number, types, and proportion of the various cells, tissues, and structures in different transplants. Very often a transplant tumor is divided into compartments by bundles of relatively mature stroma. Each compartment may be composed of epithelial-like cells, epithelial pearls, cartilage, bone, smooth muscle, neural tissue, and melanoblasts (figs. 180–182). The tumor cells may be arranged in the form of nests, sheets, or acini. The tissue components of the tumor are embedded in a loose mesenchymal matrix that often has a myxomatous appearance.

Large amounts of osseous and cartilaginous tissue are often found in the tumor. The bone may be oriented to surround a central cavity filled with marrow composed of hematopoietic cells (fig. 183), fat, and sinusoids. The connective tissue stroma is composed of fibroblasts with associated fibroglial fibrils and variable amounts of reticulum and collagen. Mature and less differentiated smooth muscle cells with associated myoglial fibers occur in bundles in the stroma, often in relation to epithelial structures. The collagenic fibers are sometimes so thick and numerous that they may constitute as much as 50 percent of some portions of a tumor. The pattern of the collagen and reticulum varies, depending upon the different tissue elements present. Epithelial structures are usually encircled by a reticulum, the fibrils of which are also present between the malignant-appearing mesenchymal cells. No elastic fibers are observed. The blood vessels vary in number and character, but many of them are of the sinusoidal type. Some sections contain neural tissue which consists chiefly of neuroglia and rosettes of cells that resemble neural crests. Ganglionic nerve cells are rarely seen. The tumor contains structures that may resemble glandular tissue of the bronchus, intestine, sali-

TERATOMA E6496. MOUSE

(Histologic sections courtesy of Dr. A. W. Hilberg, National Cancer Institute, Bethesda, Md.; tumor-bearing animal courtesy of Dr. Joseph Leighton, Pittsburgh, Pa., formerly of National Cancer Institute, Bethesda, Md.)

Figure 180. Photomicrograph of subcutaneous transplant tumor. Glandular structures show stratification of cells. Hematoxylin and eosin stain. X 510. N. C. I. 8238; A. F. I. P. Acc. No. 219934–181.

Figure 181. Photomicrograph of subcutaneous transplant tumor showing area of bone and cartilage and a small microcyst containing keratin. Hematoxylin and eosin stain. X 210. N. C. I. 8220; A. F. I. P. Acc. No. 219934–182.

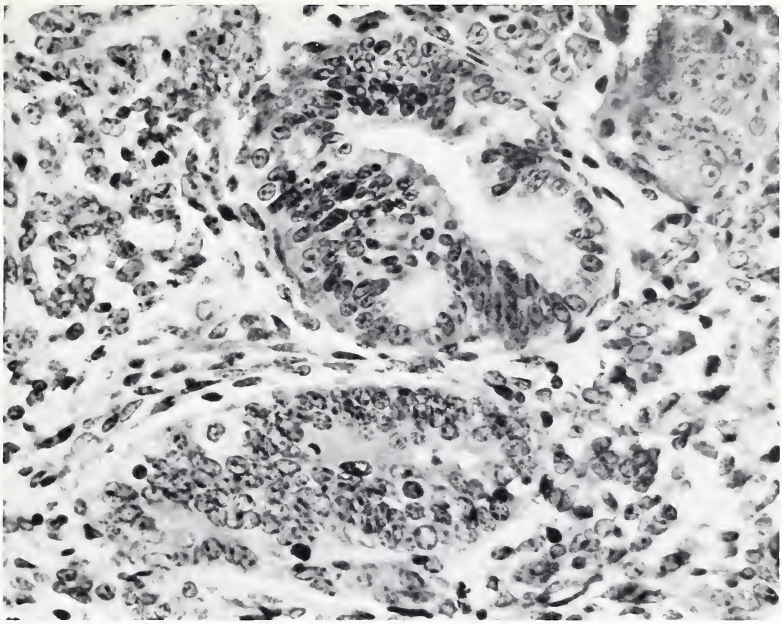

Fig. 180

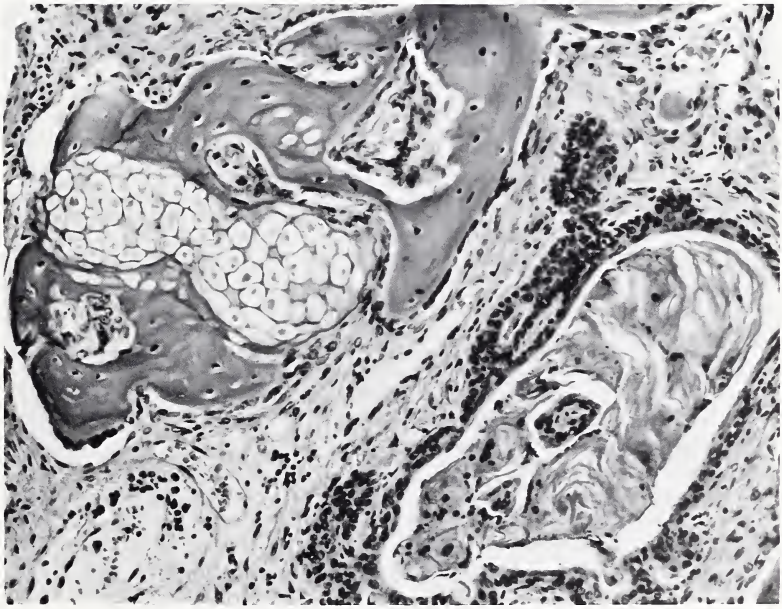

Fig. 181

TERATOMA E6496. MOUSE

Figure 182. Photomicrograph of subcutaneous transplant tumor showing area of neural tissue within the tumor. Hematoxylin and eosin stain. X 460. N. C. I. 8223; A. F. I. P. Acc. No. 219934–183.

Figure 183. Photomicrograph of subcutaneous transplant tumor showing area of bone arranged around a cavity filled with marrow cells. There are several microcysts lined with stratified squamous epithelium and containing keratin; one of these contains inflammatory cells. The stroma in this area consists of edematous fibrous tissue infiltrated with small round cells. Hematoxylin and eosin·stain. X 105. N. C. I. 8217; A. F. I. P. Acc. No. 219934–184.

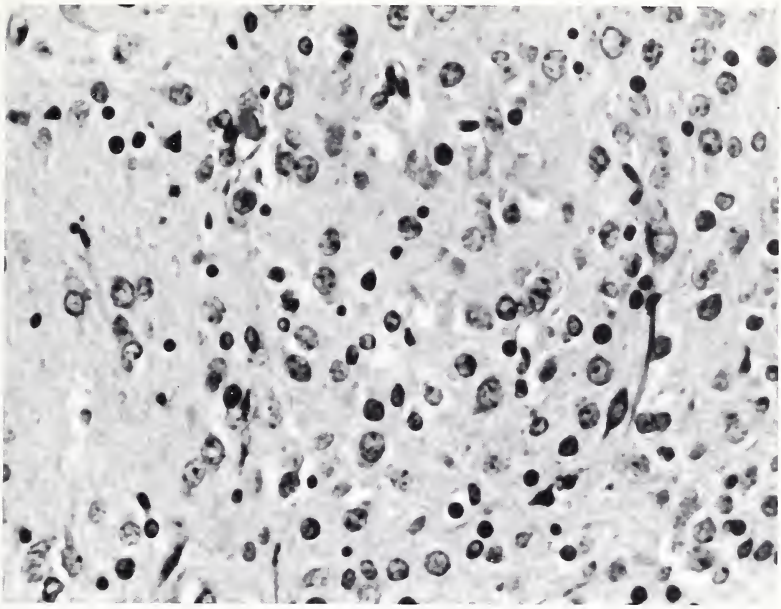

Fig. 182

Fig. 183

vary gland, or the thyroid gland. Foci of adenoacanthoma are not infrequent. Large parts of some sections are occupied by multilocular cysts. Epithelial pearls are present as solitary isolated structures in otherwise undifferentiated portions of the tumor, or they may constitute the bulk of a given area of tumor. Spidery or round melanoblasts are found to contain argentophilic pigment granules in the deep portions of the tumor where they are intermingled with other types of neoplastic cells. No structures as highly organized as the eye or skin are observed.

Skeletal muscle fibers and peripheral nerve fibers are observed in some subcutaneous transplants only. Their absence in intraperitoneal transplants suggests that they are probably of host origin when they occur in subcutaneous tumor transplants. The amount of necrotic tissue varies considerably. Some tumors are almost free of necrosis, while others may show extensive necrosis and inflammation, particularly those subcutaneous transplants that are ulcerated. The connective tissue capsule of the tumor contains in many cases small deposits of iron-containing pigment granules.

DESCRIPTION OF CURRENT INTRAPERITONEAL TRANSPLANT. Sixty days following intraperitoneal inoculation of ascitic fluid containing cells of Teratoma E6496, a $C3H_f/He$ mouse shows marked distension of the abdomen. Six cubic centimeters of serosanguineous fluid are aspirated from the peritoneal cavity. The right ovary is replaced by a dark red cyst measuring 1.0 cm. in diameter. Nodules of grayish yellow tumor tissue, measuring 1.0 to 2.0 mm. in diameter, are found infiltrating the mesentery, mesenteric lymph nodes, and parietal peritoneum.

The ascitic fluid of animals in which the intraperitoneal line of E6496 has been maintained contains a suspension of tumor cells. The composition of the solid tumor nodules growing in the ovary, mesenteric lymph nodes, and on the peritoneum resembles in general that of the subcutaneous transplant tumors, although there is less diversity of cells in the tissues.

COMPARATIVE PATHOLOGY. This tumor is not unlike the teratomas observed in man. One of the interesting features of Teratoma E6496 is that it has not metastasized despite the presence in it of cells and tissues that appear histologically to be highly malignant. The presence of neoplastic tissue within the intraperitoneal lymph nodes in the ascites form of the tumor is considered to be the result of infiltration rather than metastasis. The mouse teratoma is sometimes encapsulated, although it often invades adjacent host tissue. It is not clear why such tissue does not gain access to vascular channels and thus metastasize.

Teratomas rarely occur in mice. Only three have been observed at the National Cancer Institute. Each of these has been primary in the ovary. Jackson and Brues found a teratoma in the ovary of a C3H mouse and transplanted it. Fawcett described bilateral ovarian teratomas in a Swiss albino mouse. Recently, Stevens has observed testicular teratomas in approximately

2 percent of male mice of line 129 necropsied at the Jackson Memorial Laboratory.

References

Fawcett, D. W. Bilateral ovarian teratomas in a mouse. Cancer Research, 10:705–707, 1950.

Fekete, E., and Ferrigno, M. A. Studies on a transplantable teratoma of the mouse. Cancer Research, 12:438–440, 1952.

Jackson, E. B., and Brues, A. M. Studies on a transplantable embryoma of the mouse. Cancer Research, 1:494–498, 1941.

Leighton, J. The growth patterns of some transplantable animal tumors in sponge matrix tissue culture. J. Nat. Cancer Inst., 15:275–293, 1954.

Slye, M., Holmes, H. F., and Wells, H. G. Primary spontaneous tumors of the ovary in mice. Studies on the incidence and inheritability of spontaneous tumors in mice. J. Cancer Research, 5:205–226, 1920.

Stevens, L. Personal communication.

TUMORS OF THE MAMMARY GLAND

Mammary Adenocarcinoma C3HBA. Mouse

DEFINITION. An adenocarcinoma that arose spontaneously in the mammary gland of a C3H strain mouse.

HISTORY AND DESCRIPTION OF ORIGINAL TUMOR. Mammary Adenocarcinoma C3HBA was found in an untreated 9-month-old strain C3H female mouse on April 29, 1946, in the laboratory of H. B. Andervont at the National Cancer Institute, Bethesda, Maryland. The tumor was composed of two histologic patterns. One of these consisted of small uniform acini supported by a small amount of stroma. The other pattern consisted of solidly packed tumor cells arranged in nodular masses. The center of each mass was necrotic. The connective tissue stroma was largely confined to the periphery of these nodules.

TRANSPLANTATION STUDIES. Mammary Adenocarcinoma C3HBA has been transplanted by the inoculation of bits of tissue and also by the subcutaneous, intramuscular, intraocular, intrahepatic, and intraperitoneal inoculation of tumor brei. The tumor has also been grown beneath a transparent cellophane window inserted in the flank of a mouse (Algire's technic). When transplanted subcutaneously, the tumor becomes palpable in 7 days and kills the host within 10 to 28 days. There is limited infiltration of the surrounding soft tissues, and rarely, metastasis to the lungs.

The tumor has been successfully transplanted into C3H mice and to all F_1 hybrids, of which one parent was a strain C3H mouse. Variable success has attended attempts to transplant it to the F_1 backcross animals. However, it has not grown in mice of several other inbred strains tested. Adenocarcinoma C3HBA has been shown by Barrett and associates to contain the mammary tumor milk agent but not the XYZ factor (see Brown-Pearce Tumor).

There was some variation in the morphology of early generation transplants. In most cases the pattern was predominantly acinar. Even nodular areas of closely packed cells that appeared in many cases, and occasionally constituted the greater part of the tumor, could be shown with special staining methods to possess small acini. Later generation transplants have shown a more solid type of growth and fewer acini. No striking change in form such as transformation to sarcoma has occurred in this tumor.

DESCRIPTION OF CURRENT TUMOR. A subcutaneous transplant of the 136th generation of Mammary Adenocarcinoma C3HBA measures 1.0 cm. in diameter seven days following inoculation. It is incompletely encapsulated.

The cut surface of the tumor is composed of soft, granular, friable, pink or gray tissue. There is no gross evidence of hemorrhage, necrosis, or cyst formation.

Microscopically, the tumor cells are usually arranged in small nodules, but nests, clumps, cords, and a few acini are also present (fig. 184). These individual units are surrounded and separated from each other by a delicate stroma. In the small nodules, the cells at the periphery nearest the stroma are spindle shaped and arranged circumferentially, while more centrally the neoplastic cells are less elongated and arranged radially (fig. 185). A single acinus consists of two layers of radially arranged cuboidal cells, and the lumen contains periodic acid—Schiff-positive material.

Although the cells vary in shape and arrangement, their nuclei and cytoplasm are similar. The more rounded cells have an average diameter of 10 microns. The cell membrane is indistinct so that cells appear to merge one with another. The cytoplasm, constituting less than 50 percent of the cell, is basophilic and finely granular. The nuclei are centrally located, spheroid, umbilicated, or elongated. A delicate nuclear membrane encloses fine chromatin granules and a few dense chromatin bars, most of which are peripheral in position. One or two faintly acidophilic, centrally placed nucleoli are present. Ten or more mitotic figures, some abnormal, are observed in every high power field.

The stroma consists of fine strands of connective tissue. Reticular fibers are well demonstrated (fig. 186), but there are relatively few collagenic fibers. Small blood vessels of capillary caliber accompany the stroma and occasionally contain a thrombus. Necrosis is minimal and is generally confined to single groups of tumor cells at the periphery of the transplant. There are a few areas of hemorrhage.

References

Barrett, M. K., and Deringer, M. K. An induced adaptation in a transplantable tumor of mice. J. Nat. Cancer Inst., 11:51–59, 1950.

———, Deringer, M. K., and Dunn, T. B. Influence of the mammary tumor agent on the longevity of hosts bearing a transplanted tumor. J. Nat. Cancer Inst., 13:109–119, 1952.

———, and Morgan, W. C. A maternal influence on the growth rate of a transplantable tumor in hybrid mice. J. Nat. Cancer Inst., 10:81–88, 1949.

Dunn, T. B. Morphology of mammary tumors in mice. In: Homburger, F., and Fishman, W. H. (eds.). The Physiopathology of Cancer, pp. 123–148. New York: Paul B. Hoeber, Inc., 1953.

Bashford Carcinoma 63. Mouse

SYNONYMS. Tumor No. 63; Carcinoma 63, Bashford.

DEFINITION. An undifferentiated carcinoma that arose spontaneously in the mammary gland of a non-inbred mouse.

HISTORY AND DESCRIPTION OF ORIGINAL TUMOR. E. Gierke, working in the laboratory of E. F. Bashford in London, made a study of 45 spontaneous hemorrhagic mammary tumors occurring in mice of the Imperial Cancer

MAMMARY ADENOCARCINOMA C3HBA. MOUSE

(Tumor-bearing animal courtesy of Dr. M. K. Barrett, National Cancer Institute, Bethesda, Md.)

Figure 184. Photomicrograph of 136th generation transplant tumor. The peripheral portion shows the histologic pattern of the growth. The cells are usually arranged in small nodules; but nests, clumps, cords, and a few acini are present. Hematoxylin and eosin stain. X 60. N. C. I. 8972; A. F. I. P. Acc. No. 219934–185.

Figure 185. Photomicrograph of 136th generation transplant tumor showing the solid areas of the tumor and the arrangement and appearance of the cells within these areas. In the solid area the cells at the periphery nearest the stroma are spindle shaped and arranged circumferentially, while more centrally the neoplastic cells are less elongated and are arranged radially. Hematoxylin and eosin stain. X 430. N. C. I. 7820; A. F. I. P. Acc. No. 219934–186.

Figure 186. Photomicrograph of 136th generation transplant tumor showing a small nodule of tumor surrounded by reticular fibers. Wilder's silver preparation. X 650. N. C. I. 7822; A. F. I. P. Acc. No. 219934–187.

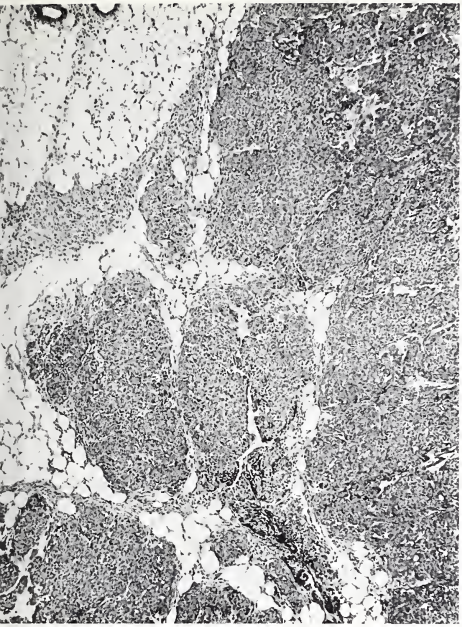

Fig. 184

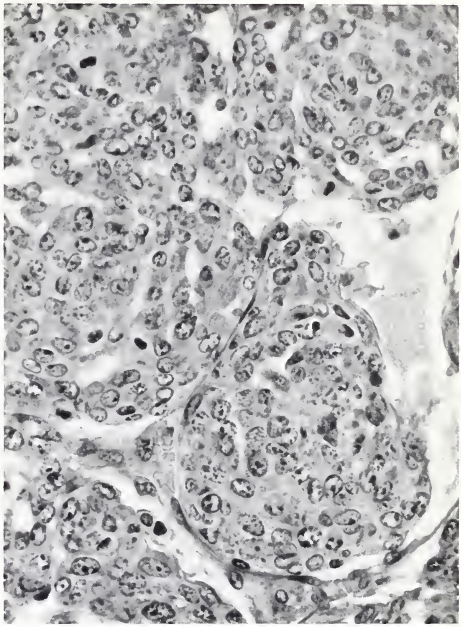

Fig. 185

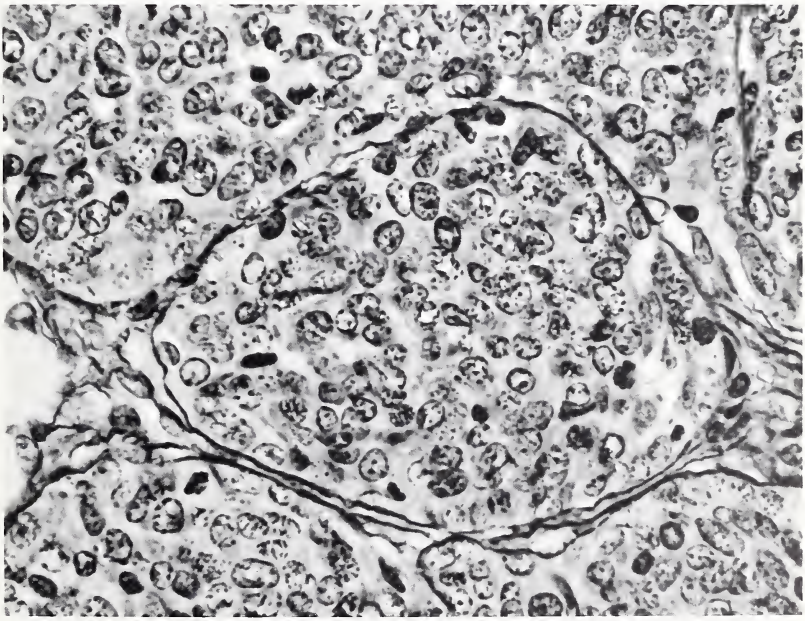

Fig. 186

Research Fund stock. Of 38 of these that were successfully transplanted to other mice, 12 metastasized to the lungs. In April 1907, Gierke transplanted one of these metastatic mammary tumors from the lung of mouse No. 63, and this tumor was subsequently designated as Bashford Carcinoma 63.

There is no individual description of the primary tumor from which the transplantable Bashford Carcinoma 63 was derived. Gierke, however, made some general observations on the group of tumors he studied. They were movable elevated masses under the skin, through which they appeared bluish. Some were ulcerated. The cut surface revealed pinkish white soft tumor tissue interspersed with hemorrhagic and serous cysts of variable size. The metastatic growths in the lungs varied from small reddish white nodules to large masses resembling the primary tumor. Histologically, these tumors showed an alveolar and an adenomatous pattern with small and large cystic spaces.

TRANSPLANTATION STUDIES. Bashford Carcinoma 63 is not strain specific. It was transplanted into mice of the Imperial Cancer Research Fund stock prior to the development of inbred strains of mice. Second generation transplants of this tumor grew successfully in 60 percent of mice inoculated. By the 13th generation, transplants grew successfully in 100 percent of the hosts. At present the tumor is usually transplanted every 10 to 14 days, but if allowed to grow, kills the host in from 28 to 42 days.

DESCRIPTION OF CURRENT TUMOR. A 14-day-old subcutaneous transplant tumor measures 1.5 x 1.0 x 1.1 cm. It is surrounded by a thin capsule of fibrous tissue. On section, much of the tumor is already necrotic and partially liquefied.

Microscopically, the capsule of the tumor consists of compressed host tissue containing young fibroblasts and a few inflammatory cells. More than one half of the tumor is necrotic. In the non-necrotic areas, the pattern consists of sheets of neoplastic cells (fig. 187) with interspersed sinusoidal vessels. The structural unit of the viable portion of the neoplasm consists of a central sinusoidal vessel surrounded by tumor cells (fig. 188). These islands of viable tumor are separated from each other by necrotic tissue. The thin-walled vessels consist of a single layer of endothelium anchored to a small amount of connective tissue. Some of the vessels are thrombosed. The pattern is that of a carcinoma with groups of tumor cells surrounded by reticular fibers (fig. 189).

The tumor cells are fairly uniform in size, shape, and staining capacity. They are deeply hyperchromatic and generally round or polygonal, except for a few columnar cells that immediately border upon a sinusoidal vessel. The tumor cells are closely packed together, and the limiting membrane of the cell is rather indistinct. At some points in the tumor certain formations of cells resemble tiny acini. There is not much cytoplasm. It is deeply basophilic and is often vacuolated in cells adjacent to necrotic areas. The baso-

philic nuclei are generally round, polygonal, or oval. The nuclear membrane is heavily stained and encloses fine and coarse granules and threads of chromatin. The nucleus contains one nucleolus that may be eosinophilic or basophilic. As many as five mitotic figures may be found in an oil immersion field, and most of them are of normal form.

References

Bashford, E. F. The behaviour of tumour cells during propagation. Sc. Rep. Cancer Fund, London, 4:131–214, 1911.

Gierke, E. The haemorrhagic mammary tumours of mice, with results of research into susceptibility and resistance to inoculation. Sc. Rep. Cancer Fund, London, 3:115–145, 1908.

Sugiura, K., and Stock, C. C. Studies in a tumor spectrum. I. Comparison of the action of methyl-bis (2-chloroethyl) amine and 3-bis (2-chloroethyl) aminomethyl-4-methoxymethyl-5-hydroxy-6-methylpyridine on the growth of a variety of mouse and rat tumors. Cancer, 5:382–402, 1952.

Sarcoma 37. Mouse

SYNONYMS: S–37; 37S.

DEFINITION. A rapidly growing undifferentiated tumor that originated as a carcinoma of the mammary gland of an untreated stock mouse.

HISTORY AND DESCRIPTION OF ORIGINAL TUMOR. The original tumor from which S–37 was derived was a spontaneous mammary adenocarcinoma, designated Carcinoma 37, that appeared in the thoracic region of an old female mouse of the Imperial Cancer Research Fund stock. The tumor was resected on September 25, 1906, but recurred shortly thereafter, and the mouse was killed on November 22. The origin and early transplant generations of Carcinoma 37 and its transformation to an anaplastic tumor were described by Haaland and by Bashford.

The resected portion of Carcinoma 37 measured approximately 1.8 cm. in diameter. Microscopically, it was composed of acini and solid masses of cells, with some of the acini containing secretory material. The stroma was delicate in some areas and abundant and cellular in others.

TRANSPLANTATION AND HISTOLOGIC CHANGE. An emulsion or bits of the resected portion of Carcinoma 37 were inoculated subcutaneously into 162 young mice of the Imperial Cancer Research Fund stock. A number of the mice were killed 1 to 9 days following inoculation in order to study the early stages of the growth. Of 69 mice surviving three weeks after inoculation, 8 had tumors and 4 of these were transplanted to new hosts. The early generation transplant tumors were composed chiefly of acini and solid masses of cells in varying proportion, but some also showed cystadenomatous structures lined with papillary excrescences. Old tumors developed central necrosis and fibrosis. Forty to 50 percent of the transplants grew successfully, beginning with the 2nd transplant generation. Some sublines of subsequent generations continued to reproduce the pattern of carcinoma; others eventually came to

BASHFORD CARCINOMA 63. MOUSE

(Tumor-bearing animal courtesy of Dr. Kanematsu Sugiura, Sloan-Kettering Institute for Cancer Research, New York City)

Figure 187. Photomicrograph of transplant tumor. The cells composing the tumor are fairly uniform in size, shape, and staining capacity, but deeply hyperchromatic. There are many mitotic figures. Hematoxylin and eosin stain. X 690. N. C. I. 8063; A. F. I. P. Acc. No. 219934–188.

Figure 188. Photomicrograph of transplant tumor showing an island of tumor cells surrounded by necrotic tissue. A small vessel is present in the center of the group of viable tumor cells. Hematoxylin and eosin stain. X 475. N. C. I. 8058; A. F. I. P. Acc. No. 219934–189.

Figure 189. Photomicrograph of transplant tumor. The pattern is that of a carcinoma with groups of cells surrounded by reticular fibers. Wilder's silver preparation. X 610. N. C. I. 8056; A. F. I. P. Acc. No. 219934–190.

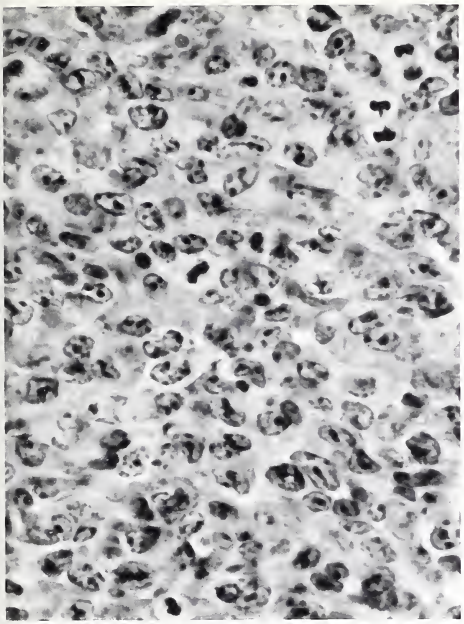

Fig. 187

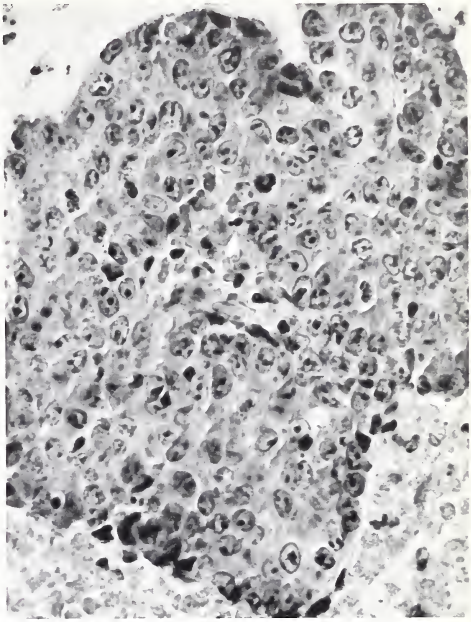

Fig. 188

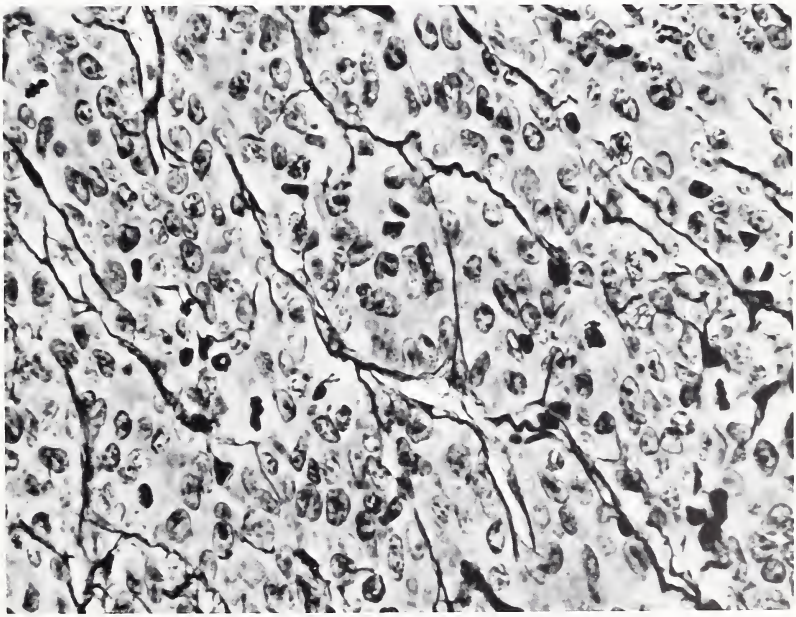

Fig. 189

resemble a sarcoma. This sarcomatous transformation occurred several times in descendants of a series of transplanted tumors designated 2A. The transformation from carcinoma to sarcoma was a gradual process in transplants propagated over a period of 5 to 18 months after the initial transplantation of Carcinoma 37. Once the sarcomatous pattern was firmly established in all parts of the transplantable tumor, the growth did not revert to a carcinoma in any instance. In describing the transformation to sarcoma observed in tumor series 2A, Haaland noted that the connective tissue stroma became more cellular and increased in quantity. Broad bands of atypical spindle-shaped cells appeared in the stroma, and these in turn were replaced by atypical polymorphous cells considered to be the sarcomatous component. Necrosis of the epithelial portion of the tumors appeared more frequently. With the introduction of the sarcomatous element, the tumors were interpreted as being of mixed type. Coincident with these changes in morphology, the growth rate was increased. Metastases found in the lungs and elsewhere were either carcinomatous, sarcomatous, or mixed in appearance. Eventually, in most instances the carcinomatous elements were entirely replaced by sarcoma. A tumor of one of the sublines that contained short spindle-shaped cells for several generations finally became stabilized as a polymorphous-cell sarcoma. It was this tumor, or one similar to it, that later became known as Sarcoma 37. Although Sarcoma 37 grew successfully in 90 to 100 percent of hosts inoculated, it frequently regressed. The tumor grew rapidly, invaded tissues adjacent to it, and developed central necrosis as early as 10 to 14 days following transplantation. Metastases were found in the lymph nodes, lungs, liver, spleen, myocardium, and kidneys.

CURRENT STATE OF S–37. Although not strain specific, the transplant tumor grows better in some strains of mice than in others. Leiter and Kline have described observations on the growth and regression of Sarcoma 37 in about 2,000 mice of 12 strains or stocks. According to these authors, the tumor grew progressively without regression in more than 99 percent of the BALB/c, DBA/2, ABC, ZBC, and (BALB/c x A)F_1 mice (formerly CAF_1) in which it was transplanted. Only three of the 559 (BALB/c x A)F_1 mice failed to show growth of the transplanted tumor. Whether the transplants failed to grow at all in these three mice or whether they started to grow and later regressed is not known.

Regression rates of 42 to 78 percent were observed in C3H, C57BL, CF, CFW, NIH–B.S., and NIH–Reg. mice. The Sarcoma 37 transplants grew for a week or 10 days before the signs of regression appeared. Fewer regressions occurred in strain A mice—2 percent in the Heston subline and 38 percent in the Lilly subline.

S–37 is used extensively to evaluate the effectiveness of chemotherapeutic agents. The tumor is valuable for such work, due to its successful transplantability and its rapid growth in mice of many strains. Moreover,

transplants become richly vascularized as early as 5 days after transplantation, and the untreated tumor shows little degeneration and necrosis within the first 8 or 10 days.

A standardized sterile **technic of transplantation** is of utmost importance in studies dealing with transplantable tumors. In the laboratory of chemical pharmacology of the National Cancer Institute, Bethesda, Maryland, Sarcoma 37 is used as a test object for screening chemotherapeutic agents. In this laboratory, the tumor is transplanted by injecting with a syringe and needle 0.05 cc. of a tumor mash diluted with one volume of 0.9 percent saline solution into the muscles of the thigh. To inoculate 150 to 250 mice, 8 to 12 one-week-old tumors are pooled and mashed. Each such batch is tested for bacterial contamination by incubating an aliquot in nutrient broth for aerobic microorganisms and in a medium containing thioglycollate for anaerobic organisms. When the cultures show growth, the corresponding experiments are considered unreliable.

Most investigators consider that intramuscular transplantation of Sarcoma 37 is preferable to subcutaneous transplantation. The tumor grows faster in muscle tissue and is less likely to ulcerate than when placed under the skin. When the transplant is placed in the thigh muscle of one leg, a blood-borne chemical agent can conveniently be injected subcutaneously in the contralateral axilla at a distance from the tumor. If the transplant is to be inoculated subcutaneously, early ulceration and infection are less likely to occur if the tumor tissue is inserted between the shoulder blades.

Tumors, whether transplanted subcutaneously or intramuscularly, are palpable within four or five days. In general, they are well vascularized at five days, but become necrotic eight days after inoculation. The tumor kills the host in 18 to 49 days, with very few animals surviving more than three weeks.

An ascites form of S–37 has been propagated by intraperitoneal transfer. Inoculated by this route, the tumor cells multiply rapidly. There is neoplastic infiltration of the subperitoneal tissues and metastasis to lymph nodes and lungs. The host rarely survives more than two weeks.

DESCRIPTION OF CURRENT TUMOR. For the purpose of the following description, S–37 was inoculated into two female (C57L x A)F_1 mice (formerly LAF_1). A 6-day-old subcutaneously transplanted tumor measures 28 x 12 x 8 mm. It is grayish yellow and moderately firm. The cut surface shows a small central area of necrosis and hemorrhage. An intramuscular transplant of the same age showing essentially the same gross characteristics is slightly larger, has less necrosis, and infiltrates surrounding tissues more aggressively.

Microscopic examination reveals that the central fourth of the subcutaneous transplant tumor is necrotic. A wide zone of loose areolar connective tissue and deep and superficial skeletal muscle is found at the perimeter of the tumor. These host tissues are infiltrated by tumor cells and show a slight inflammatory reaction with young fibroblasts and hyperemic blood vessels.

(The presence of large numbers of polymorphonuclear leukocytes in the tissues surrounding the tumor would generally indicate bacterial contamination of the original mash at implantation.) Although a wide band of the panniculus carnosus has been invaded, its outline can still be traced within the tumor by the presence of degenerated muscle fibers. Remnants of degenerated and necrotic skeletal muscle fibers, blood vessels, nerves, and mammary ducts can be recognized deep within the tumor.

Both the subcutaneous and intramuscular transplants of S–37, six days after inoculation, consist of a solid mass of cells interspersed with small islands of stroma containing capillary-like blood vessels (figs. 190, 191). The tumor cells are so closely approximated to one another that their peripheral limits are often indistinct. At the periphery of the tumor where the neoplastic cells are loosely arranged, they are round or slightly elongated. The cytoplasm is basophilic and homogeneous. The nuclei are round, oval, horseshoe shaped, or dumbbell shaped, and uniformly hyperchromatic (fig. 192). A fine nuclear membrane encloses delicate chromatin granules and a loose linin network which radiates from one or more of the large nucleoli (fig. 193). An average of two mitotic figures occurs in an oil immersion field, and many of these figures are bizarre. In the viable portions of the tumor there is an abundant reticulum. Single tumor cells and groups of 2 or 3 tumor cells are surrounded by reticular fibers (fig. 194). The thin-walled blood vascular channels are enveloped in a delicate sheath of connective tissue stroma. The degenerated tumor tissue is devoid of reticular fibers, and here, most of the blood vessels are dilated and thrombosed. Little hemorrhage is noted in any part of the tumor.

This tumor resembles an undifferentiated neoplasm because of the undeveloped form of its cells, the intimate relation of the cells to reticulum, and the lack of a specific histologic pattern. However, since the original tumor was a papillary adenocarcinoma and clearly arose in the mammary gland, Sarcoma 37 is classified with tumors of the mammary gland. Since the tumor cannot be classified either as a carcinoma or as a sarcoma, it would logically follow that another designation, such as S–37, be assigned to it. However, since the tumor has been called Sarcoma 37 for 50 years, we are retaining the name.

References

Algire, G. H., and Chalkley, H. W. Vascular reactions of normal and malignant tissues in vivo. I. Vascular reactions of mice to wounds and to normal and neoplastic transplants. J. Nat. Cancer Inst., 6:73–85, 1946.

Bashford, E. F. The behaviour of tumour cells during propagation. Sc. Rep. Cancer Fund, London, 4:131–214, 1911.

Goldie, H., and Felix, M. D. Growth characteristics of free tumor cells transferred serially in the peritoneal fluid of the mouse. Cancer Research, 11:73–80, 1951.

Goldin, A., Humphreys, S. R., Venditti, J. M., Dennis, D., and Mantel, N. Growth studies of Sarcoma 37 in mice. J. Nat. Cancer Inst., 16:1207–1220, 1956.

Haaland, M. Contributions to the study of the development of sarcoma under experimental conditions. Sc. Rep. Cancer Fund, London, 3:175–261, 1908.

Leiter, J., Downing, V., Hartwell, J. L., and Shear, M. J. Damage induced in Sarcoma 37 with podophyllin, podophyllotoxin, alpha-peltatin, beta-peltatin, and quercetin. J. Nat. Cancer. Inst., 10:1273–1293, 1950.

———, and Kline, I. Growth and survival of Sarcoma 37 in various mouse stocks. J. Nat. Cancer Inst., 14:449–454, 1953.

Mammary Fibroadenoma R2737. Rat

SYNONYM: Rat Mammary Adenofibroma.

DEFINITION. A fibroadenoma that arose spontaneously in the mammary gland of a female rat of the August strain.

HISTORY. Mammary Fibroadenoma R2737 was found in February 1946. It arose in an untreated, pink-eye-dilute agouti piebald female rat of August line 28807 from the colony maintained by Dunning and Curtis at Wayne University, Detroit, Michigan. There was no histologic description made of this tumor, but it was stated that it arose in the region of the mammary glands and was similar to other mammary fibroadenomas of the rat.

The fibroadenoma is the most commonly occurring spontaneous neoplasm of the mammary gland of the rat. It is usually firm, lobular, and encapsulated. Tumors of this type were described by Loeb in 1902, who later with Fleisher, transplanted one of them for 3 generations. Emge studied a mammary fibroadenoma that arose in a Wistar rat in 1928. He described the morphologic characteristics and biologic behavior of this transplantable tumor.

TRANSPLANTATION STUDIES. Mammary Fibroadenoma R2737, when inoculated subcutaneously into female rats of the same strain as that of the animal in which the tumor arose, grows successfully without regression in all cases. Immature rats of both sexes and adult male rats are somewhat resistant to transplantation of this tumor. Pieces of tissue used to transplant the tumor subcutaneously become vascularized more readily than do tumor cells inoculated as a suspension. The animal usually maintains excellent nutrition during the course of tumor growth, although the weight of the tumor may exceed that of the animal. Old tumors may show ulceration, infection, and hemorrhage. The subcutaneous transplant of R2737 becomes palpable 4 to 6 weeks after inoculation and kills the host in 6 to 10 months. (Many of these data were kindly contributed by Dr. W. F. Dunning of the University of Miami, Coral Gables, Fla.)

DESCRIPTION OF CURRENT TUMOR. Mammary Fibroadenoma R2737 is described as being encapsulated, lobulated, tough, and pinkish white. It does not metastasize.

Sections reveal that it is a well circumscribed tumor, although its capsule is invaded at irregular points by glandular elements. The capsule consists of bundles of relatively acellular dense collagenic fibers, extensions from which

SARCOMA 37. MOUSE

(Tumor-bearing animals courtesy of Dr. Joseph Leiter, National Cancer Institute, Bethesda, Md.)

Figure 190. Photomicrograph of intramuscular transplant tumor showing the peripheral portion where there is aggressive neoplastic infiltration of skeletal muscle. Remnants of necrotic muscle may be found deep within the tumor. Hematoxylin and eosin stain. X 75. N. C. I. 8285; A. F. I. P. Acc. No. 219934–191.

Figure 191. Photomicrograph of intramuscular transplant tumor showing the degeneration of muscle fibers in the wake of the infiltrating tumor. Hematoxylin and eosin stain. X 155. N. C. I. 9730; A. F. I. P. Acc. No. 219934–192.

Figure 192. Photomicrograph of intramuscular transplant tumor. The neoplasm is composed of tightly packed cells showing basophilic cytoplasm and hyperchromatic nuclei. Mitotic figures are numerous. A remnant of necrotic skeletal muscle may be seen in the lower right corner. Hematoxylin and eosin stain. X 520. N. C. I. 8286; A. F. I. P. Acc. No. 219934–193.

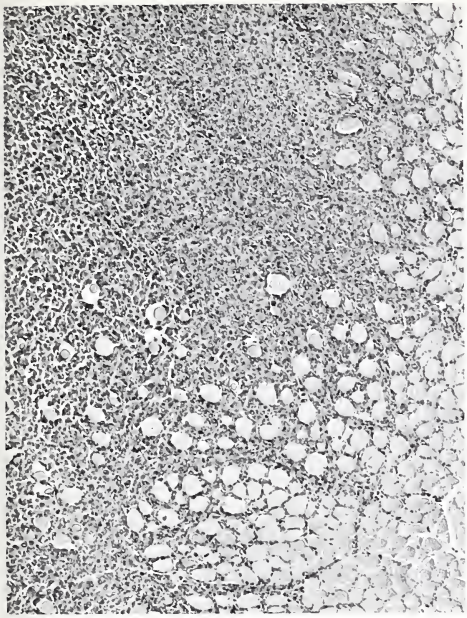

Fig. 190

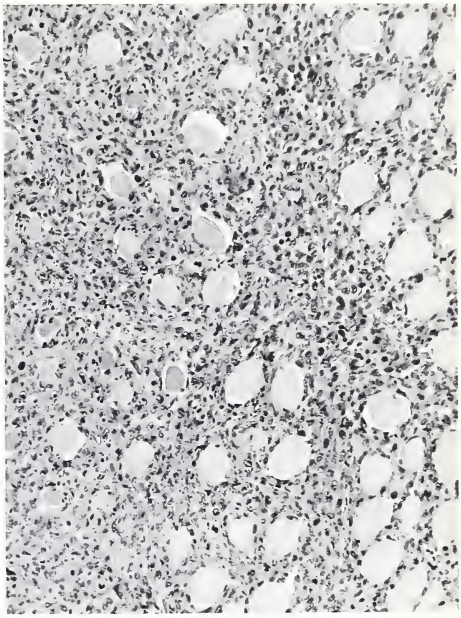

Fig. 191

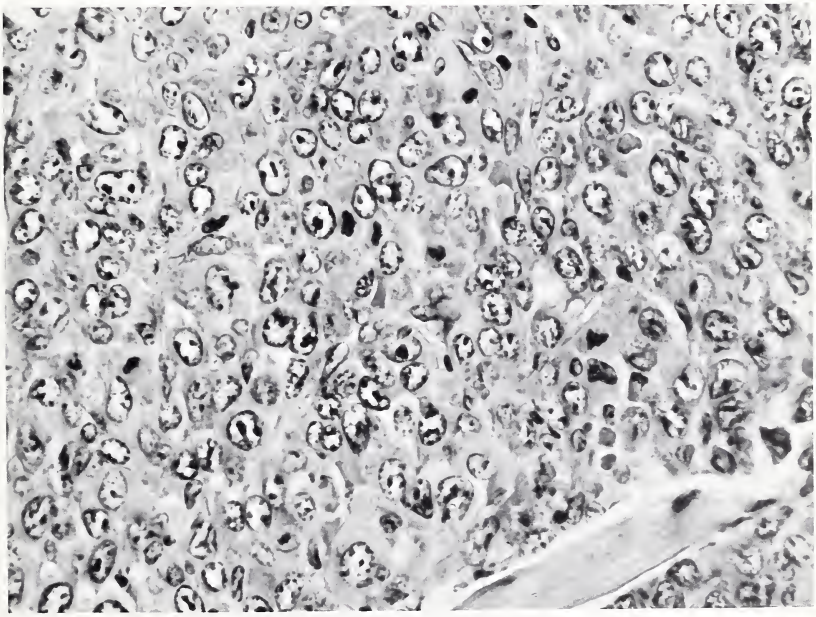

Fig. 192

SARCOMA 37. MOUSE

Figure 193. Photomicrograph of intramuscular transplant tumor showing cellular detail and the presence of mitotic figures. Note linear arrangement of cells around each mitotic figure. Hematoxylin and eosin stain. X 1360. N. C. I. 9723; A. F. I. P. Acc. No. 219934–194.

Figure 194. Photomicrograph of subcutaneous transplant tumor. The reticular fibers are numerous and are intimately associated with the tumor cells. Mitotic figures are numerous. Wilder's silver preparation. X 610. N. C. I. 8288; A. F. I. P. Acc. No. 219934–195.

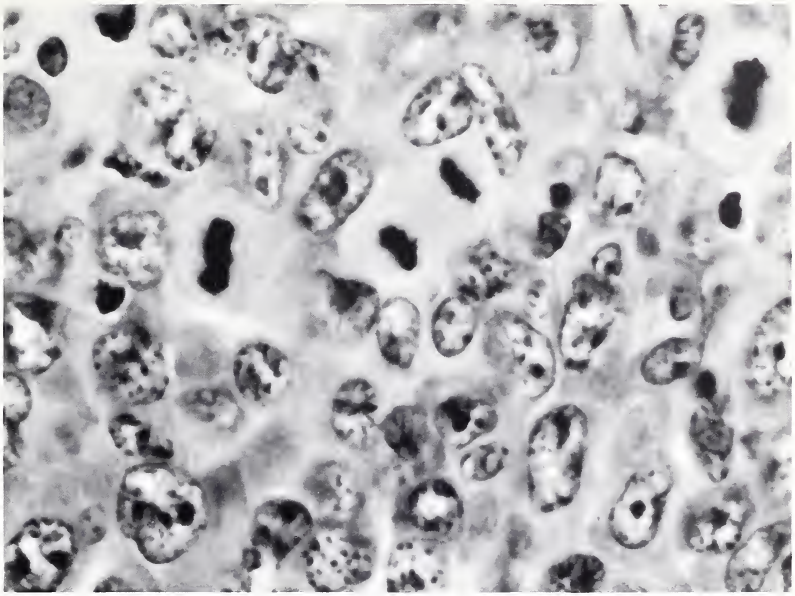

Fig. 193

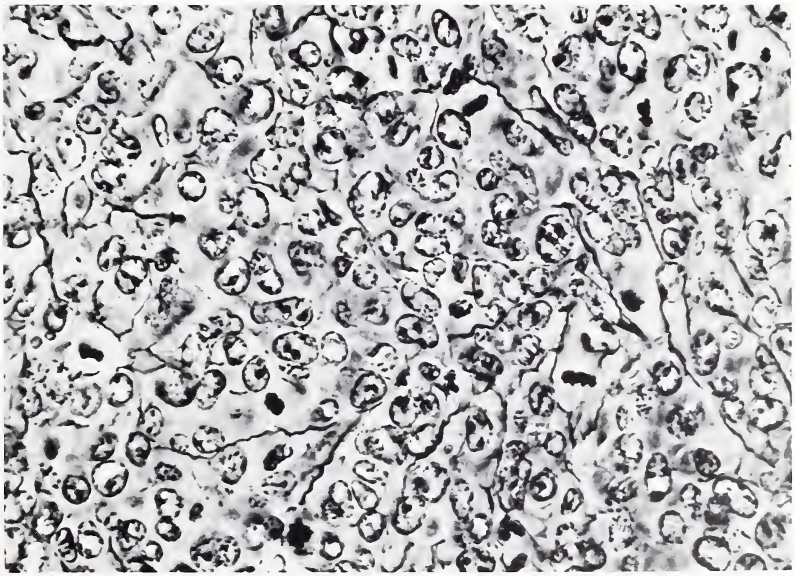

Fig. 194

divide the tumor into lobules. Arteries, veins, and adipose tissue from the host are incorporated within the mass of the tumor. The vessels of the tumor are of capillary size and are not numerous. There are a few small areas containing small lymphocytes and mast cells, indicative of inflammation.

The illustrations show the evolutionary changes which this tumor transplant undergoes (fig. 195). In the first place, the adipose tissue is infiltrated with ductlike structures supported by connective tissue stroma (fig. 196). Coincident with the replacement of adipose tissue by the infiltrating tumor, the glandular elements proliferate and the amount of stroma increases. This results in the almost complete replacement of fat by tumor tissue (fig. 197). Even while this process is taking place in some parts of the tumor, regressive changes have begun to appear in other areas (fig. 198). These regressive changes are characterized by hyalinization of the stroma with atrophy and disappearance of the glandular elements. As a result of this infiltration, proliferation, hyalinization, and atrophy, the tumor finally becomes characterized by a pattern of atrophied duct structures surrounded by concentric rings of collagenous connective tissue (fig. 199).

The epithelial component of the tumor consists of small, branching, ductlike structures lined with a single layer of cuboidal or columnar cells that are uniform in appearance and staining reaction (fig. 200). The nucleus is basally situated, hyperchromatic, round or oval, and has a sharply outlined nuclear membrane. Within the nucleus there is fine chromatin material. There is generally 1 basophilic centrally placed mucleolus; rarely 2 or 3 nucleoli are seen. Mitotic figures are not numerous, and they are normal in appearance. In some ducts, the cytoplasm of the portion of the cell bordering the lumen contains a small amount of periodic acid—Schiff-positive material and is darkly colored and granular in Wilder's silver preparation. Some of the acini contain periodic acid—Schiff-positive material in the lumen.

Characteristics of mammary fibroadenomas. The so-called "fibroadenoma" of the mammary gland of the rat is often referred to as benign because of its close histologic resemblance to benign tumors of man. Nevertheless, if considered in the light of criteria for the evaluation of malignancy in experimental neoplasia, the tumor under certain conditions may be said to be malignant. This mammary tumor can be transplanted, and, as becomes evident in the following paragraphs, it may develop the characteristics of a purely epithelial or purely connective tissue tumor, a mixed tumor, or a genuine carcinoma or sarcoma.

Growth of the primary tumor is generally slow but progressive, and the tumor may reach an enormous size. According to Foulds' review of the studies made by various investigators of the fibroadenoma of the breast in rats, the structure of primary tumors of this type frequently differs from that considered typical of a fibroadenoma. The epithelial component may increase at the expense of the connective tissue so that the histologic appearance

is more like that of an adenoma or a secreting adenoma. During pregnancy and lactation, or after the administration of estrogens, secretory activity in the tumor cells may roughly parallel that of the surrounding breast tissue. The tumor is thus responsive to a physiologic stimulus in much the same way as is the normal tissue from which it was derived. On the other hand, the connective tissue component may overgrow the epithelium to produce the pattern of a fibroma or, rarely, a sarcoma. Such changes are likely to occur in long standing primary tumors of old rats. Possibly growth of the epithelial component of the tumor depends upon estrogens which may be present in inadequate amounts in old rats.

When a mammary tumor of the fibroadenomatous type is transplanted to other rats, its histologic pattern may be duplicated for many successive generations, or structural variations may occur. Like the primary tumor, and under similar hormonal conditions, the predominant pattern of the transplanted tumor may become that of an adenoma or a secreting adenoma. Infrequently and for reasons that are not understood, more extreme alterations may occur during transplantation. The epithelium may differentiate into squamous, sebaceous, or sweat gland type, and the connective tissue may show chondroid, osteoid, or adipose differentiation. Occasionally the lesion of chronic mastitis may be simulated. According to Foulds, all these variations are temporary and reversible. However, if during transplantation the epithelial component is lost and the histologic pattern of a fibroma or sarcoma develops, the change is permanent, and the epithelial component never reappears.

A transformation to sarcoma rarely occurs in primary mammary tumors but commonly occurs in transplanted ones. This change from fibroadenoma to fibroma and later to sarcoma may take place early or late in the course of serial transplantation. The alteration in structure may become completed within one transplant generation or it may require several generations. A comparable irreversible change in the epithelial component, leading through adenoma to carcinoma, occurs but rarely. Thus, the same tumor, if seen at different stages in its evolution, might be diagnosed as an epithelial or a connective tissue growth, or as a mixed tumor, any of which might be considered to be benign or malignant.

The plasticity and variability of structure and behavior of the so-called "fibroadenoma" of the rat is thus accompanied in serial transplantation by a tendency to irreversible change toward a more stable and more aggressive tumor, and especially toward sarcoma. As stated by Foulds, fibroadenoma appears to be a tumor in a stage of uncompleted development; given time and opportunity, it changes into something different.

References

Davis, J. H., Murphy, K. M., and Emge, L. A. Effect of dibenzanthracene on transplantable mammary adenofibroma of the white rat. Am. J. Path., 17:93–102, 1941.

MAMMARY FIBROADENOMA R2737. RAT

(Fixed tissue courtesy of Dr. W. F. Dunning, University of Miami, Coral Gables, Fla.)

Figure 195. Photomicrograph of transplant tumor. A low power view of a histologic section showing coarse and fine lobulation of the tumor.

A. Areas of adipose tissue infiltrated by ductlike structures accompanied by a small amount of connective tissue.

B. A nodule composed of numerous ductlike structures and young connective tissue.

C. An area of the tumor composed of old hyalinized connective tissue and a few atrophic ductlike structures.

Hematoxylin and eosin stain. X 6. N. C. I. 8225; A. F. I. P. Acc. No. 219934-196.

Figure 196. Photomicrograph of transplant tumor. The area of adipose tissue shows the early stage of infiltration by a few ductlike structures accompanied by stroma. Hematoxylin and eosin stain. X 105. N. C. I. 8211; A. F. I. P. Acc. No. 219934-197.

Figure 197. Photomicrograph of transplant tumor showing an area in which most of the adipose tissue has been replaced by proliferating duct structures accompanied by a large amount of connective tissue. Hematoxylin and eosin stain. X 105. N. C. I. 8212; A. F. I. P. Acc. No. 219934-198.

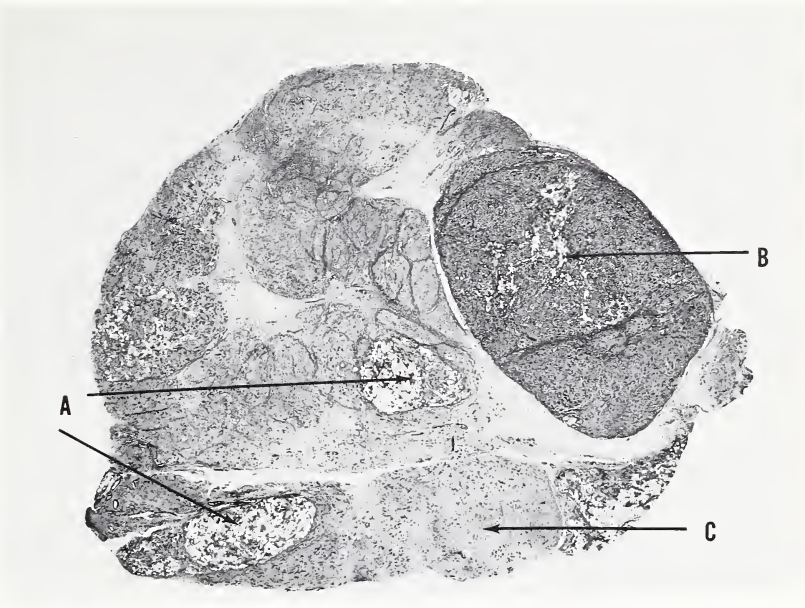

Fig. 195

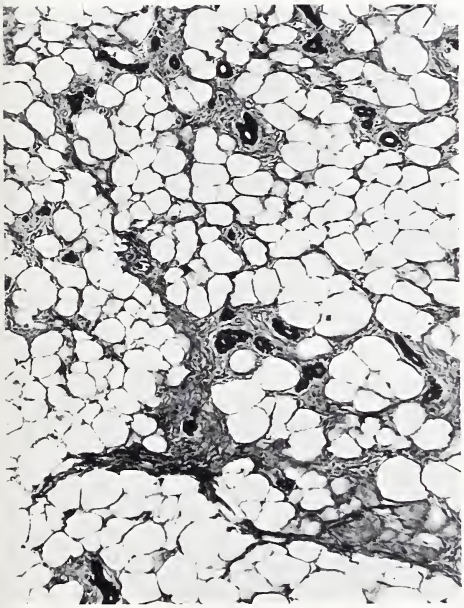

Fig. 196

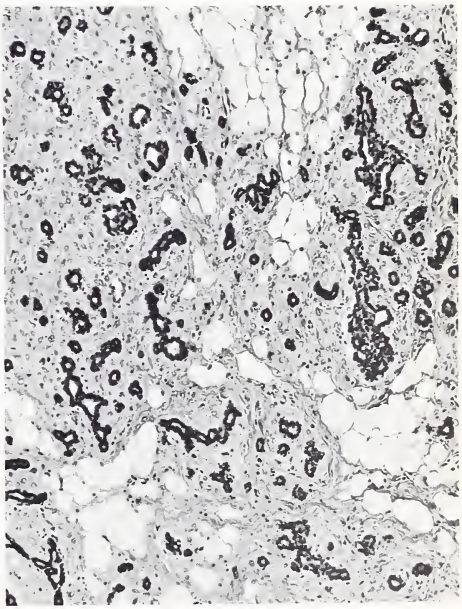

Fig. 197

MAMMARY FIBROADENOMA R2737. RAT

Figure 198. Photomicrograph of transplant tumor. The histologic pattern departs from that shown in figure 197 in that there is a low grade inflammatory reaction. This is shown at the center. Regressive changes, consisting of atrophy of duct structures and periductal fibrosis, have begun. Hematoxylin and eosin stain. X 105. N. C. I. 8213; A. F. I. P. Acc. No. 219934–199.

Figure 199. Photomicrograph of transplant tumor. This area shows atrophy of duct structures and sclerosis. Hematoxylin and eosin stain. X 105. N. C. I. 8214; A. F. I. P. Acc. No. 219934–200.

Figure 200. Photomicrograph of transplant tumor. A high power view of the branching duct structures that constitute the epithelial component of the tumor. Hematoxylin and eosin stain. X 430. N. C. I. 8243; A. F. I. P. Acc. No. 219934–201.

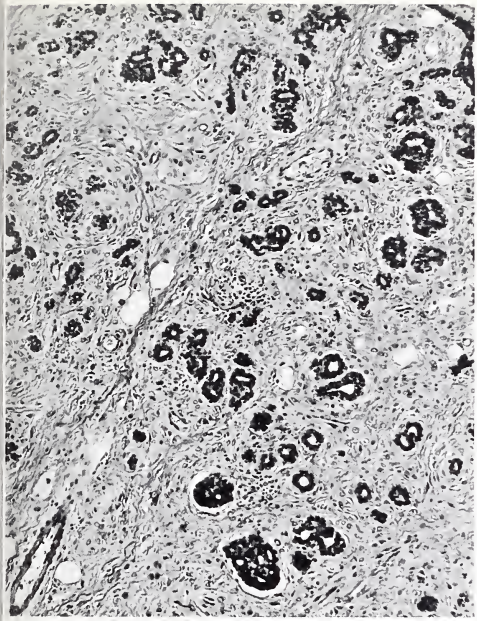

Fig. 198

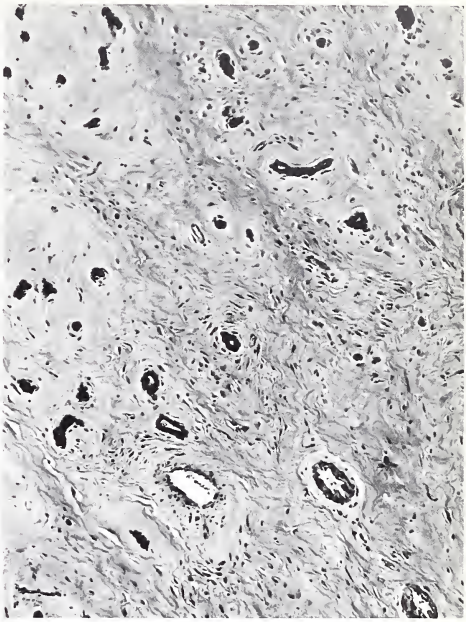

Fig. 199

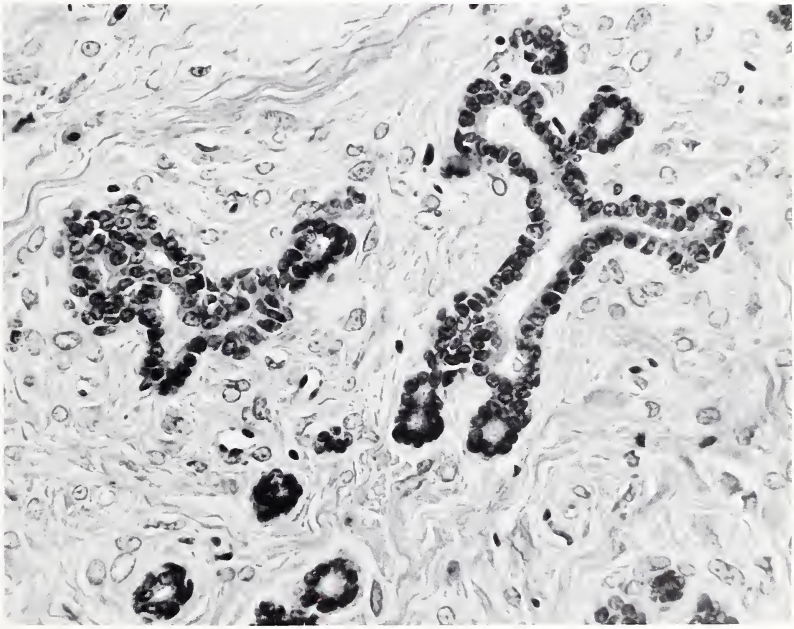

Fig. 200

Emge, L. A. Sarcomatous degeneration of transplantable mammary adenofibroma of the white rat. Arch. Path., 26:429–440, 1938.

———, and Murphy, K. M. The influence of long-continued injections of estrogen on mammary tissue. Am. J. Obst. & Gynec., 36:750–768, 1938.

Foulds, L. Experimental study of the course and regulation of tumour growth. Ann. R. Coll. Surgeons England, 9:93–101, 1951.

Loeb, L., and Fleisher, M. S. Transplantation of benign tumors. J. Cancer Research, 1:427–459, 1916.

Mammary Adenocarcinoma R2426. Rat

DEFINITION. An adenocarcinoma that originated spontaneously in the mammary gland of a female rat of the August strain.

HISTORY AND DESCRIPTION OF ORIGINAL TUMOR. Adenocarcinoma R2426 arose in a pink-eye-dilute agouti hooded female rat of the August strain from the colony of M. R. Curtis and W. F. Dunning at the Institute of Cancer Research, Columbia University, New York City. This rat had had one pregnancy at five months of age and had suckled her nine young for four weeks. The animal was 337 days old when necropsied on February 21, 1939. The tumor measured 4 x 3.5 cm. and weighed 12 gm. It was a firm, encapsulated growth located in the lower right ventral mammary region. There were no metastases. The tumor was described histologically as a well differentiated adenocarcinoma and was illustrated in a paper by Eisen in 1940.

TRANSPLANTATION STUDIES. The tumor has been transplanted by subcutaneous, intravenous, intraperitoneal, intraocular, and intraprostatic inoculation. When transplanted subcutaneously, it grew successfully without regression in 100 percent of male and female rats of the same inbred strain as the animal in which the tumor arose. Tumor tissue inoculated into rats of substrains of the original August strain grew in some of them, but in several of these, growth was followed by regression. Attempts to transfer the tumor to rats of the Sherman, Copenhagen, AXC, and two lines each of the Fisher and Zimmerman strains were unsuccessful except in one male Fisher rat. Intraperitoneal inoculation of an emulsion of tumor cells into rats of the August strain resulted in widespread peritoneal implants. Using the intravenous route, massive neoplastic deposits, described as papillary and cystic, developed in the lungs. Intraocular inoculation with tumor brei resulted in the development of a vascularized transplant that protruded from the orbit at 21 days. (Many of these data were kindly contributed by Dr. W. F. Dunning of the University of Miami, Coral Gables, Fla.)

DESCRIPTION OF CURRENT TUMOR. A subcutaneous transplant of Mammary Adenocarcinoma R2426 is described as being pink to gray and irregularly lobated. It is surrounded in part by a thin capsule through which tumor tissue extends to invade the surrounding host tissues. After the transplant tumor has grown for some time it may metastasize to the lungs. Large tumors often show areas of necrosis.

The histologic pattern is that of a well differentiated papillary cystic adenocarcinoma arranged in coarse lobules that are surrounded by thick bundles of connective tissue continuous with the capsule of the transplant (fig. 201). The acini are lined with two or more layers of epithelial cells and vary considerably in size and shape (fig. 202). Small foci composed of solid sheets of cells are occasionally noted. There is papillary infolding of the epithelium and desquamation of cells into the cystic spaces. The tumor cell is low columnar or cuboidal, with a sharply defined cell membrane. The cytoplasm is finely granular and rarely vacuolated. The periodic acid—Schiff reaction reveals purplish red material within the cytoplasm of some cells and occasionally in the lumen of an acinus or cystic space.

The nuclei are generally round or elongated and rarely lobated. An occasional multinucleated cell may be found. A densely stained nuclear membrane encloses fine chromatin clumps and linin threads. There is usually one basophilic nucleolus which in some cases may occupy an eccentric position. The mitotic figures appear normal and there is an average of less than one per high power field.

The thick septa of connective tissue that divide the growth into lobules contain most of the blood vessels of the tumor and are infiltrated with a few inflammatory cells. Fine collagenic and reticular fibers branch off these connective tissue septa and surround the glandular elements of the tumor (fig. 203).

References

Cahill, W. M., Dunning, W. F., and Smith, A. H. A free choice dietary study of tumor-bearing rats. Cancer Research, 3:830–832, 1943.

Eisen, M. J. Transplantable carcinoma of the rat breast. Am. J. Cancer, 39:36–44, 1940.

Walker Carcinosarcoma 256. Rat

SYNONYMS: Walker Rat Tumor; Walker Sarcoma 256.

DEFINITION. A carcinosarcoma that arose spontaneously in the region of the mammary gland of a pregnant albino rat.

HISTORY AND DESCRIPTION OF ORIGINAL TUMOR. This tumor developed spontaneously in the region of the mammary gland of a pregnant albino rat in 1928 in the laboratory of George Walker at the Johns Hopkins University School of Medicine. The mass was the size of a large pecan and was located in the lower left abdominal wall. During lactation the tumor regressed, but it recurred after weaning and grew rapidly thereafter.

At necropsy, this subcutaneous tumor was found to be the size of a hen's egg and appeared to be incompletely encapsulated. On section, a portion was composed of firm, granular, grayish red tissue with small foci of necrosis. The remainder was hemorrhagic and necrotic. There were no metastatic growths.

MAMMARY ADENOCARCINOMA R2426. RAT

(Fixed tissue courtesy of Dr. W. F. Dunning, University of Miami, Coral Gables, Fla.)

Figure 201. Photomicrograph of transplant tumor. The pattern is that of a papillary cystic adenocarcinoma divided into lobules by thick bundles of connective tissue stroma. Hematoxylin and eosin stain. X 83. N. C. I. 8543; A. F. I. P. Acc. No. 219934-202.

Figure 202. Photomicrograph of transplant tumor. This area shows irregularly shaped acini and stroma infiltrated with inflammatory cells. Hematoxylin and eosin stain. X 210. N. C. I. 8518; A. F. I. P. Acc. No. 219934-203.

Figure 203. Photomicrograph of transplant tumor. Note the distribution of reticular fibers in a papillary adenomatous structure of the tumor. Wilder's silver preparation. X 250. N. C. I. 8520; A. F. I. P. Acc. No. 219934-204.

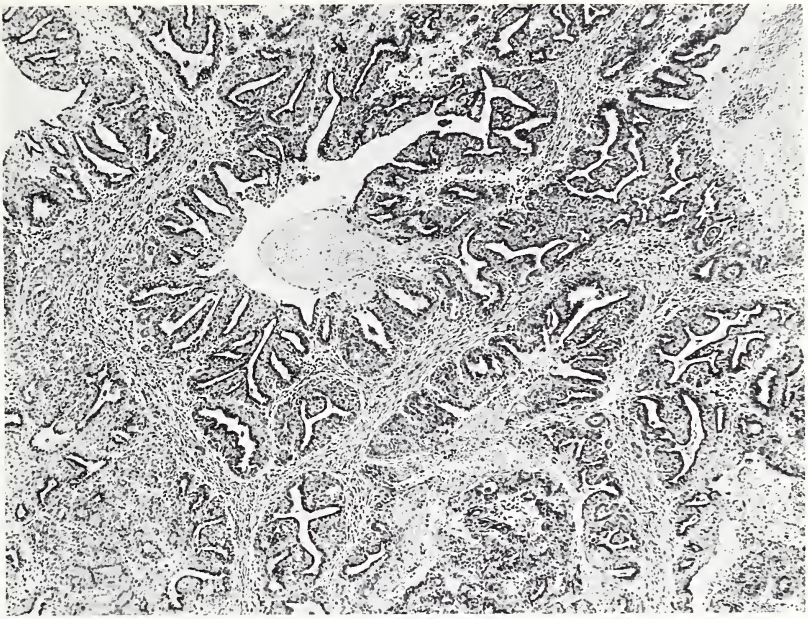

Fig. 201

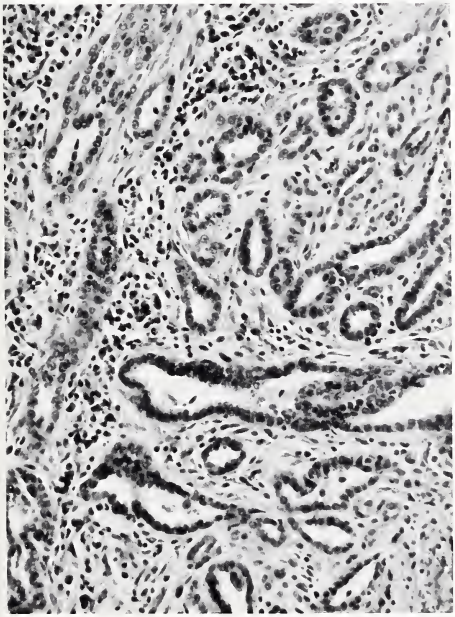

Fig. 202

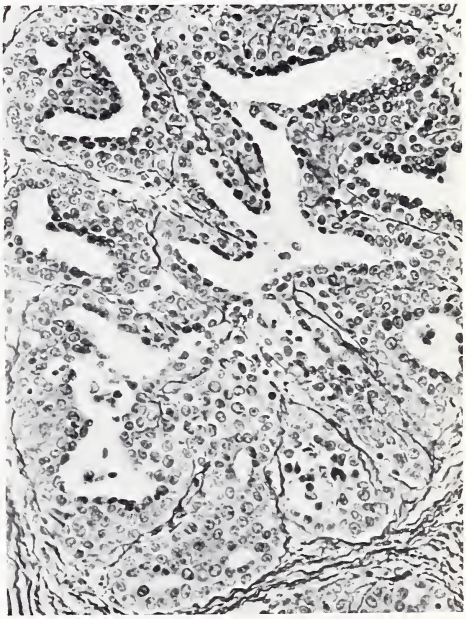

Fig. 203

On microscopic examination, the tumor was diagnosed as adenocarcinoma. It consisted in part of both simple and complex acini, showing proliferation and stratification of cells. Sheets, strands, and nests of neoplastic cells, only partially confined by the connective tissue capsule, were also found. The nuclei of the epithelial cells were large, prominent, round or oval, and deepy stained. There was stated to be distinct evidence that the nucleolus consisted of a karyosome deeply colored with hematoxylin and an eosinophilic portion that was thought to be a plasmosome. The stroma consisted of loose cellular connective tissue containing slender spindle-shaped cells, most of which possessed elongated hyperchromatic nuclei. Other cells had a somewhat larger granular nucleus with a relatively prominent nucleolus. The nature of this latter type of cell, whether fibroblastic or epithelial, was not determined.

TRANSPLANTATION STUDIES. The first two transplant generations of the Walker tumor were accomplished with only limited success. Thereafter, the transplant tumors grew successfully in nearly 100 percent of the Doure-Doure and other strains of rats receiving intramuscular or subcutaneous injections of brei or tissue fragments. Sugiura stated in correspondence with us that between July 1953 and July 1954 he transplanted the tumor into 500 Sherman strain rats. The transplants grew in 100 percent of host animals but regressed in 2 percent of them. The tumor became of palpable size one week following inoculation, and it killed the host animal within six weeks, at which time it measured about 5 cm. in diameter.

DESCRIPTION OF CURRENT TUMOR. A 15-day-old subcutaneous transplant tumor is described as firm, round, lobulated, and partially encapsulated. There is invasion of the surrounding connective tissue and muscle and occasionally of the vertebrae and spinal cord. On section, a central area of semisolid, yellowish white, necrotic material surrounded by a zone of firm, white, glistening, viable tumor is generally present. Metastatic growths of the tumor are regularly found in the regional lymph nodes and occasionally in the retroperitoneal lymph nodes and lungs.

On microscopic examination, the Walker Carcinosarcoma 256 is seen to be composed of three types of cell. Two of the three types of cell may form an independent pattern, or all three types may be intermingled. The two architectural patterns, carcinoma and sarcoma, may stand alone or may form a mixed type of growth, a carcinosarcoma (fig. 204). Differences in the number and character of the blood vessels and in the extent of necrosis appear to be somewhat interrelated, and these differences are in turn related to the age of the transplant, the cell population, and the pattern of growth.

The capsule of the transplant tumor is composed of edematous granulation tissue. The portion of the viable tumor tissue nearest the capsule reveals a predominantly carcinomatous pattern, while the portion nearest the large central necrotic area is for the most part sarcomatous in appearance. Aside from

the large central area of necrosis, the tumor tissue contains numerous small foci of necrosis.

The **carcinomatous variant** of the Walker 256 (fig. 205) is composed of broad sheets or clumps of so-called "principal cells," which are supported by a small amount of connective tissue stroma containing few collagenic fibers but many reticular fibers. Interspersed among these principal cells are the so-called "undifferentiated cells," which are small and deeply stained. The vessels are of capillary size, not very numerous, and rarely thrombosed. They are more dilated near the numerous small foci of necrosis. Acini are not present in this transplant tumor in the rat, although they have been described in transplants of the Walker 256 tumor grown on the chorioallantoic membrane of the chick.

The principal cell is polygonal, round or oval, and has an indistinct cell membrane. The cytoplasm is granular, basophilic, and sometimes vacuolated (fig. 206). There is usually one centrally located nucleus that may be round or oval and sometimes indented. Occasionally 2 or 3 nuclei are present. The deeply stained nuclear membrane encloses a fine linin mesh and 1 to 4 small clumps of chromatin. There is generally one large eosinophilic nucleolus. Three or four mitotic figures, often tripolar, may be found in nearly every high power field. The individual principal cells are often found to be in various stages of degeneration, necrosis, and resorption, and many clear spaces in the tumor seem to represent the sites previously occupied by them. The principal cell as it undergoes this series of regressive changes becomes surrounded by satellite cells (fig. 207). Some of the satellite cells are round and possess a nucleus resembling that of the principal cell, while others resemble the so-called "undifferentiated cell."

The undifferentiated cell appears most frequently in the portion of the tumor tissue that has a carcinomatous pattern, although it is also a component of the other two histologic patterns—sarcoma and carcinosarcoma. This cell is small, deeply staining, and round, polygonal, elongated, or dendritic. It has a thin rim of cytoplasm that often forms the dendritic processes. The nucleus is hyperchromatic and contains a coarse linin network beaded with clumps of chromatin. This undifferentiated cell may or may not be associated with collagenic and reticular fibers. It may occur singly, in groups, or in a linear arrangement within the stroma.

The **sarcomatous variant** of the Walker 256 has a pattern of interlacing bundles of spindle-shaped and stellate cells with long processes (fig. 208). The spindle-shaped cells exhibit the characteristics of neoplastic fibroblasts (fig. 209). Large numbers of fibroglial fibrils are demonstrated in association with the fasciculi of spindle-shaped cells. Virtually every spindle-shaped cell is surrounded by reticular fibers. Collagenic fibers are less numerous but show the same distribution. Near the numerous small foci of necrosis, the cells of the sarcoma surrounding blood vessels appear to have survived long-

WALKER CARCINOSARCOMA 256. RAT

(Tumor-bearing animal courtesy of Dr. Kanematsu Sugiura, Sloan-Kettering Institute for Cancer Research, New York City)

Figure 204. Photomicrograph of transplant tumor showing the pattern of carcinosarcoma. In the sarcomatous portion virtually every cell is surrounded by reticular fibers, whereas there is little or no penetration of the carcinomatous areas by reticulum. The carcinomatous areas are composed of cells with large nuclei that stand out prominently in this silver preparation. Wilder's silver preparation. X 260. N. C. I. 7675; A. F. I. P. Acc. No. 219934-205.

Figure 205. Photomicrograph of transplant tumor. The carcinomatous variant of the tumor is composed chiefly of principal cells. These are large cells with large nuclei that are frequently in mitosis. Interspersed among the principal cells are the undifferentiated cells which are small and deeply stained. Hematoxylin and eosin stain. X 360. N. C. I. 7676; A. F. I. P. Acc. No. 219934-206.

Figure 206. Photomicrograph of transplant tumor. This area is composed chiefly of principal cells which are large, have indistinct cell borders and sharply outlined nuclei. Interspersed among the principal cells are many undifferentiated cells. Hematoxylin and eosin stain. X 880. N. C. I. 7686; A. F. I. P. Acc. No. 219934-207.

Figure 207. Photomicrograph of transplant tumor. The remains of a swollen necrotic principal cell surrounded by satellite cells may be seen in the center of the field. At the right of this necrotic cell is a viable principal cell. The contrast between the principal cells and the satellite cells is clearly shown. Hematoxylin and eosin stain. X 420. N. C. I. 7684; A. F. I. P. Acc. No. 219934-208.

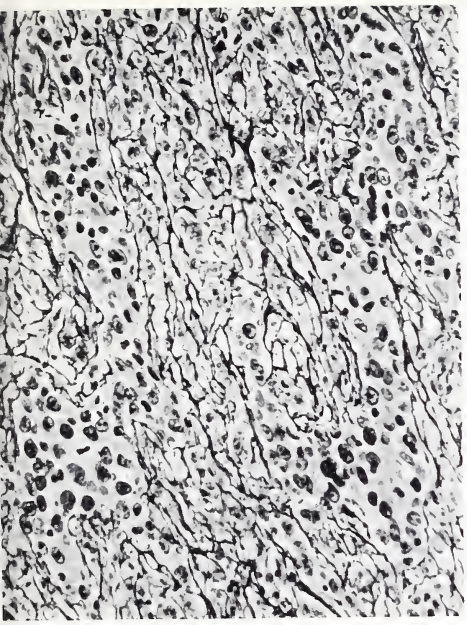

Fig. 204

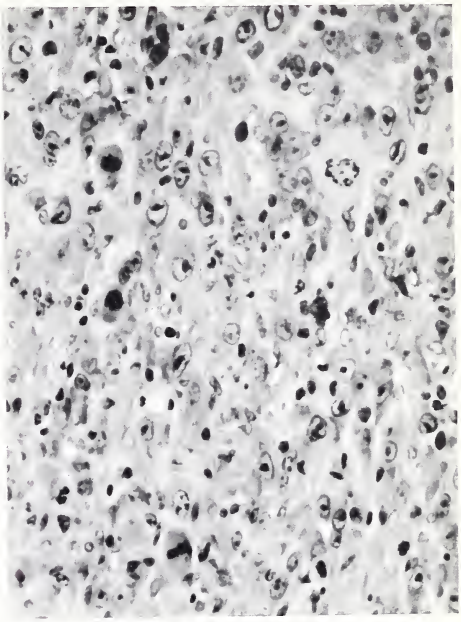

Fig. 205

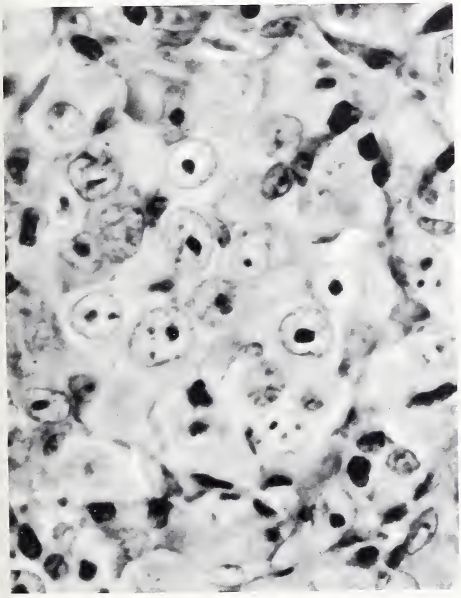

Fig. 206

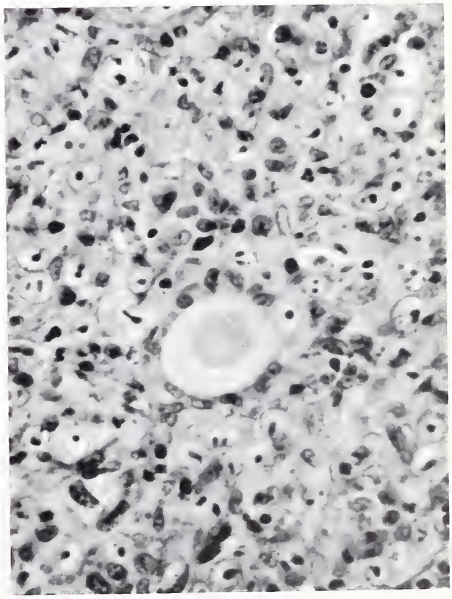

Fig. 207

WALKER CARCINOSARCOMA 256. RAT

Figure 208. Photomicrograph of transplant tumor. This area of the sarcomatous variant shows interlacing bundles of spindle-shaped cells with thin-walled dilated blood vessels. Hematoxylin and eosin stain. X 200. N. C. I. 7678; A. F. I. P. Acc. No. 219934–209.

Figure 209. Photomicrograph of transplant tumor showing fibroglial fibers associated with neoplastic spindle-shaped cells. Iron alum hematoxylin stain. X 1500. N. C. I. 7692; A. F. I. P. Acc. No. 219934–210.

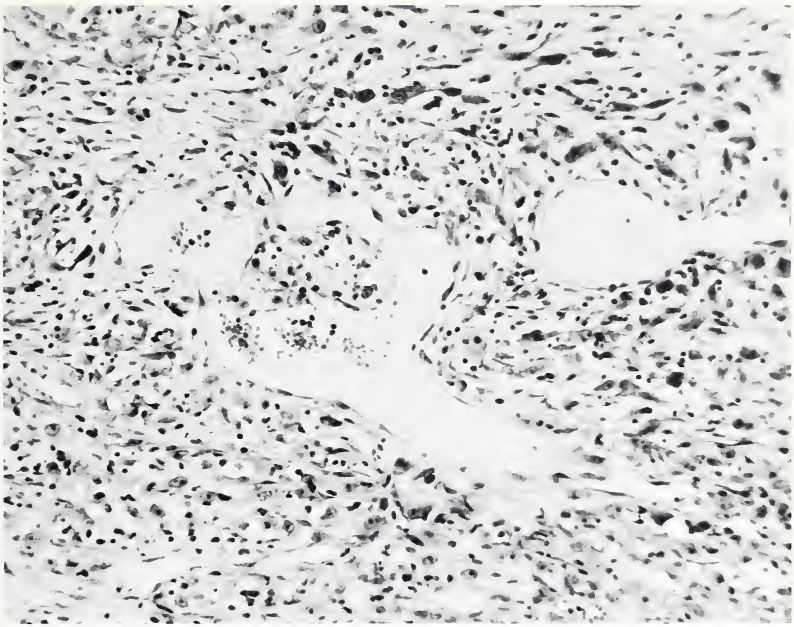

Fig. 208



Fig. 209

est. Large thin-walled telangiectatic blood vessels are numerous (fig. 208). Between an area of necrosis and the sarcomatous tissue there is a zone of small round or elongated hyperchromatic cells, the character of which is not determined.

The sarcomatous component of the tumor exhibits a predilection for the immediate vicinity of the areas of necrosis. It follows, therefore, that the bulk of the sarcomatous tissue borders upon the large central necrotic area. However, thin strands of spindle-shaped and stellate cells may be seen here and there in the carcinomatous portion of the tumor, often in relation to numerous small foci of necrosis. These strands of spindle-shaped and stellate cells are not always organized into fasciculi and may have only a few reticular and collagenic fibers associated with them. Nevertheless, we believe that such foci represent the beginning stage of sarcoma. This early sarcomatous change often develops in relation to the small blood vessels of the carcinomatous area and appears to spread toward the necrotic areas.

During transplantation of experimental tumors, a transformation from carcinoma to sarcoma may occur. A number of well authenticated examples of this phenomenon have been published. Upon serial transplantation, the pulmonary tumor, the hepatoma, and the mammary adenocarcinoma of the mouse have all been known to develop a sarcomatous pattern. When once this change has taken place, these tumors do not revert to their former carcinomatous pattern. However, the Walker 256 tumor is unique in that it appears to recapitulate in each transplant generation its natural history of change from carcinoma to sarcoma. At first, the young transplant of the Walker 256 is chiefly carcinomatous, but as the transplant grows older it develops a sarcomatous pattern around blood vessels and around areas of necrosis. The sarcomatous tissue spreads to the periphery of the growth to crowd out the remaining shell of carcinomatous tissue. Since the spindle-shaped cells invade areas of necrosis, the process has been referred to as "healing." It has been possible to obtain a carcinoma from a transplant composed of the fibrosarcomatous variant of the Walker 256. As described by various observers in different laboratories, the Walker 256 has presented different combinations of carcinoma and sarcoma under varying conditions.

The material at hand and the methods of study employed have been inadequate to establish the relationship, if any exists, between the different cell types of the tumor and the different histologic patterns that it may exhibit. There are certain obvious possibilities. The Walker 256 may have originated as a mixed tumor, a hypothesis not inconsistent with its origin from the mammary gland, since primary breast tumors of mixed pattern have been described both in man and in lower animals including the rat. On the other hand, there may be a multipotential cell in the Walker 256 tumor from which all other types of cell in this tumor are derived. Answers to this problem might be sought by using the technic of Sanford and associates to isolate a single

cell in tissue culture. It might then be possible to determine whether the tumor that develops at the site of inoculation of such cultured tumor tissue derived from this single cell would exhibit the mixed histologic patterns of the present Walker 256.

References

Dunn, T. B. Morphology and histogenesis of mammary tumors. In: Moulton, F. R. (ed.). Mammary Tumors in Mice, pp. 13–38. A. A. A. S. Publication no. 22, 1945.

Earle, W. R. A study of the Walker rat mammary carcinoma 256, in vivo and in vitro. Am. J. Cancer, 24:566–612, 1935.

Likely, G. D., Sanford, K. K., and Earle, W. R. Further studies on the proliferation in vitro of single isolated tissue cells. J. Nat. Cancer Inst., 13:177–184, 1952.

McCoy, T. A., and Neuman, R. E. The cultivation of Walker carcinosarcoma 256 in vitro from cell suspensions. J. Nat. Cancer Inst., 16:1221–1229, 1956.

Mider, G. B., Tesluk, H., and Morton, J. J. Effects of Walker Carcinoma 256 on food intake, body weight and nitrogen metabolism of growing rats. Acta Unio internat. cancr., Louvain, 6:409–420, 1948.

Sanford, K. K., Earle, W. R., and Likely, G. D. The growth in vitro of single isolated tissue cells. J. Nat. Cancer Inst., 9:229-246, 1948.

Schrek, R. A quantitative study of the growth of the Walker rat tumor and the Flexner-Jobling rat carcinoma. Am. J. Cancer, 24:807–822, 1935.

Sugiura, K. Personal communication.

———, and Stock, C. C. Studies in a tumor spectrum. I. Comparison of the action of methylbis (2-chloroethyl) amine and 3-bis (2-chloroethyl) aminomethyl-4-methoxymethyl-5-hydroxy-6-methylpyridine on the growth of a variety of mouse and rat tumors. Cancer, 5:382–402, 1952.

TUMORS OF THE ENDOCRINE GLANDS

TUMORS OF THE ADRENAL GLANDS

Adrenal Cortical Carcinoma WK1546. Mouse

DEFINITION. A carcinoma of the cortex of the adrenal gland that arose in a gonadectomized female (DBA x CE)F_1 mouse.

HISTORY AND DESCRIPTION OF ORIGINAL TUMOR. Adrenal Cortical Carcinoma WK1546 was found on January 23, 1950, at necropsy of an 18-month-old female (DBA x CE)F_1 hybrid mouse, that had had the ovaries removed at two days of age. The experiment was performed by Margaret Dickie of the Jackson Memorial Laboratory in Bar Harbor, Maine, who gave us histologic sections of the original tumor and a description of the necropsy findings. The left adrenal gland measured 15 x 10.6 x 9.7 mm. and was replaced by firm grayish white tumor tissue. It was from this lesion that the adrenal tumor WK1546 was derived. The right adrenal gland also contained tumor tissue. The vagina was only partially open. The clitoral glands and uterus were small. There was dilatation and downward extension of the uterine glands and mucification of the vaginal epithelium. The submaxillary glands were large, light in color, and of the masculine type. The cells lining the terminal tubules of these glands were heightened, their nuclei were basal, and there was increased cytoplasmic granularity. The pituitary gland was slightly enlarged. The thyroid gland was of normal size, and the lungs revealed pneumonia.

Histologic sections show tumors in both adrenal glands. The left adrenal gland, from which the transplantable tumor WK1546 was derived, is almost entirely replaced by neoplastic tissue, leaving only a narrow subcapsular remnant of adrenal cortical tissue intermingled with a few foci of pale, swollen, vacuolated cells containing yellowish brown pigment. This original tumor of the left adrenal gland is composed of three types of neoplastic tissue (fig. 210). The first type, located near and within the capsule, consists of a few glandular or small cystic structures lined with small cells with exceedingly hyperchromatic nuclei. The second type of tumor tissue consists of a small focus of atypical glandular structures lined with a syncytial type of neoplastic cell. These glandular structures resemble atrophic testicular tubules and are reminiscent of the common embryonic origin from the genital ridge of both the cortex of the adrenal gland and the testis. It is sometimes difficult to distinguish between the two foregoing types of neoplastic tissue. The third neoplastic component of the tumor constitutes the bulk of the tumor in the left

adrenal gland and is composed of cells that resemble those of the present transplantable tumor to be described. These cells of the third histologic type are arranged in cords, nodules, and sheets separated from each other by narrow strands of richly vascularized stroma. The zona glomerulosa of the remnant of the left adrenal gland (mentioned previously) is largely replaced by small darkly stained cells that resemble cells often observed in the same location in the adrenal glands of senile mice. There is a close resemblance between these small darkly stained cells and those of the third neoplastic component.

The right adrenal gland is largely replaced by tumor tissue composed of four distinctive types (fig. 211), three of them resembling in part the three types of neoplastic tissue found in the left adrenal gland (fig. 210). A fourth portion of the tumor of the right adrenal gland is composed of cords of pale polygonal cells, some of which vary moderately in size, shape, and staining capacity. These cells closely resemble those of the zona fasciculata of the cortex of the adrenal gland.

TRANSPLANTATION STUDIES. Fragments of WK1546 were transplanted subcutaneously into intact (DBA x CE)F_1 hybrid mice. Eight months after transplantation a tumor could be palpated at the site of inoculation. Subsequently, the tumor was transplanted at intervals of 6 to 9 months, which is the time required for it to reach a diameter of 2 cm. In July 1954, the tumor was in its 8th transplant generation. It can be maintained in either intact or in castrated (DBA x CE)F_1, or (CE x DBA)F_1 hybrid mice.

DESCRIPTION OF CURRENT TUMOR. A 7th generation subcutaneous transplant tumor of Adrenal Cortical Carcinoma WK1546 in an intact mouse measures approximately 2 cm. in diameter eight months following inoculation. On section, it has the appearance of swordfish steak.

Microscopically, the cells are round, polyhedral, elongated or tadpole shaped (fig. 212). The nucleus may be centrally or peripherally placed and occupies the bulbous end of the tadpole-shaped cell. For the most part, the cells are arranged in sheets. However, cells that are tadpole shaped, cuboidal, or columnar often radiate from the blood vessels or from a central strand of collagen, forming a palisade pattern (figs. 213, 214). Such an arrangement of cells, particularly around a single strand of collagen or a tiny blood vessel, may give the false impression of rosette formation in the hematoxylin—eosin preparation. There are a few spaces here and there suggesting poorly formed acini, but these are believed to be the result of cytolysis of individual cells in the center of a nest of tumor cells. The cytoplasm of the cells may be fibrillar, granular, or occasionally vacuolated. It may contain a granular precipitate of silver in Wilder's silver preparations. In the areas of degeneration and necrosis, the cytoplasm often contains periodic acid—Schiff-positive material which can be removed by diastase. Some of the tadpole-shaped cells terminate in fine fibrils that stain blue with phosphotungstic acid—hematoxylin and lose

themselves in the stroma or in the connective tissue that surrounds blood vessels.

The nuclei are round, oval, rod shaped, elliptical, or kidney shaped. They are uniform in staining characteristics and in internal structure, and they are nearly all the same size. The linin network is coarse, and chromatin granules are numerous, particularly near the deeply stained nuclear membrane. One or several nucleoli are present, and sometimes these are connected one with another by thick bars of chromatin. One mitotic figure can be found in every three oil immersion fields. The tumor tissue contains numerous blood vessels around which most of the stroma is concentrated. A few collagenic and reticular fibers penetrate from this stroma into the tumor tissue for a short distance but rarely surround single cells (fig. 215). There are a few small areas of degeneration, necrosis, and hemorrhage, but in general the tumor tissue is well preserved. The peripheral portions of the tumor are sharply demarcated from the surrounding host tissue by a capsule of connective tissue. A few coarse fibrous trabeculae extend from the capsule into the tumor. These are infiltrated by inflammatory cells and contain numerous dilated blood vessels, one of which is seen to be invaded by tumor cells.

Adrenal gland tumors and castration. The relationship of cancer to the glands of internal secretion has focused interest upon tumors of the adrenal gland that occur following castration. Tumors of the adrenal gland are seldom found in untreated intact mice without endocrine disturbances. Only four spontaneous tumors of the adrenal gland were found in 33,000 necropsies of the Slye colony of mice. Dalton and associates described a spontaneous transplantable adrenal cortical tumor in a 24-month-old female mouse of the C strain. Frantz and associates reported spontaneous adrenal cortical tumors in mice of the NH strain, chiefly in females. They correlated this finding with the early cessation of ovarian activity. When mice of this strain were castrated at the time of weaning, adrenal gland tumors appeared at an earlier age than in intact mice.

The response of the adrenal gland to gonadectomy is influenced to some extent by genetic factors. For example, in mice of strains C57BR/aJ and C57BL/10 Wy, the cortex of the adrenal gland becomes only slightly increased in width following this operative procedure. A more pronounced reaction, namely nodular hyperplasia of the adrenal gland cortex, develops in mice of strain DBA/2Wy following gonadectomy. In mice of strain CE/Wy or (DBA x CE)F_1 gonadectomized at birth, bilateral adrenal cortical tumors develop in 100 percent of animals within 13 months. Following the appearance of the adrenal tumor in these mice, growth and development of the accessory sex organs occur, and effects attributable to the presence of estrogenic and androgenic hormones have been recorded. Formation of these tumors can be prevented by the subcutaneous implantation of diethylstilbesterol pellets when the castrated mice are seven weeks of age. Hosts bearing transplanted

adrenal cortical tumors may sometimes exhibit overdevelopment of the secondary sex organs. However, Adrenal Cortical Carcinoma WK1546 transplanted in intact mice does not produce overt pathologic changes in the endocrine glands or in the accessory reproductive organs. When transplanted to gonadectomized mice, WK1546 does delay the formation of adrenal cortical tumors that usually follow gonadectomy. The histologic appearance of the tumor grown in intact mice closely resembles that of tumors grown in gonadectomized mice.

References

Christy, N. P., Dickie, M. M., Atkinson, W. B., and Woolley, G. W. The pathogenesis of uterine lesions in virgin mice and in gonadectomized mice bearing adrenal cortical and pituitary tumors. Cancer Research, 11:413–422, 1951.

Dalton, A. J., Edwards, J. E., and Andervont, H. B. A spontaneous, transplantable, adrenal cortical tumor arising in a strain C mouse. J. Nat. Cancer Inst., 4:329–338, 1943.

Fekete, E., and Little, C. C. Histological study of adrenal cortical tumors in gonadectomized mice of the CE strain. Cancer Research, 5:220–226, 1945.

———, Woolley, G. W., and Little, C. C. Histological changes following ovariectomy in mice. I. DBA high tumor strain. J. Exper. Med., 74:1–8, 1941.

Frantz, M., Kirschbaum, A., and Casas, C. Endocrine interrelationship and spontaneous tumors of the adrenal cortex in NH mice. Proc. Soc. Exper. Biol. & Med., 66:645–646, 1947.

Slye, M., Holmes, H. F., and Wells, H. G. Primary spontaneous tumors in the kidney and adrenal of mice. Studies on the incidence and inheritability of spontaneous tumors in mice. J. Cancer Research, 6:305–336, 1921.

Woolley, G. W. The adrenal cortex and its tumors. In: The Adrenal Cortex. Ann. New York Acad. Sc., 56 (art. 6):616–626, 1949.

———, Dickie, M. M., and Little, C. C. Adrenal tumors and other pathological changes in reciprocal crosses in mice. I. Strain DBA x strain CE and the reciprocal. Cancer Research, 12:142–152, 1952.

TUMORS OF THE PITUITARY GLAND

Furth Pituitary Tumor. Mouse

SYNONYM: Thyrotrophin-secreting pituitary tumor (Furth).

DEFINITION. A functionally active hormone-secreting tumor induced in the anterior lobe of the pituitary gland of a C57BL mouse radiothyroidectomized by I^{131}, one transplant subline of which is autonomous and grows in untreated hosts, while another is dependent and grows successfully only in radiothyroidectomized hosts.

HISTORY. Gorbman, in 1949, induced tumors in the anterior lobe of the pituitary gland of mice by the destruction of most or all of the thyroid gland following a single subcutaneous injection of I^{131}. The following year, Furth and his associates began their studies of the mechanism of production and histogenesis of this type of pituitary gland tumor, its transplantability, and its effects upon the host. They stated that such tumors induced in the adenohypophysis could be transplanted successfully into radiothyroidectomized mice but not into normal mice. Hence, successful transplantation depended upon such

ADRENAL CORTICAL CARCINOMA WK1546. MOUSE

(Histologic sections of original tumor and of 7th generation transplant courtesy of Miss Margaret Dickie, Roscoe B. Jackson Memorial Laboratory, Bar Harbor, Me.)

Figure 210. Section of original tumor in left adrenal gland of ovariectomized mouse. The capsule is at the lower right corner. The right half of the field is occupied by small glandular structures lined by small cells with hyperchromatic nuclei. The left half of the field is occupied by the third neoplastic component constituting the bulk of the tumor. In the left lower portion of the field is a cross section of a structure resembling a testicular tubule. Hematoxylin and eosin stain. X 210. N. C. I. 9365; A. F. I. P. Acc. No. 219934-211.

Figure 211. Section of right adrenal gland from ovariectomized mouse in which Adrenal Cortical Carcinoma WK1546 originated. The top center of the illustration shows two nodules of tumor tissue described as type three. This tissue constitutes the bulk of the tumor in both the right and the left adrenal glands. Extending across the middle portion of the illustration is neoplastic tissue which resembles testicular tubules and is described as type two. In the lower right is a type of neoplastic tissue composed of cords of polygonal cells closely resembling adrenal cortical tissue. This latter type of neoplastic tissue was seen only in the right adrenal gland. At the right upper margin are pigment-containing cells. Hematoxylin and eosin stain. X 110. N. C. I. 9358; A. F. I. P. Acc. No. 219934-212.

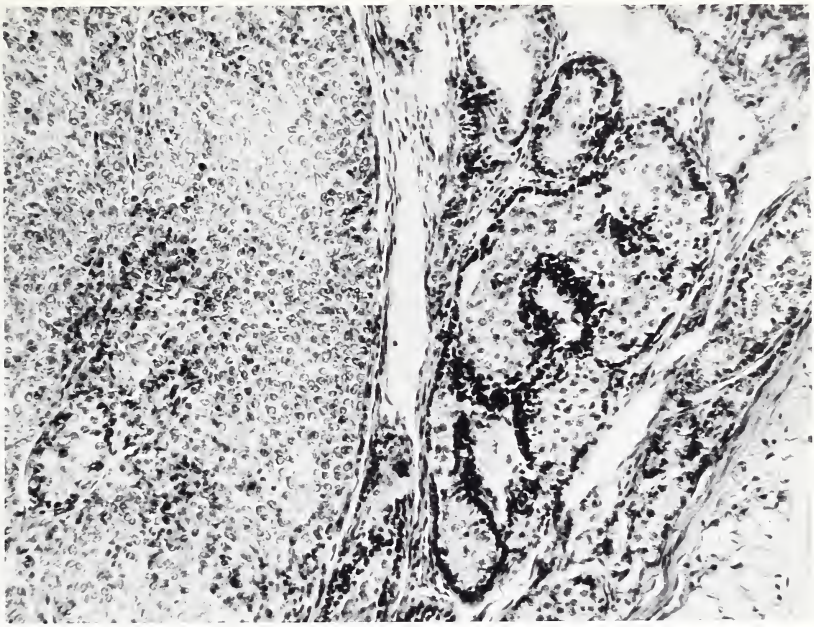

Fig. 210

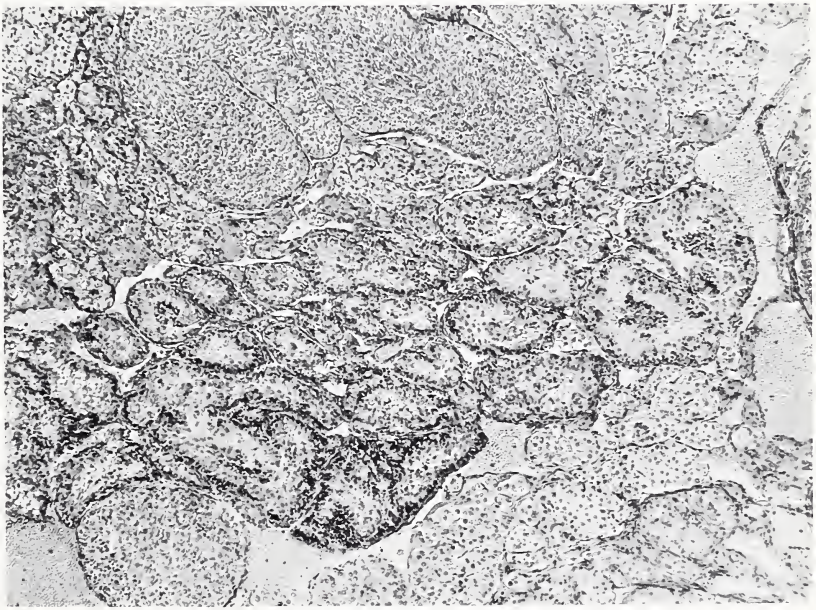

Fig. 211

ADRENAL CORTICAL CARCINOMA WK1546. MOUSE

Figure 212. Photomicrograph of 7th generation transplant tumor grown subcutaneously in an intact mouse. The tumor cells are arranged in sheets. There is little variation in the size and in the staining characteristics of the cells, although they do vary in shape. Hematoxylin and eosin stain. X 340. N. C. I. 9235; A. F. I. P. Acc. No. 219934–213.

Figure 213. Photomicrograph of 7th generation transplant tumor grown subcutaneously in an intact mouse. This area shows small foci of necrosis and hemorrhage. In the lower portion of the field are two blood vessels. Note the radial perivascular arrangement of the tumor cells. Hematoxylin and eosin stain. X 210. N. C. I. 9238; A. F. I. P. Acc. No. 219934–214.

Figure 214. Photomicrograph of 7th generation transplant tumor grown subcutaneously in an intact mouse. The various shapes of the tumor cells are shown. Note the radial arrangement of the tumor cells around a small blood vessel to the left of the center of the field. Hematoxylin and eosin stain. X 915. N. C. I. 9255; A. F. I. P. Acc. No. 219934–215.

Figure 215. Photomicrograph of 7th generation transplant tumor grown subcutaneously in an intact mouse. The reticular and collagenic fibers are not very numerous and are largely confined to the region of the blood vessels. Wilder's silver preparation. X 565. N. C. I. 9252; A. F. I. P. Acc. No. 219934–216.

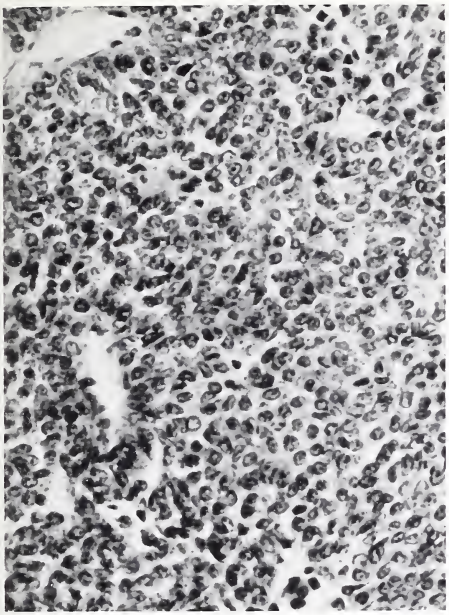

Fig. 212

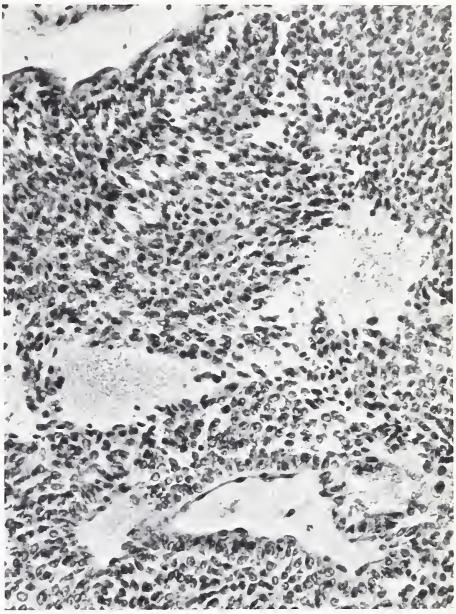

Fig. 213

Fig. 214

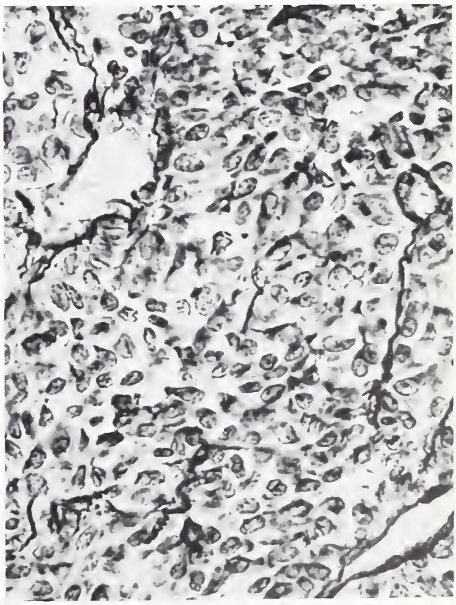

Fig. 215

radiothyroidectomy. However, they found later that some of the dependent transplant tumors acquired autonomy in the course of successive generations, for they could then be transplanted into normal host mice with intact thyroid glands. Indeed, after a few transplant passages in normal hosts, the autonomous tumors grew even better than they did in radiothyroidectomized animals.

Radiothyroidectomized mice given thyroid hormone developed no tumors of the anterior lobe of the pituitary gland. Furthermore, administration of thyroid hormone prevented the growth of transplanted dependent tumors in radiothyroidectomized hosts. By biologic assay and morphologic study, Furth showed that both the dependent and the autonomous transplant tumors secrete thyrotrophin. There is some indication that the dependent tumor may also secrete gonadotrophin. Upon acquiring autonomy, the transplanted tumor secretes less of the thyroid stimulating hormone. The acquisition of autonomy was accompanied by certain morphologic alterations in the tumor cells as well as in the stroma.

Furth and Burnett injected 200 to 400 millicuries of carrier-free I^{131} subcutaneously into C57BL mice 6 to 10 weeks of age. Most of the animals surviving 10 to 13 months after this treatment developed tumors of the anterior lobe of the pituitary gland. The investigators believed that the consequent reduction in quantity or lack of the normal thyroid hormone may have led to overstimulation of the anterior lobe of the pituitary gland, eventuating in hyperplasia and subsequent formation of a tumor. The signs of a primary carcinoma of the pituitary gland in the mouse were ruffled fur, listlessness, sudden loss of weight (pituitary cachexia), blindness, motor disturbances, and enlargement and distortion of the head with separation of the parietal and occipital bones of the skull. At necropsy, the mammary ducts of female mice were found to be hyperplastic and hypertrophic, and the ovaries were largely replaced by lutein cells.

HISTOGENESIS. Halmi and Gude studied the changes in the pituitary glands of mice at intervals following the destruction of the thyroid gland by the injection of radioiodine. They also described the alterations in the pituitary gland in intact and in radiothyroidectomized host mice bearing intramuscular transplants of pituitary tumors.

The pituitary body of the normal, nontumor-bearing mouse, according to Halmi and Gude, possesses three types of chromophil cells—alpha cells, beta cells, and delta cells. These authors stated that following radiothyroidectomy the beta cells rapidly transform into thyroidectomy cells by a process of degranulation, hyperplasia, and hypertrophy. Six months after treatment with radioiodine, multiple adenomas composed of thyroidectomy cells appear in the anterior lobe of the pituitary gland. Ten months after radiothyroidectomy, grossly visible tumors composed of similar but usually less well differentiated cells form in the pituitary gland. Halmi and Gude believed that the delta cells become hypertrophied temporarily, immediately prior to the appearance of

the adenomas. There is little change in the acidophil cells until they are crowded out by the tumor.

According to Furth, the cells that produce the thyrotrophin in the normal pituitary glands of different species he studied are probably the basophilic cells that contain periodic acid—Schiff-positive and aldehyde-fuchsin-positive material in the cytoplasm. The neoplastic cells of the pituitary tumor of radiothyroidectomized mice, on the other hand, do not exhibit these characteristics. However, it is clear from evidence of bioassay that the transplanted dependent pituitary tumors secrete large amounts of the thyroid stimulating hormone but small amounts if any of other hormones. These tumors per unit weight secrete 5 to 10 times as much thyroid-stimulating hormone as does the normal pituitary gland. Pituitary tumors that secrete thyroid-stimulating hormone have not previously been identified in an animal other than the mouse.

Dent and his associates have found more recently that a small dose of I^{131} (50 millicuries in male mice and 25 millicuries in female mice), much less than that used originally by Gorbman and by others, is sufficient to lead to the production of similar tumors in the pituitary gland. The fact that tumors of the pituitary gland also develop in mice following nearly complete surgical thyroidectomy indicates that radioiodine may not be essential in the induction of the pituitary tumors except for the destruction of the parenchymal tissue of the thyroid gland.

DESCRIPTION OF ORIGINAL TUMOR (FURTH'S LINE 3). The animal from which Furth's Line 3 thyrotrophin-secreting pituitary tumor was derived had a nodular tumor 1.0 cm. in diameter that replaced the pituitary gland, displacing the surrounding intracranial structures. Although the cerebral hemispheres were compressed and distorted, the growth did not invade the brain, nor did it erode bone.

No separate histologic description of the original line 3 tumor was made. However, Halmi and Gude did describe the histology of tumors of the pituitary gland that developed 10 months or more following radiothyroidectomy. In all of the animals examined, the normal structure of the pituitary body was almost obliterated. Remnants of the original parenchyma containing granulated acidophil cells could be identified in the peripheral areas in some cases. The bulk of the tumor was composed of cells resembling small thyroidectomy cells that could not be colored by the periodic acid—Schiff reagent or by aldehyde fuchsin. Certain cells resembling the delta cell and containing periodic acid—Schiff-positive granules were found interspersed among the predominating chromophobe cells. A few cells that contained periodic acid—Schiff-positive intranuclear inclusions were present. The tumor cells were usually uniform in appearance, and few mitotic figures were to be found. A few follicle-like formations were present. In general, the histologic features of these original growths of the pituitary gland were similar to those of the subsequently transplanted dependent tumors.

TRANSPLANTATION STUDIES. The Furth Line 3 thyrotrophin-secreting tumor of the anterior lobe of the pituitary gland was 1 of 10 primary tumors transplanted by the intramuscular inoculation of fragments of the original tumor into host mice pretreated with sufficient I^{131} to destroy the thyroid gland. These tumor transplants grew successfully in nearly 100 percent of mice pretreated with I^{131}. Fragments of the primary tumor transplanted into normal intact hosts failed to grow. The latent period ranged from 117 to 268 days in the 1st transplant generation but was later reduced to a period of 90 to 120 days.

One subline of this tumor, designated Line 3A, became independent of radiothyroidectomy after several transplant generations, so that it could then be transplanted successfully to normal intact host mice. When tumor Line 3A first acquired autonomy, the latent period of growth was 150 to 240 days, but in later transplant passages the latent period was only 45 to 90 days. Upon the acquisition of autonomy, the transplant tumors produced less thyrotrophin.

According to Halmi and Gude, both the dependent and the autonomous transplant tumors exert an effect on the pituitary gland of the host mouse whether the animal is intact or radiothyroidectomized. They found that all three types of chromophil cells of the pituitary gland, especially the alpha cells, were depressed when the autonomous tumor was grafted into normal intact hosts. The progress of the changes that occur in the cell population of the pituitary gland in thyroidectomized mice was said to be arrested, and there was some degree of reversal of these changes in hosts bearing either dependent or autonomous tumors. Halmi and Gude found a partial reappearance of beta granules in the thyroidectomy cells and a regression of the delta cells. However, this influence was apparently insufficient to inhibit the neoplastic process in the pituitary gland, for 2 of 7 such hosts bearing transplants of autonomous tumors developed growths in their pituitary glands that histologically resembled malignant neoplastic tissue.

DESCRIPTION OF THE CURRENT TRANSPLANT DEPENDENT TUMOR (FURTH'S TUMOR #JB2014 OF LINE 3). An intramuscular transplant of the dependent pituitary tumor is gray and firm and shows little necrosis. It has been found that the tumor occasionally metastasizes to lymph nodes.

Microscopically, the dependent tumor is surrounded by a capsule of connective tissue which is infiltrated with tumor tissue in some areas. The capsule contains inflammatory cells, extravasated blood, and pigment-containing phagocytes. Prolongations of the capsular stroma, containing skeletal muscle fibers in various stages of degeneration, extend into the tumor tissue, dividing it into coarse lobules 0.5 to 2.0 mm. or more in diameter (fig. 216). The tumor has an epithelial pattern (fig. 217), consisting of large and small acini and nests of cells (fig. 218) in a vascular stroma of connective tissue containing collagenic and reticular fibers. In periodic acid—Schiff preparations, phagocytes containing purplish red granular pigment appear in the stroma sometimes inter-

spersed among the tumor cells. The lining cells of the glandlike structures are often arranged as papillary excrescences. The lumens of these structures frequently contain well preserved red blood cells (fig. 219), suggesting circulating blood rather than hemorrhage. Some of the vascular channels are occupied by fresh or partially organized thrombi.

The majority of the neoplastic cells of the dependent tumor measure 30 microns in diameter and are uniform in appearance (fig. 220). Other neoplastic cells are larger and show marked variation in size and shape (fig. 221). In the solid portions of the tumor, the cells are tightly packed and polygonal, but in the lining of glandular spaces they may be cuboidal or columnar. One third to one half of the volume of the small neoplastic cell is occupied by its hyperchromatic nucleus. It possesses a deeply stained nuclear membrane enclosing small masses or granules of chromatin, most numerous near the cell membrane. There is usually an irregularly shaped, centrally placed nucleolus. The cytoplasm stains deeply, often irregularly, is either granular or homogeneous, and occasionally vacuolated.

There is a difference in the degree of cytoplasmic vacuolization of this dependent Furth Tumor #JB2014 as compared with another dependent Furth Tumor #RF Line 3 which is currently being studied cytologically by MacCardle of this laboratory. A section of #RF Line 3 fixed in Cajal's uranium nitrate—formalin and colored by Masson's trichrome method is found to be composed chiefly of large cells with extensively vacuolated cytoplasm (pl. IV–E, F). These cells appear to be palisaded in rows along the blood vascular channels. They contain coarse red granules colored with ponceau de xylidine which are scattered throughout the cytoplasm rather than being compact in solid masses. There are a few areas of the nonvacuolated cells such as are found in the #JB2014 tumor.

The large irregular neoplastic cell of dependent tumor #JB2014 possesses a hyperchromatic nucleus several times larger than that of the smaller tumor cell. These large nuclei often have 1, 2, or 3 round, acidophilic, intranuclear inclusion bodies. There are not many mitotic figures in the neoplastic cells, and almost all of them have a normal appearance. In addition to the cells described, a few of the lobular areas of the tumor are composed of cells that closely resemble those of the normal pituitary gland. These cells are small and of uniform appearance and are colored more deeply than those of the remainder of the tumor. In Mallory's aniline blue preparation, the cytoplasm of these cells is either deep blue and homogeneous or bright red and granular.

Regressive changes may be seen in scattered individual neoplastic cells. Large portions of some lobules are necrotic and may reveal hemorrhage, pigment deposition, and what appears to be reactive fibrosis. Channels resembling lymphatic vessels may contain isolated individual tumor cells and small clumps of tumor cells.

FUNCTIONAL EFFECTS OF DEPENDENT TUMOR. In hosts pretreated with I^{131} and bearing dependent pituitary gland tumors, striking morphologic alterations occur in certain organs and tissues distant from the site of growing transplant tumors. These changes consist of cystic dilatation of the biliary tract, retrogressive changes in the reticular zone of the adrenal gland, atrophy of the thymus gland, gonadal stimulation and, in the female, hyperplasia of the ducts of the mammary gland. The presence of these secondary effects that are thought to be hormonal in nature places this tumor in the category of functionally active neoplasms.

DESCRIPTION OF THE CURRENT TRANSPLANT AUTONOMOUS TUMOR (FURTH'S TUMOR #JB2005 OF LINE 3). An intramuscular transplant of this autonomous tumor is firm and variegated in appearance. It has been observed that this tumor occasionally metastasizes to the ovaries, liver, and regional lymph nodes. The metastatic deposits of the autonomous tumor in the regional lymph nodes are likely to be larger than those of the dependent tumor in this location.

The histologic pattern of the autonomous tumor differs in some respects from that of the dependent tumor. Necrosis and hemorrhage are more extensive and iron and periodic acid—Schiff-positive pigment more abundant in the autonomous than in the dependent tumor. The autonomous tumor is traversed by septa of connective tissue which are not as uniform as those observed in the dependent tumor. There is also a more marked desmoplastic reaction. At several points the capsule of the autonomous tumor is thin, and neoplastic cells are present in the surrounding host tissue.

The neoplastic cells of the autonomous tumor are more hyperchromatic (figs. 222, 223) and more uniform in size than those of the dependent tumor. There are also more mitotic figures. Only a few of the very large multinucleated giant cells with strikingly prominent nucleoli are seen, whereas there are many in the dependent tumor. The prevailing pattern in the autonomous tumor is that of nests of cells surrounded by stroma. In addition, there are acinar spaces, some of which appear to be serving as blood channels. In most of these spaces the red blood cells are well preserved, while a few may contain thrombi. Papillary structures are also present, and each of these is supported by a central core of connective tissue containing a thin-walled blood vessel that may be permeated by tumor cells.

A peculiar, sharply circumscribed, nodular, necrotic lesion occurs in the autonomous tumor (fig. 224). The shadowy outline of the nucleus is discernible and the cytoplasmic portion of the cell contains numerous granules. These cytoplasmic granules are deeply basophilic with the hematoxylin—eosin stain, purplish red with the periodic acid—Schiff reaction, and blue in the Prussian blue reaction. Remnants of degenerated collagenic and reticular fibers can be identified among necrotic cells in this lesion. This necrotic

lesion, of which the nature and pathogenesis are not clear, may represent collections either of necrotic iron-containing phagocytes within the stroma or of necrotic tumor cells.

A section of another autonomous tumor from Furth #JB101A, colored by Masson's method by MacCardle, reveals that in the nuclei of several of the large cells there is a large, irregular, pinkish mass (pl. IV–C, D). The center of this mass is sometimes granulated and separated from the outer portion of the mass by a clear area. Many areas of this autonomous tumor resemble the histologic structure of the nontumorous pituitary gland of the radiothyroidectomized mouse (pl. IV–B). The cells are very large, and the Golgi apparatus is hypertrophied as compared with the structure of the alpha cells of the normal pituitary gland (pl. IV–A).

SPECIAL FEATURES OF THE AUTONOMOUS TUMOR. The autonomous pituitary gland tumor, like the dependent tumor, can be classified as a functionally active neoplasm, although its effects upon the host are decidedly different from those of the latter. In intact hosts bearing the autonomous transplant tumor, degenerative changes occur in the adrenal gland. The pancreas is gray-pink and enlarged and shows hyperplasia of exocrine cells in which fusiform cleftlike spaces are seen. The thyroid gland enlarges and may show the development of tumors, some of which appear to be adenomas, while others, which occasionally metastasize to lymph nodes, must be considered to be malignant. These effects on the thyroid gland indicate a response to excessive secretion of thyrotrophin by the grafted autonomous pituitary gland tumor. Under certain circumstances, some mice bearing the autonomous transplant tumor die suddenly with manifestations suggestive of acute thyrotoxicosis. The blood volume of intact mice bearing autonomous tumors is almost double that of radiothyroidectomized hosts. However, the characteristic gross and microscopic features of hypervolemia are absent, indicating that the increase in the blood volume is only moderate as compared to that of mice with granulosa cell tumors. The gonads are not stimulated, the thymus gland may be normal or atrophic, and biliary tract dilatation is absent or minimal.

References

Dent, J. N., Gadsden, E. L., and Furth, J. On the relation between thyroid depression and pituitary tumor induction in mice. Cancer Research, 15:70–75, 1955.

———, Gadsden, E. L., and Furth, J. Further studies on induction and growth of thyrotropic pituitary tumors in mice. Cancer Research, 16:171–174, 1956.

Furth, J. Morphologic changes associated with thyrotrophin-secreting pituitary tumors. Am. J. Path., 30:421–463, 1954.

———, and Burnett, W. T., Jr. Hormone-secreting transplantable neoplasms of the pituitary induced by I^{131}. Proc. Soc. Exper. Biol. & Med., 78:222–224, 1951.

———, Burnett, W. T., Jr., and Gadsden, E. L. Quantitative relationship between thyroid function and growth of pituitary tumors secreting TSH. Cancer Research, 13:298–307, 1953.

FURTH PITUITARY TUMOR. MOUSE

(Fixed tissue courtesy of Dr. Jacob Furth, Children's Cancer Research Foundation, Boston, Mass.)

Figure 216. Photomicrograph of dependent transplant tumor JB2014 showing coarse lobular pattern with thick septa-like capsular prolongations containing degenerated skeletal muscle fibers. Hematoxylin and eosin stain. X 50. N. C. I. 8290; A. F. I. P. Acc. No. 219934–217.

Figure 217. Photomicrograph of dependent transplant tumor JB2014 showing the arrangement of the cells to form an epithelial pattern. The nests of cells are surrounded by reticular fibers. Wilder's silver preparation. X 210. N. C. I. 8293; A. F. I. P. Acc. No. 219934–218.

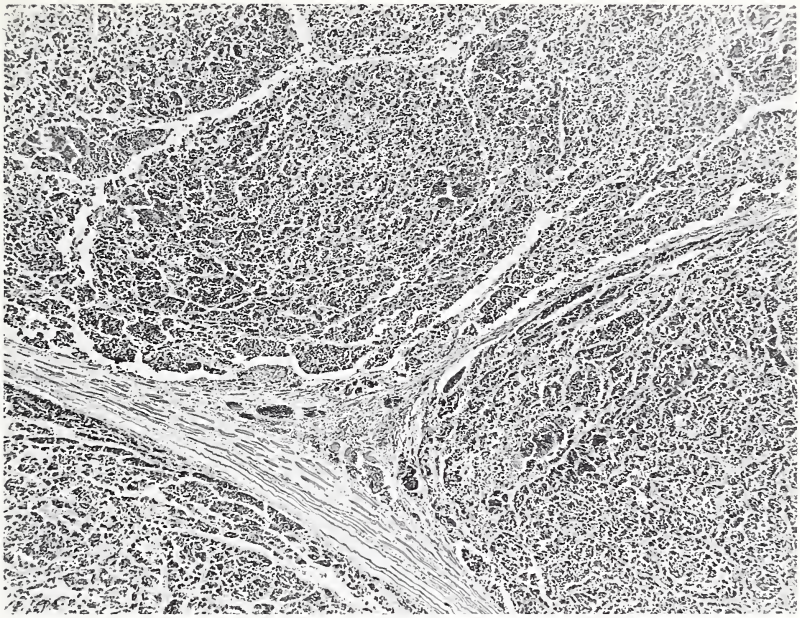

Fig. 216

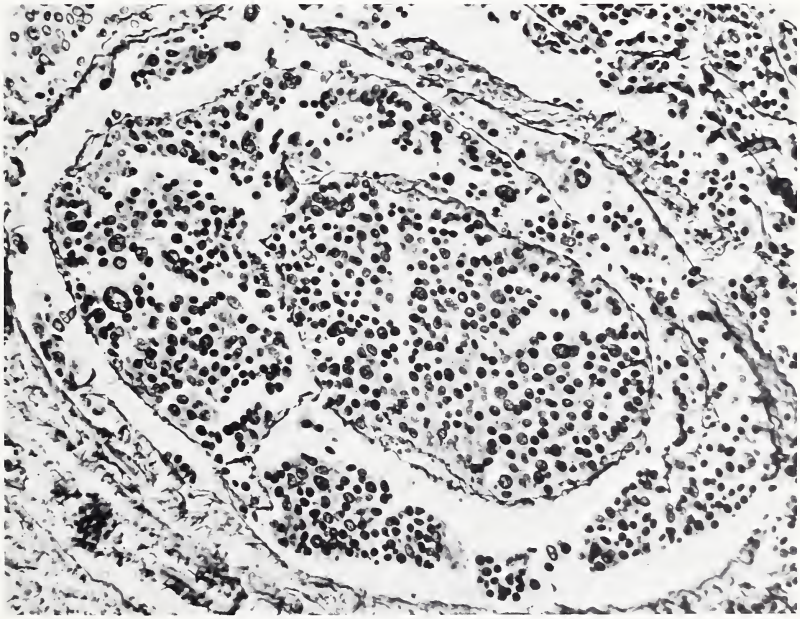

Fig. 217

FURTH PITUITARY TUMOR. MOUSE

Figure 218. Photomicrograph of dependent transplant tumor JB2014 with a large acinus showing the neoplastic cells in papillary arrangement. Hematoxylin and eosin stain. X 270. N. C. I. 8294; A. F. I. P. Acc. No. 219934–219.

Figure 219. Photomicrograph of dependent transplant tumor JB2014. In the upper portion of the field there is a blood-filled vascular channel lined with neoplastic cells. Hematoxylin and eosin stain. X 370. N. C. I. 8296; A. F. I. P. Acc. No. 219934–220.

Figure 220. Photomicrograph of dependent transplant tumor JB2014. This area shows both the small type of neoplastic cell, which is more numerous, and also the larger type of cell. Hematoxylin and eosin stain. X 370. N. C. I. 8295; A. F. I. P. Acc. No. 219934–221.

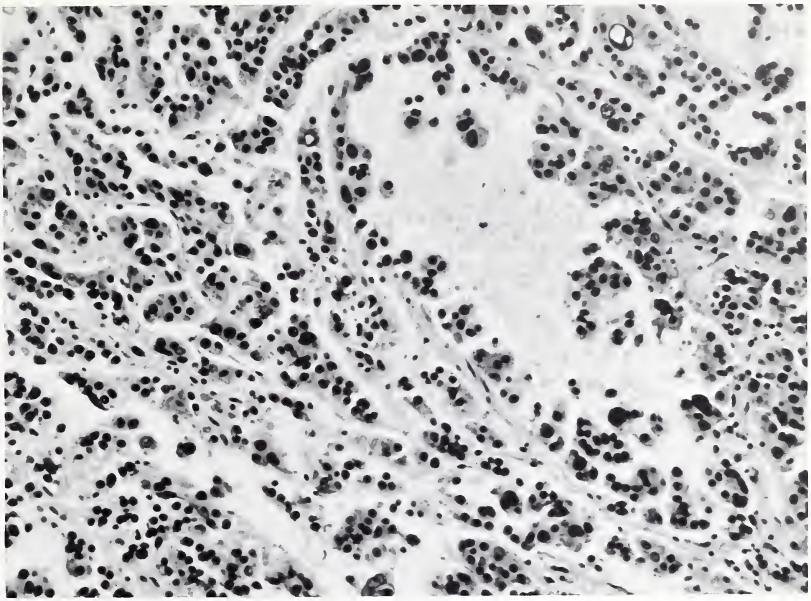

Fig. 218

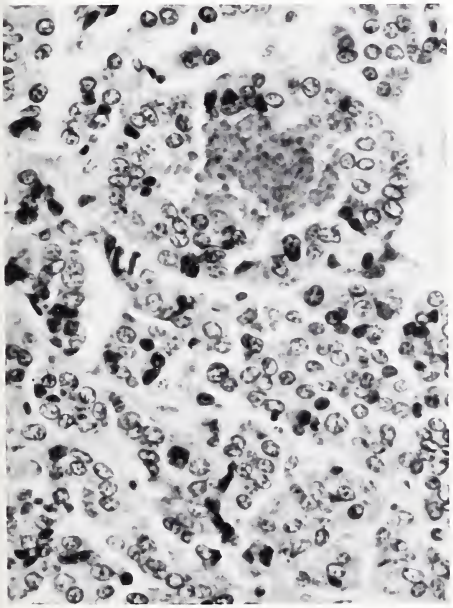

Fig. 219

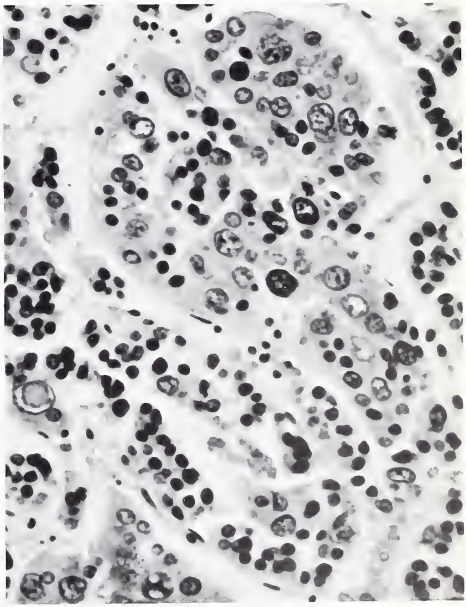

Fig. 220

FURTH PITUITARY TUMOR. MOUSE

Figure 221. Photomicrograph of dependent transplant tumor JB2014. This higher magnification shows the contrast between the small type and the large type of neoplastic cell. Hematoxylin and eosin stain. X 700. N. C. I. 8297; A. F. I. P. Acc. No. 219934–222.

Figure 222. Photomicrograph of autonomous transplant tumor JB2005 showing the appearance and arrangement of the cells. The large nest at the center is surrounded by a thin strand of connective tissue stroma. Hematoxylin and eosin stain. X 735. N. C. I. 8329; A. F. I. P. Acc. No. 219934–223.

Figure 223. Photomicrograph of autonomous transplant tumor showing the distribution of the reticular fibers in relation to the nests of tumor cells. Wilder's silver preparation. X 260. N. C. I. 8321; A. F. I. P. Acc. No. 219934–224.

Figure 224. Photomicrograph of autonomous transplant tumor JB2005 showing the peculiar, sharply circumscribed, iron-containing necrotic lesion. Hematoxylin and eosin stain. X 210. N. C. I. 8320; A. F. I. P. Acc. No. 219934–225.

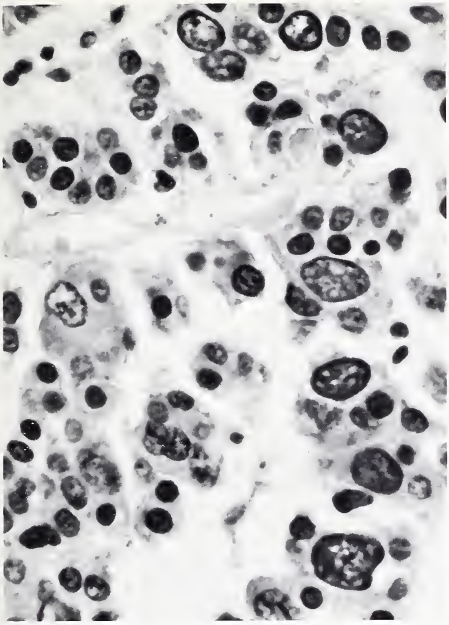

Fig. 221

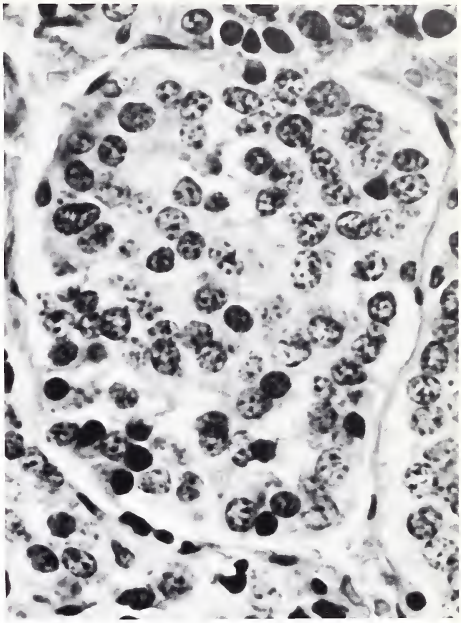

Fig. 222

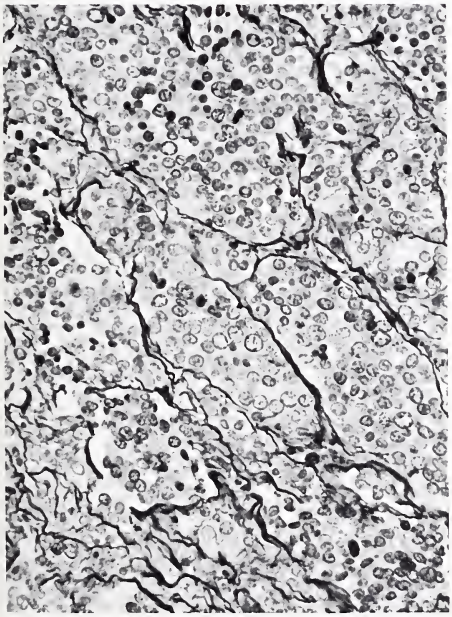

Fig. 223

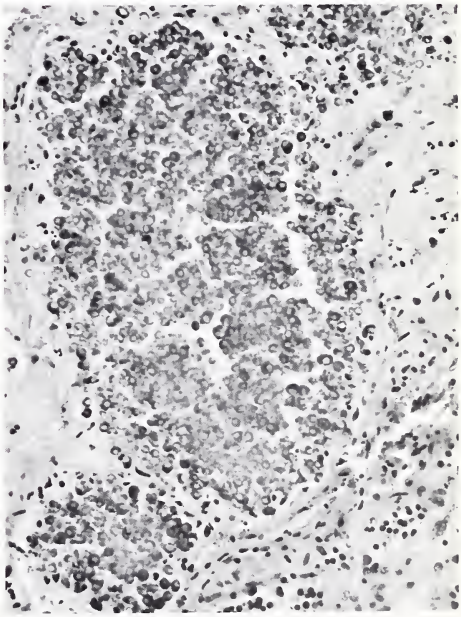

Fig. 224

PLATE IV

FURTH PITUITARY TUMOR. MOUSE

(Histologic sections courtesy of Dr. R. C. MacCardle, National Cancer Institute, Bethesda, Md.; tumor-bearing animals courtesy of Dr. Jacob Furth, Children's Cancer Research Foundation, Boston, Mass.)

A. Photomicrograph of the anterior lobe of the pituitary gland of a normal mouse showing alpha cells colored red. (Cajal uranium nitrate—formalin fixative.) Masson's trichrome stain. X 1340. N. C. I. 9657; A. F. I. P. Acc. No. 219934-300.

B. Photomicrograph of hyperplastic anterior lobe of pituitary gland of a radiothyroidectomized mouse showing the alpha cells colored red and a large hypertrophied cell with abnormal nucleus and a few cytoplasmic granules. (Cajal uranium nitrate—formalin fixative.) Masson's trichrome stain. X 1340. N. C. I. 9658; A. F. I. P. Acc. No. 219934-301.

C. Photomicrograph of autonomous transplant pituitary tumor (Furth's #JB 101-A) grown in an intact normal host C57BL mouse. Note large cells with hypertrophied clear canals of Golgi apparatus and large intranuclear body. This tumor secretes less thyrotrophin than does the dependent tumor shown in figures E and F. No areas of tissue resembling the dependent transplant tumor could be found in this tumor. (Cajal uranium nitrate—formalin fixative.) Masson's trichrome stain. X 1850. N. C. I. 9529; A. F. I. P. Acc. No. 219934-302.

D. Photomicrograph of autonomous transplant pituitary tumor (Furth's #JB 101-A) grown in a host C57BL mouse, showing mitotic division. (Cajal uranium nitrate—formalin fixative.) Masson's trichrome stain. X 1850. N. C. I. 9621; A. F. I. P. Acc. No. 219934-303.

E. Photomicrograph of dependent transplant pituitary tumor (Furth's #RF line 3) grown in a radiothyroidectomized host RF mouse, showing enlarged cells in palisade formation against vascular spaces. Note cytoplasmic granules colored red. (Cajal uranium nitrate—formalin fixative.) Masson's trichrome stain. X 1500. N. C. I. 9532; A. F. I. P. Acc. No. 219934-304.

F. Photomicrograph of dependent transplant pituitary tumor (Furth's #RF line 3) grown in a radiothyroidectomized host RF mouse. Note vacuolization of cells compared with more compact cells of tumor in figure E. This tumor secretes more thyrotrophin than does the autonomous tumor. It contains very few islands of tissue resembling autonomous tumors. (Cajal uranium nitrate—formalin fixative.) Masson's trichrome stain. X 1500. N. C. I. 9526; A. F. I. P. Acc. No. 219934-305.

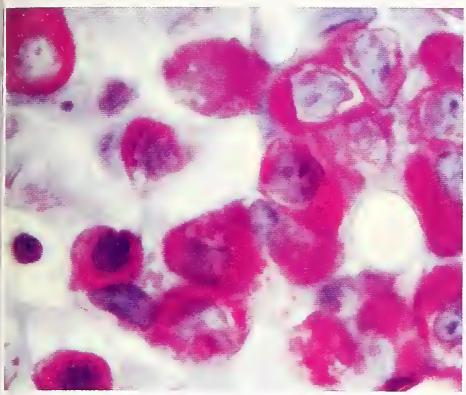

A

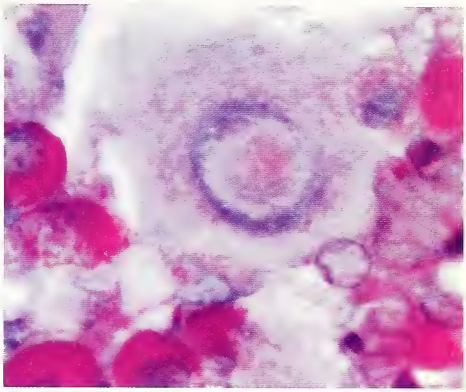

B

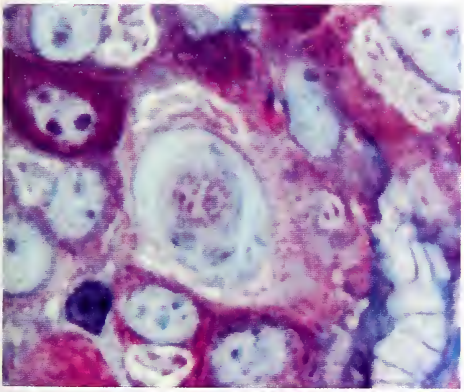

C

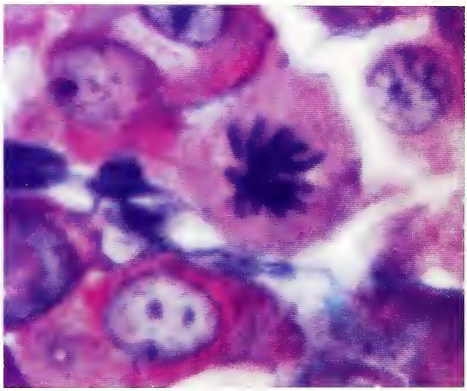

D

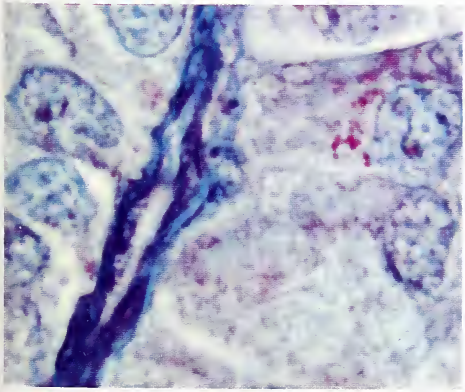

E

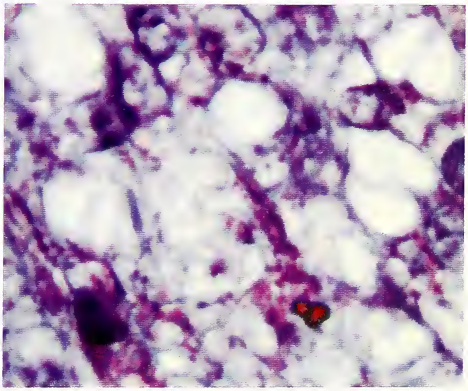

F

Plate IV

———, Gadsden, E. L., and Burnett, W. T., Jr. Autonomous transplantable pituitary tumors arising in growths dependent on absence of the thyroid gland. Proc. Soc. Exper. Biol. & Med., 80:4-7, 1952.

———, Gadsden, E. L., and Upton, A. C. Hyperplasia and cystic dilatation of extrahepatic biliary tracts in mice bearing grafted pituitary growths. Cancer Research, 12:739–73, 1952.

Gorbman, A. Tumorous growth in the pituitary and trachea following radiotoxic dosages of I^{131}. Proc. Soc. Exper. Biol. & Med., 71:237–240, 1940.

———. Pituitary tumors in rodents following changes in thyroid function: a review. Cancer Research, 16:99–105, 1956.

Halmi, N. S., and Gude, W. D. The morphogenesis of pituitary tumors induced by radio thyroidectomy in the mouse and the effects of their transplantation on the pituitary body of the host. Am. J. Path., 30:403–419, 1954.

TUMORS OF THE THYROID GLAND

Carcinoma #1. Dog

SYNONYM: Canine Carcinoma #1 (Univ. of Pennsylvania).

DEFINITION. A carcinoma that originated spontaneously in the ventral cervical region, possibly in the thyroid gland, of a boxer dog.

HISTORY AND DESCRIPTION OF ORIGINAL TUMOR. Canine Carcinoma #1 arose spontaneously in a 5½-year-old female boxer dog. Allam and his associates examined the dog February 6, 1954, at the Veterinary Hospital of the University of Pennsylvania in Philadelphia. There had been a history of cough for two weeks, listlessness, and enlargement of the ventral cervical region. Pulmonary nodules, interpreted as metastatic growths, were revealed by roentgenography. Three days after the dog had been admitted to the hospital, a biopsy was taken of the tumor in the cervical region. The animal died the following day. Necropsy disclosed a diffuse, multilobulated, soft tumor mass, which extended along the trachea from the posterior part of the larynx to the level of the thoracic inlet. The regional lymph nodes and lungs were involved with metastatic tumor tissue.

Wet tissue and histologic preparations of the primary tumor and some of the organs of the boxer dog were kindly made available to us for examination by Allam and his associates. This material included portions of pharynx, lung, and lymph node, and a piece of tumor tissue said to be from the thyroid gland.

The tumor is medullary in appearance with numerous small areas of necrosis, hemorrhage, and deposition of pigment (fig. 225). Thin-walled, often slitlike blood vessels, usually surrounded by a small amount of connective tissue, are distributed throughout all portions of the tumor. Ninety-five percent of the tumor cells are fairly uniform in size and measure approximately 20 microns in diameter. The remaining cells of the tumor are either smaller or larger than these, and there are a few giant cells containing as many as 12 nuclei (fig. 226). The tumor cells are loosely arranged and somewhat sepa-

rated from each other, due probably to shrinkage during fixation. Between the cells so separated there remain thin cytoplasmic threads connecting one cell with another. The cells are polygonal and often acutely angulated. They do not form any structure that resembles the follicle of the thyroid gland. The nucleus, which occupies approximately half of the volume of the cell, has a prominent nuclear membrane, showing concentration of chromatin material along its internal surface. The coarse linin network is dotted with chromatin granules, and frequently radiates from a large, centrally located, basophilic nucleolus. The cytoplasm is granular, sometimes vacuolated, and moderately basophilic. Some cells contain periodic acid—Schiff-positive globules within the cytoplasm. One mitotic figure may be found in each oil immersion field.

The multinucleated giant cells have small nuclei and resemble more closely the multinucleated cells of a giant cell tumor of bone than they do malignant giant tumor cells. The cytoplasm has the appearance of a feltwork. In the periodic acid—Schiff preparation, these giant cells are found to have 1, 2, or 3 long cytoplasmic processes that occasionally embrace a uninucleated tumor cell. Collagenic fibers are few in number and chiefly confined to the region of blood vessels, from which they extend for a short distance between the adjacent tumor cells. Although reticular fibers are more numerous than collagenic fibers, their distribution is similar (fig. 227). In the region of the blood vessels, reticular fibers may surround groups of tumor cells, but rarely do they surround single cells. Portions of the tumor farthest removed from blood vessels are almost devoid of reticulum.

The piece of tumor said to be from the thyroid gland shows neoplastic invasion of the surrounding fibrofatty tissue as well as of lymphatic and blood vessels, but it contains no tissue identifiable as thyroid gland. A retropharyngeal lymph node on the right side of the neck is almost completely replaced by tumor tissue. The two metastatic tumor deposits in the lung are sharply circumscribed but not encapsulated. The pattern of growth is more alveolar in appearance than that of the main tumor mass, due, it is believed, to the distribution of the tumor along the walls of the septa and within the alveoli. The submucosa of the pharynx is edematous, the veins are dilated, and there is a small neoplastic deposit located near the junction of the submucosa and muscularis.

Although the tumor is a highly undifferentiated neoplasm, there are a few areas, such as that illustrated in figure 228, where the cells are arranged in a pattern compatible with carcinoma. In most other areas, the pattern is that of a very anaplastic neoplasm. The significance of the multinucleated benign-looking giant tumor cells with feltlike cytoplasm and occasional long processes is difficult to interpret. Highly undifferentiated neoplasms as well as carcinomas with a follicular pattern may both be primary in the thyroid gland. It therefore seems reasonable to accept Canine Carcinoma #1 as an example of thyroid gland cancer in the dog, since the prosector felt that this

was indeed the case, and since there is no evidence to support the possibility of any other primary site.

TRANSPLANTATION STUDIES. A piece of the tumor tissue removed at biopsy was minced, refrigerated at 4° C., and within one hour was inoculated both subcutaneously and intraperitoneally into four puppies. All four had been pretreated with total body roentgen ray irradiation, two having received 500 r, and two, 300 r. The four puppies also received cortisone at the time of transplantation and on alternate days thereafter for a period of two weeks. The transplanted tumors grew progressively in all animals inoculated. The puppies that were treated with 500 r died or were destroyed within 27 days, and those treated with 300 r, within 46 days.

One of the puppies killed on the forty-sixth day after inoculation because of its cachectic state had both intraperitoneal and subcutaneous tumors. The subcutaneous tumor measured 4.2 x 3.3 x 3.0 cm. It was ulcerated and surrounded by hemorrhagic tissue. The intraperitoneal tumors, which varied from 0.1 to 6.0 cm. in diameter, were present in the omentum, mesentery, and intestinal serosa. The histologic pattern of these 1st generation transplants resembled that of the primary tumor.

By September 1954, the tumor had been carried through 14 generations and had grown successfully in nearly 100 percent of the animals that had received total body roentgen ray irradiation along with cortisone or hydrocortisone. The substitution of nitrogen mustard for total body irradiation failed to give comparable results. When cortisone alone was used, the transplant grew for 8 to 12 days, but regressed completely by the sixteenth day. In August 1956, Allam and associates reported transplantation of the tumor through the 30th generation. Of 324 puppies pretreated with roentgen ray irradiation (150 to 300 r), 85.8 percent developed tumors; of 26 puppies pretreated with nitrogen mustard, 69.2 percent developed tumors; and of 64 untreated puppies, 60.9 percent developed tumors. Metastatic growths occurred occasionally in the regional lymph nodes of the irradiated and of the untreated dogs but not of those given nitrogen mustard. An important problem in research on experimental tumors is to secure from a large animal a tumor that is easily transplantable. The success in transplanting Carcinoma #1 represents the first step in this direction.

DESCRIPTION OF CURRENT TUMOR. A subcutaneous tumor of the 14th transplant generation in a female puppy of mixed breed that had received 250 r total body irradiation five days prior to inoculation was first palpable on the sixth post injection day. It measured 3.9 x 2.1 x 1.1 cm. by the twenty-fifth day, the day of death. At necropsy, the tumor was grayish purple, soft, and surrounded by a zone of hemorrhage.

This 14th generation transplant of Carcinoma #1 is fairly well circumscribed by compressed fibrofatty tissue showing an inflammatory reaction. The transplanted tumor is similar in most respects to the primary tumor (figs.

CARCINOMA #1. DOG

(Fixed tissue and histologic sections courtesy of Dr. M. W. Allam, University of Pennsylvania, Philadelphia, Pa.)

Figure 225. Photomicrograph of original tumor of the boxer dog. This is a section through the tumor nodule taken from the region of the thyroid gland. The tumor shows a medullary pattern with extensive necrosis. A band of fibrofatty tissue that evidently belongs to the host is included in this field. Hematoxylin and eosin stain. X 90. N. C. I. 9301; A. F. I. P. Acc. No. 219934–226.

Figure 226. Photomicrograph of original tumor of the boxer dog. The majority of the tumor cells are uniform in size. Two multinucleated giant tumor cells may be seen. Periodic acid—Schiff preparation pretreated with diastase. X 430. N. C. I. 9290; A. F. I. P. Acc. No. 219934–227.

Figure 227. Photomicrograph of original tumor of the boxer dog showing an area of the tumor in which groups of cells are surrounded by reticular fibers suggesting a carcinomatous pattern. Wilder's silver preparation. X 610. N. C. I. 9294; A. F. I. P. Acc. No. 219934–228.

Figure 228. Photomicrograph of 14th generation transplant tumor. The tumor is medullary in appearance, and the cells are uniform in size and similar to those of the primary tumor. However, no multinucleated giant tumor cells are observed. Hematoxylin and eosin stain. X 290. N. C. I. 9308; A. F. I. P. Acc. No. 219934–229.

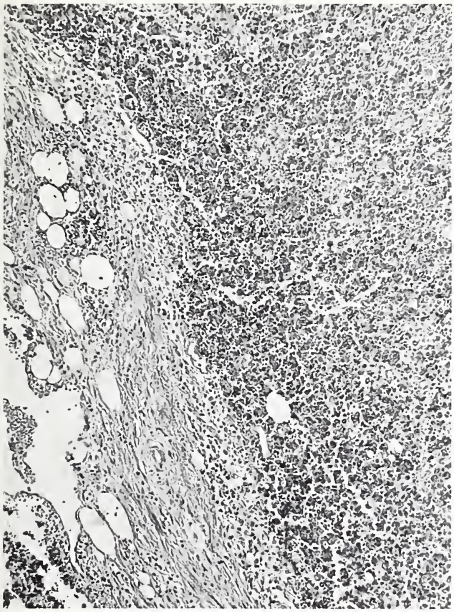

Fig. 225

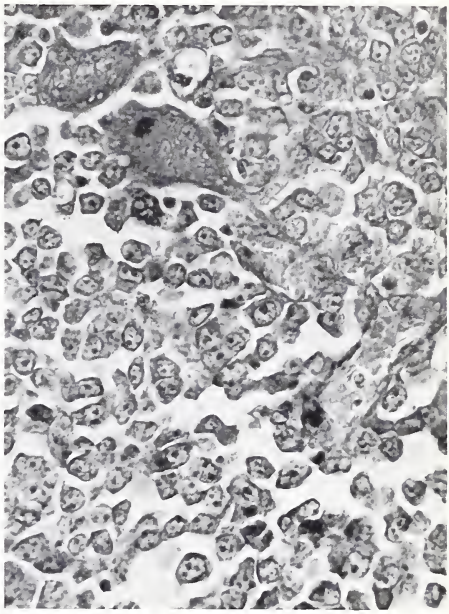

Fig. 226

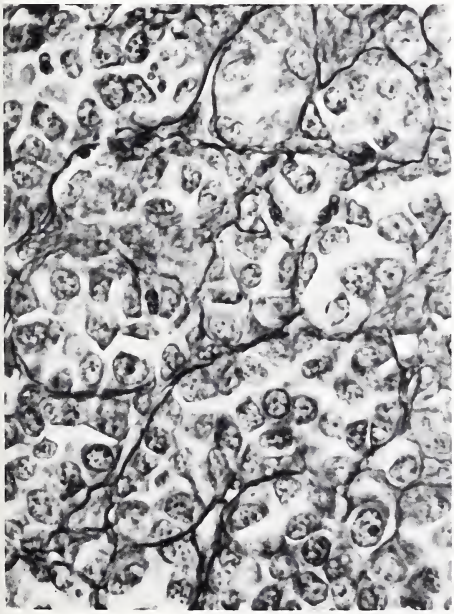

Fig. 227

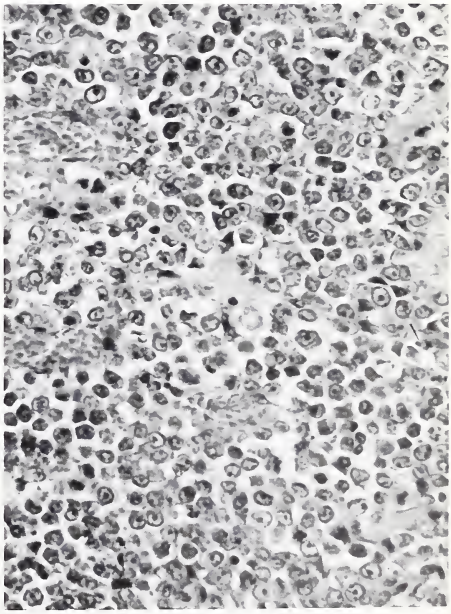

Fig. 228

CARCINOMA #1. DOG

Figure 229. Photomicrograph of 14th generation transplant tumor. This is a higher power view of figure 228 showing cellular detail. There are only a few collagenic fibers, and these are confined to the region of the blood vessels. Van Gieson stain. X 830. N. C. I. 9299; A. F. I. P. Acc. No. 219934–230.

Figure 230. Photomicrograph of 14th generation transplant tumor. Reticular fibers are most numerous in the region of the blood vessels, where they may surround individual cells or small groups of cells. Distant from the blood vessels, reticular fibers are few in number. Wilder's silver preparation. X 610. N. C. I. 9295; A. F. I. P. Acc. No. 219934–231.

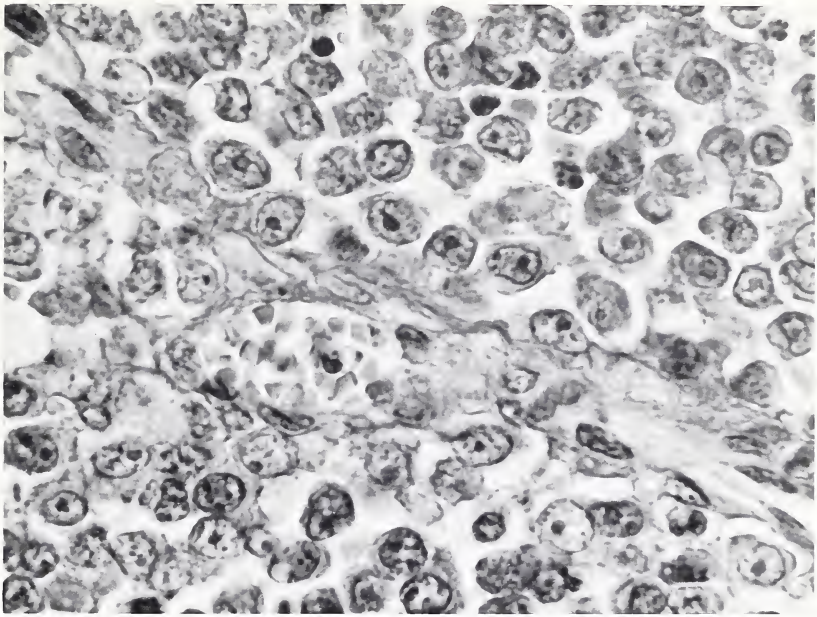

Fig. 229

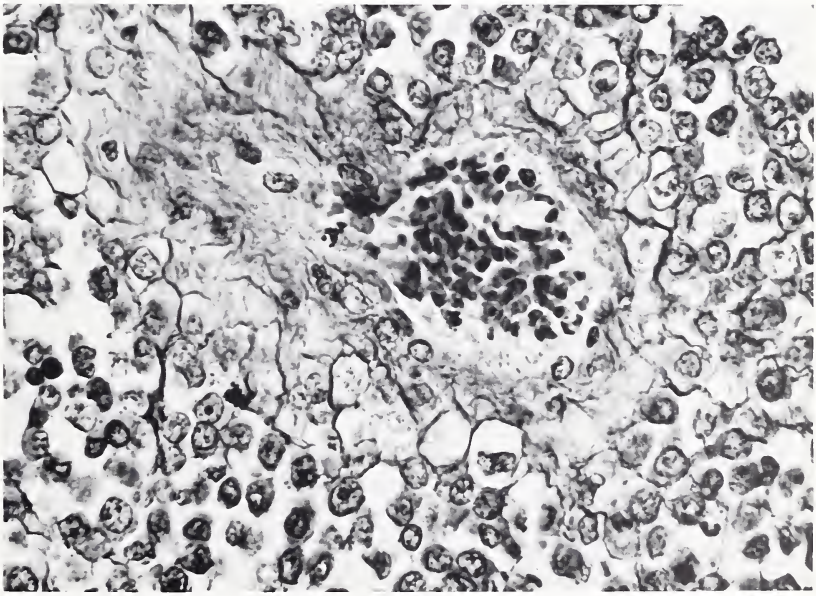

Fig. 230

228–230). However, the transplanted tumor is more vascular and contains no multinucleated giant cells. The cytoplasm of a few cells, some neoplastic and others phagocytic, contains clusters of periodic acid—Schiff-positive globular material which cannot be removed by diastase. There are no large areas of hemorrhage and necrosis. However, single degenerated and necrotic cells that are shrunken, stellate, and hyperchromatic may be found throughout the tumor.

References

Allam, M. W., Lombard, L. S., Stubbs, E. L., and Shirer, J. F. Transplantation of a thyroid carcinoma within the canine species. Cancer Research, 14:734–737, 1954.

———, Lombard, L. S., Stubbs, E. L., and Shirer, J. F. Transplantability of a canine thyroid carcinoma through thirty generations in mixed-breed puppies. J. Nat. Cancer Inst., 17:123–129, 1956.

TUMORS OF THE BLOOD VASCULAR SYSTEM

Hemangioendothelioma H6221. Mouse

DEFINITION. A spontaneous hemangioendothelioma of the epididymis of a BALB/c mouse.

HISTORY AND DESCRIPTION OF ORIGINAL TUMOR. Hemangioendothelioma H6221 was found at necropsy in the epididymis of an untreated adult male BALB/c mouse of unknown age. The necropsy was performed on January 9, 1951, in the laboratory of Katharine Hummel at the Roscoe B. Jackson Memorial Laboratory in Bar Harbor, Maine. The tumor was described as a soft dark red nodule 8.0 mm. in diameter that replaced the epididymis, surrounded the ductus deferens, and extended into the adjacent adipose tissue.

A histologic section of the primary tumor stained with hematoxylin and eosin was made available to us for the present study through the kindness of Elizabeth Fekete of Bar Harbor. A cross section of the vas deferens and two separate foci of epididymal tubules lie within the mass of the tumor. The tumor is nodular and partially encapsulated by connective tissue consisting chiefly of collagenous fibers (fig. 231). Extension fibers of the capsule partition the neoplasm into several coarse and many fine nodules. These fibers also form the supporting stroma for the neoplastic cells and blood vessels. The tumor is composed predominantly of blood vascular channels and sheets of neoplastic cells (figs. 232, 233). The blood vascular channels vary in shape and size, the largest measuring 0.5 mm. in greatest diameter, and the smallest approaching the size of capillaries. Although a few of these channels are empty, most of them contain erythrocytes, leukocytes, fibrin, precipitated blood protein, and occasionally desquamated neoplastic cells. Some are occluded by organizing thrombi. These vessels are lined by neoplastic cells one to several layers thick, which often form papillary processes extending into the lumen. Fibers of connective tissue support these processes and also form the wall of the blood channel (fig. 234). The tumor is generally well preserved, although a few areas of necrosis, hemorrhage, deposition of pigment, and inflammatory cell infiltration may be found.

The neoplastic cells are flat, round, polygonal, spindle shaped, or extremely irregular in form. They vary in size from that of a small lymphocyte to that of a megakaryocyte. Many of the tumor cells that line blood vessels resemble hyperplastic endothelial cells. The larger more atypical cells have a large amount of basophilic cytoplasm that is often granular or finely vacuolated. The nucleus also varies widely in size and shape. While most of the cells contain only one nucleus, some of these nuclei are multilobed. Other

tumor cells contain several nuclei. The hyperchromatic nucleus contains numerous fine evenly distributed chromatin granules and usually one basophilic nucleolus. One mitotic figure may be observed in three or four oil immersion fields. Some are abnormal in appearance.

TRANSPLANTATION STUDIES. Hemangioendothelioma H6221 was transplanted subcutaneously to weanling mice of the BALB/c strain, and it has subsequently grown successfully in 80 to 100 percent of BALB/c mice into which it has been inoculated. The tumor becomes palpable within 8 to 10 days following subcutaneous inoculation. It is transplanted at monthly intervals and kills the host within 4 to 6 weeks. In October 1954, the tumor was in its 66th transplant generation at the Jackson Memorial Laboratory. No metastases have ever been observed.

DESCRIPTION OF CURRENT TUMOR. A 1-month-old transplant tumor of the 61st generation of Hemangioendothelioma H6221 measures approximately 1.0 cm. in greatest diameter. It is partially encapsulated and composed of soft dark red tissue which, upon section, exudes dark blood. The necropsy was performed at the Jackson Memorial Laboratory and the paraffin block containing the tumor was sectioned and stained by a variety of methods at the National Cancer Institute. The histologic characteristics of the tumor of the 61st generation (figs. 235, 236) are similar to those of the primary tumor; therefore only additional features, particularly those revealed by special staining methods, are described.

One large vessel of the hemangioendothelioma is occluded by an organizing thrombus. Almost all of the tumor cells in the solid areas of the neoplasm are surrounded by or in contact with an argentophilic reticular network. This reticulum is black in Wilder's silver preparation and colored red by the periodic acid—Schiff reaction. It is colored deep blue with Mallory's aniline blue and dark brownish purple with phosphotungstic acid—hematoxylin. In the vascular areas of the tumor, the reticular fibers occupy a position with respect to the wall of the blood vessel similar to that of a basement membrane. The cytoplasm of the tumor cell as seen with the oil immersion lens is frequently granular and fibrillar. These cytoplasmic fibrils are colored blue with phosphotungstic acid—hematoxylin and are therefore considered to be fibroglia.*

*Note: One of the critics (P. E. S.) who reviewed this manuscript questioned our diagnosis of H6221 and wondered whether it might be an adenomatoid tumor of the type that occurs in the region of the generative organs. This critic stated that figures 231, 234, and 235 furthered his suspicion that this might indeed be an adenomatoid tumor. We have therefore reviewed H6221 in the light of this criticism, and although we appreciate its resemblance to an adenomatoid tumor as revealed in the photomicrographs, we are still of the opinion that this tumor is a hemangioendothelioma. Not only were the primary tumor and the transplants grossly red and did exude blood on section, but also this tumor is composed predominantly of vascular channels of varying size lined by neoplastic cells and containing erythrocytes, leukocytes, fibrin, precipitated blood protein, and thrombi. The adenomatoid tumors we have seen do not have a red color, do not exude large amounts of blood, and do not contain elements of the circulating blood or thrombi in the glandlike spaces that compose the tumor.

References

Andervont, H. B. Induction of hemangio-endotheliomas and sarcomas in mice with o-aminoazotoluene. J. Nat. Cancer Inst., 10:927–941, 1950.

_____, and Dunn, T. B. Transplantation of spontaneous and induced hepatomas in inbred mice. J. Nat. Cancer Inst., 13:455–503, 1952.

_____, Grady, H. G., and Edwards, J. E. Induction of hepatic lesions, hepatomas, pulmonary tumors, and hemangio-endotheliomas in mice with o-aminoazotoluene. J. Nat. Cancer Inst., 3: 131–153, 1942.

Edwards, J. E., Andervont, H. B., and Dalton, A. J. A transplantable malignant hemangioendothelioma of the liver in the mouse. J. Nat. Cancer Inst., 2:479–490, 1942.

Foulds, L. Angio-endothelioma in the mouse. Sc. Rep. Cancer Fund, London, 9:89–91, 1930.

Lorenz, E., and Stewart, H. L. Tumors of the alimentary tract induced in mice by feeding olive-oil emulsions containing carcinogenic hydrocarbons. J. Nat. Cancer Inst., 7:227–238, 1947.

Stewart, H. L. Tumors induced by subcutaneously injected carcinogens. Bull. Hosp. Joint Dis., 12: 131–147, 1951.

White, J., and Stewart, H. L. Intestinal adenocarcinoma and intra-abdominal hemangio-endothelioma in mice ingesting methylcholanthrene. J. Nat. Cancer Inst., 3:331–347, 1942.

HEMANGIOENDOTHELIOMA H6221. MOUSE

(Histologic section of original tumor and paraffin blocks containing 61st generation transplant tumor courtesy of Dr. Elizabeth Fekete, Roscoe B. Jackson Memorial Laboratory, Bar Harbor, Me.)

Figure 231. Photomicrograph of original tumor. The tumor is coarsely nodular and is composed of vascular spaces and sheets of neoplastic cells. A cross section of the ductus deferens (A) and two foci of epididymal tubules (B) are indicated by arrows. Note the extensive connective tissue which partially surrounds the tumor and contributes to its nodular character. Papillary processes extend into the large vascular space in the lower portion of the section below the ductus deferens. Hematoxylin and eosin stain. X 17. N. C. I. 9257; A. F. I. P. Acc. No. 219934–232.

Figure 232. Photomicrograph of original tumor. Note the anastomosing character of the vascular channels. Hematoxylin and eosin stain. X 235. N. C. I. 9246; A. F. I. P. Acc. No. 219934–233.

Figure 233. Photomicrograph of original tumor. In this area there are numerous vascular channels lined and separated from each other by neoplastic cells. The walls of some of these blood channels are composed of collagenous connective tissue. In some areas the tumor cells are arranged in sheets. Hematoxylin and eosin stain. X 80. N. C. I. 9251; A. F. I. P. Acc. No. 219934–234.

Fig. 231

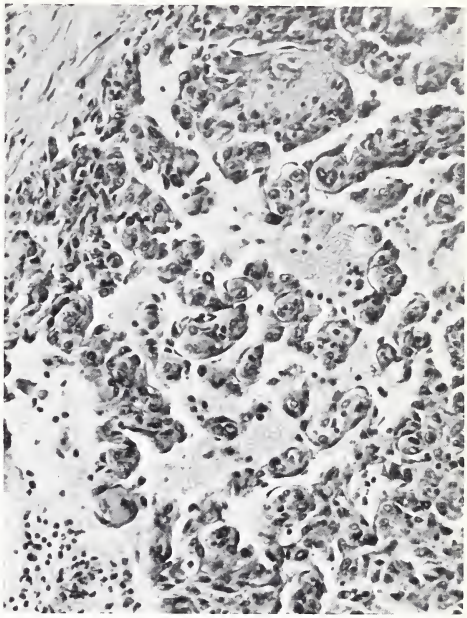

Fig. 232

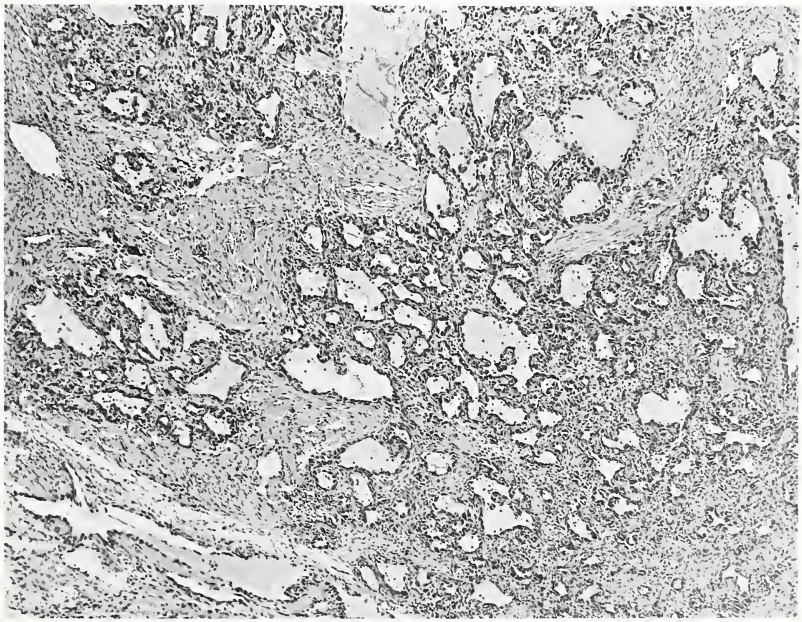

Fig. 233

HEMANGIOENDOTHELIOMA H6221. MOUSE

Figure 234. Photomicrograph of original tumor. Note the variation in size, shape, and appearance of the neoplastic cells and their relationship to the vascular channels. Hematoxylin and eosin stain. X 420. N. C. I. 9241; A. F. I. P. Acc. No. 219934–235.

Figure 235. Photomicrograph of 61st generation transplant tumor. Note blood vascular spaces lined by neoplastic cells which vary in size and shape. Hematoxylin and eosin stain. X 220. N. C. I. 9373; A. F. I. P. Acc. No. 219934–236.

Figure 236. Photomicrograph of 61st generation transplant tumor. Note the vascular character of the growth. There is a portion of a thrombosed blood vessel in the upper right corner of the illustration. Note the inflammatory reaction and thick bands of connective tissue. Hematoxylin and eosin stain. X 105. N. C. I. 9354; A. F. I. P. Acc. No. 219934–237.

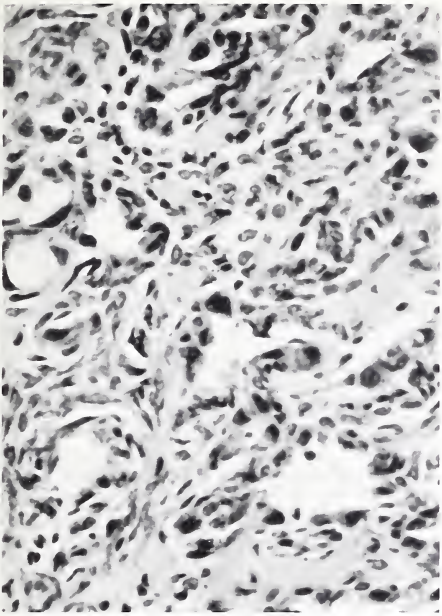

Fig. 234

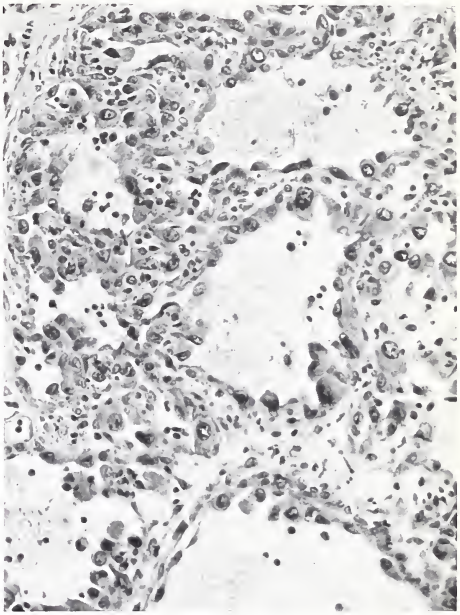

Fig. 235

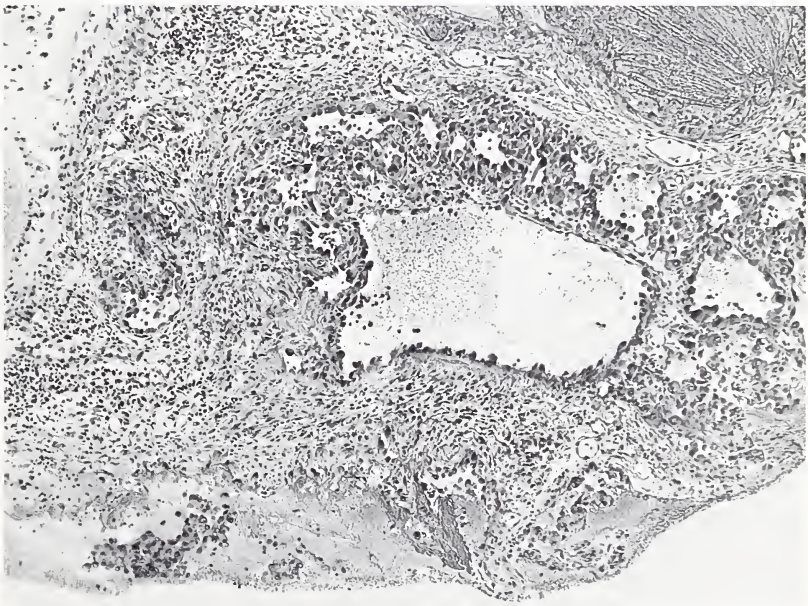

Fig. 236

TUMORS OF NEURAL TISSUE

TUMORS OF THE BRAIN

Astrocytoma C3H(18). Mouse

DEFINITION. An astrocytoma developed by selective transplantation of a glioma induced by methylcholanthrene in the brain of a C3H/St mouse.

HISTORY AND DESCRIPTION OF ORIGINAL TUMOR. A pellet of methylcholanthrene was inserted into the brain of a C3H/St mouse in midsummer 1947, in the laboratory of H. M. Zimmerman at Montefiore Hospital in New York City. The mouse suffered no immediate ill effects from this procedure and remained in apparent good health for almost nine months. Suddenly, on April 20, 1948, signs of an intracranial lesion developed. These consisted of enlargement of the head, convulsions, and paralysis. Eight days later the animal died.

At necropsy, a tumor was found in the subcortex of the right parietal lobe. It consisted of a small, infiltrating, gray, gelatinous growth with focal hemorrhage. On microscopic examination, the tumor was found to consist of a mixture of astrocytes, spongioblasts, ependymal cells, and other cells which were not identified. These different types of cell failed to form regular patterns but instead occurred in clusters among sparse fibrils of glial origin. The tumor possessed no connective tissue stroma and contained only a few blood vessels. Little or no necrosis was observed.

TRANSPLANTATION STUDIES. Selected tissue from this original mixed cell glioma was transplanted subcutaneously into host C3H/St strain mice. After continued selection and serial transplantation, a relatively pure astrocytoma emerged. This histologic pattern and behavior on transplantation became stabilized between the 8th and 14th generations. The characteristic cells were astrocytes, but spongioblasts were also frequently present. This astrocytoma was nearly always cystic, and the cysts contained clear fluid which coagulated upon standing. A variant of the tumor, an undifferentiated glioma, occasionally appeared in the course of serial transplantation.

The transplanted tumor grew successfully without regression in nearly 100 percent of animals inoculated with tissue fragments or with saline emulsions of the neoplasm. Transplantation was successful by subcutaneous, intraperitoneal, intrathoracic, intracerebral, and intraocular inoculation. The tumor was transplanted at 10 to 21 day intervals, and the host died about 14 days after inoculation. The growth invaded the adjacent tissues of the host but did not metastasize. (Data on the original tumor and its transplantation characteris-

tics were kindly contributed by Dr. H. M. Zimmerman of the Montefiore Hospital, New York, N. Y.)

DESCRIPTION OF CURRENT TUMOR. After more than 100 transplant generations, a 10-day-old subcutaneous transplant tumor measures about 1.2 cm. in diameter. It is gray, soft, and partially necrotic. Much of the growth is composed of a single cyst containing clear colorless or light amber fluid that clots upon standing.

Microscopically, Astrocytoma C3H(18) is surrounded by a capsule of edematous connective tissue containing a few blood vessels, inflammatory cells, and extravasated blood. The subcapsular portion of the tumor is viable, whereas much of the remaining tumor tissue is necrotic (fig. 237). Tumor cells survive longest around blood vessels. There are a few cystic areas containing granular or homogeneous acidophilic material. A feltwork of blue or brownish fibrils is revealed in viable portions of the tumor by the phosphotungstic acid—hematoxylin stain. In some instances, the fibrils appear to be continuous with the cytoplasmic processes of the tumor cell. The neoplastic cells show an extreme degree of variation in size, shape, amount of cytoplasm, and number of nuclei (figs. 238, 239). They may be round, oval, polygonal, or spindle shaped. They may be as small as small lymphocytes or even larger than megakaryocytes (fig. 240). The nuclei of some cells are surrounded only by thin, fibrillary, cytoplasmic processes, while other cells possess a large amount of acidophilic, often fibrillar cytoplasm. The appearance and distribution of the intranuclear chromatin are uniform, irrespective of the size or shape of the cell. The chromatin occurs as large, heavily stained granules, evenly distributed throughout the nucleus. Some nuclei possess from 1 to 6 acidophilic nucleoli, while others have none. One mitotic figure may be found in every other oil immersion field. These mitotic figures are generally very bizarre.

Blood vessels are of capillary type and are not numerous. They are supported by a small amount of connective tissue stroma that contains a few collagenic and reticular fibers. The periodic acid—Schiff reaction reveals purplish red fibrils around the vessels at the junction of, and occasionally within, areas of necrotic and viable tumor tissue. In addition, this reaction reveals a well defined purplish red network that is continuous with the cytoplasmic processes of the tumor cells. A few reticular fibers, demonstrated by Wilder's silver method, are present at the junction of necrotic and viable portions of the tumor but are not observed elsewhere. Zimmerman has classified this tumor as an astrocytoma.

References

Zimmerman, H. M. The nature of gliomas as revealed by animal experimentation. Am. J. Path., 31:1–29, 1955.

ASTROCYTOMA C3H (18). MOUSE

(Fixed tissue courtesy of Dr. H. M. Zimmerman, Montefiore Hospital, New York City)

Figure 237. Photomicrograph of transplant tumor. This area from the periphery of the tumor shows viable and necrotic tissue and a small cystic space. Hematoxylin and eosin stain. X 90. N. C. I. 8262; A. F. I. P. Acc. No. 219934-238.

Figure 238. Photomicrograph of transplant tumor. There is marked variation in size and shape of the tumor cells, although the intranuclear chromatin is fairly uniform in appearance and distribution. Hematoxylin and eosin stain. X 420. N. C. I. 8257; A. F. I. P. Acc. No. 219934-239.

Figure 239. Photomicrograph of transplant tumor showing an area composed chiefly of elongated cells. Hematoxylin and eosin stain. X 725. N. C. I. 8255; A. F. I. P. Acc. No. 219934-240.

Figure 240. Photomicrograph of transplant tumor showing an area in which the size of the cells varies from that of a small lymphocyte to that of a multinucleated giant cell larger than a megakaryocyte. Hematoxylin and eosin stain. X 880. N. C. I. 8256; A. F. I. P. Acc. No. 219934-241.

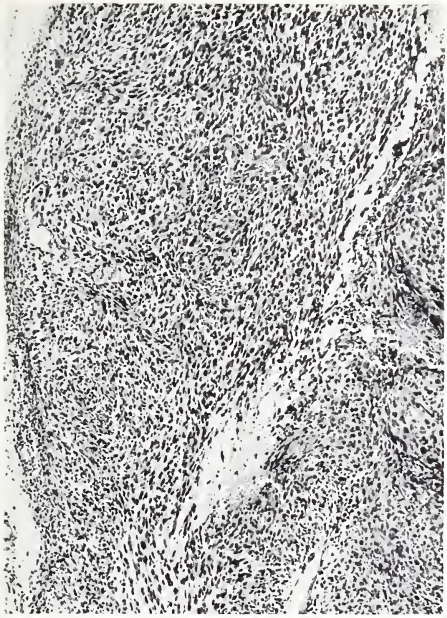

Fig. 237

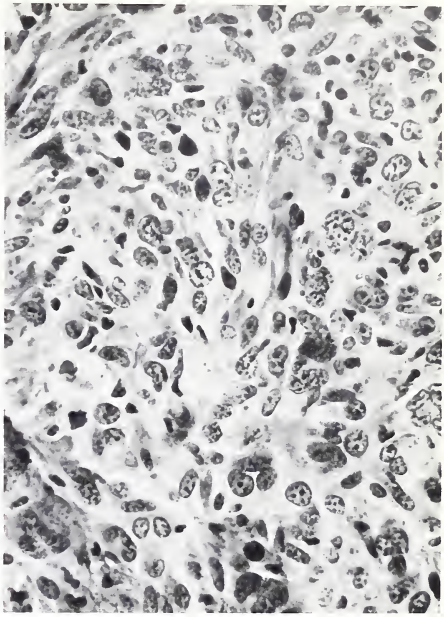

Fig. 238

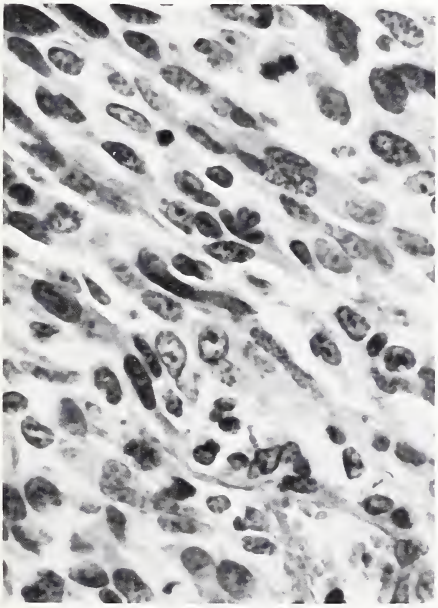

Fig. 239

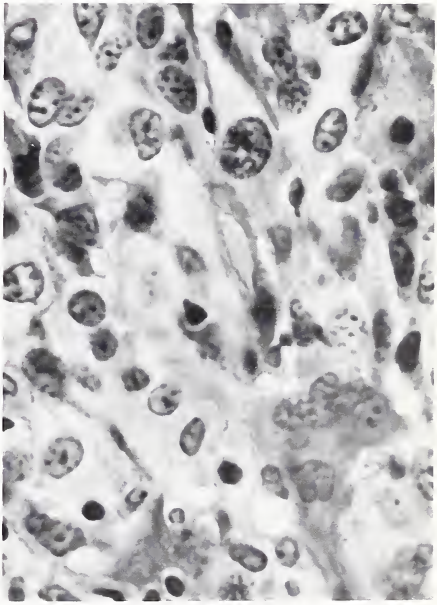

Fig. 240

———, (Moderator): Panel on tumors of the nervous system. In: Proceedings of the First National Cancer Conference, pp. 227–243. A publication of the American Cancer Society and the National Cancer Institute, 1949.

———, and Arnold, H. Experimental brain tumors. I. Tumors produced with methylcholanthrene. Cancer Research, 1:919–938, 1941.

———, and Maier, N. The transplantation of experimentally induced brain tumors. Am. J. Path., 25:801–802, 1949.

Ependymoma A(22). Mouse

DEFINITION. An ependymoma developed by selective transplantation of tissue from a glioma induced by 20-methylcholanthrene in the brain of an A/St mouse.

HISTORY AND DESCRIPTION OF ORIGINAL TUMOR. The original glioma was found on September 25, 1948, in an A/St strain mouse 354 days after H. M. Zimmerman, of the Montefiore Hospital in New York City, had implanted a pellet of 20-methylcholanthrene in the brain. The animal was in apparent good health until five days before its death. In the course of its five day illness, the mouse developed enlargement and distortion of the cranium and paralysis of certain muscles. At necropsy, a hemorrhagic tumor, 2 mm. in diameter, was found in the right cerebral subcortex at the site of implantation of the methylcholanthrene pellet. The neoplasm filled the right lateral and the third ventricles, replaced the ependyma of these cavities, and infiltrated the adjacent neural tissue. A portion of the tumor was necrotic and hemorrhagic. Most of the tumor cells were identified as being of ependymal origin, but there were also many astrocytes and spongioblasts. Occasionally, tumor cells were arranged in rosette formation. The stroma consisted of glial fibers.

TRANSPLANTATION STUDIES. Zimmerman transplanted the original glioma subcutaneously into mice of the A/St strain. Subsequent serial transplantation of selected pieces of tissue for 14 to 18 generations resulted in a biologically and histologically stabilized tumor having the characteristics of an ependymoma. This ependymoma could be transplanted by the subcutaneous, intramuscular, intraperitoneal, intrathoracic, intracerebral, or intraocular inoculation of a piece of the tumor or of an emulsion of tumor cells. The tumor was transplanted every 7 to 30 days, and most of the tumor-bearing hosts died 21 days after transplantation. The subcutaneous transplant tumor grew successfully in 100 percent of the host mice and did not regress. The ependymoma invaded adjacent host tissues but did not metastasize. (Data on the original tumor and its transplantation characteristics were kindly contributed by Dr. H. M. Zimmerman of the Montefiore Hospital, New York, N. Y.)

DESCRIPTION OF CURRENT TUMOR. A 21-day-old subcutaneous transplant tumor measures 15 mm. in diameter. It is soft, gray, and contains several foci of yellowish necrotic tissue.

On microscopic examination, the tumor is found to be sharply circumscribed and surrounded by a thin capsule of edematous connective tissue con-

taining a few inflammatory cells, blood vessels, and nerves. It is composed of closely packed cells that form characteristic perivascular pseudorosettes. The cells appear viable, except for occasional small focal areas of hemorrhage and necrosis. A few small calcareous deposits are scattered throughout the tumor. The tissue is moderately vascular, and most of the blood vessels are small. The vessels are surrounded by a small amount of connective tissue stroma containing collagenic and reticular fibrils and a few large cells with pale nuclei, not further identified. The tumor tissue between the blood vessels is virtually devoid of stroma.

There are three types of cell in the tumor: the polygonal cell, which is the most numerous; the cell composing the pseudorosettes; and the giant tumor cell (figs. 241, 242).

The polygonal-shaped cell measures 30 microns in average diameter and is faceted so that adjacent cells fit closely together. Many individual cells have 1 to 12 threadlike cytoplasmic processes which anastomose with those of adjacent cells, forming a glial meshwork (fig. 243). The basophilic cytoplasm sometimes contains granules which are particularly well brought out by Mallory's aniline blue stain. A cytoplasmic vacuole containing remnants of necrotic nuclear material is occasionally present, but blepharoplasts are not identified. The nucleus is usually found in the center of the cell and is deeply basophilic, because it is rich in fine chromatin granules. The nuclear membrane is thin. There are usually 1 or 2 large basophilic nucleoli. One mitotic figure is observed in every two or three oil immersion fields.

The cells of the pseudorosettes radiate from the walls of blood vessels that are the size of capillaries. These cells are often carrot shaped, and the nucleus occupies the bulbous end of the cell distal to the blood vessel (fig. 244). The tapered end of the cell loses itself in the perivascular connective tissue. Except for their characteristic shape and perivascular location, these cells that compose the pseudorosettes are in all other respects similar to the polygonal cells.

The giant tumor cells bear some resemblance to megakaryocytes, and they measure as much as 80 microns in diameter. These giant tumor cells are not numerous and are found most often in the region of blood vessels. No transitional forms between the giant tumor cell and the two previously described cells are observed. The giant tumor cell generally contains several nuclei, or it may contain only one lobated nucleus. Rarely it may be found to possess one round, lightly stained nucleus in the center of the cell. The nuclei of the multinucleated tumor cells are distributed peripherally, leaving the central part of the cell occupied by cytoplasm that may contain 1 or 2 basophilic granules. The cytoplasm of the giant tumor cells may form processes which anastomose with cytoplasmic processes of the polygonal cell. Both the cytoplasm and the nuclei of the giant tumor cell resemble in general the corresponding structures of the other two types of tumor cells. Zimmerman classified this tumor as an ependymoma.

EPENDYMOMA A(22). MOUSE

(Fixed tissue courtesy of Dr. H. M. Zimmerman, Montefiore Hospital, New York City)

Figure 241. Photomicrograph of transplant tumor. The tumor is composed of three types of cell: the polygonal cell, which is the most numerous; a carrot-shaped cell, which forms perivascular pseudorosettes; and a giant tumor cell. Hematoxylin and eosin stain. X 420. N. C. I. 8573; A. F. I. P. Acc. No. 219934–242.

Figure 242. Photomicrograph of transplant tumor. Only a few reticular fibers are present, and these are confined to the region of the blood vessels. Wilder's silver preparation. X 485. N. C. I. 8575; A. F. I. P. Acc. No. 219934–243.

Figure 243. Photomicrograph of transplant tumor. Many individual cells have threadlike cytoplasmic processes that anastomose with those of adjacent cells forming a glial meshwork. Phosphotungstic acid—hematoxylin stain. X 880. N. C. I. 8568; A. F. I. P. Acc. No. 219934–244.

Figure 244. Photomicrograph of transplant tumor. Another high power view to show the details of the polygonal cells and of the cells that form the pseudorosettes. Phosphotungstic acid—hematoxylin stain. X 800. N. C. I. 8572; A. F. I. P. Acc. No. 219934–245.

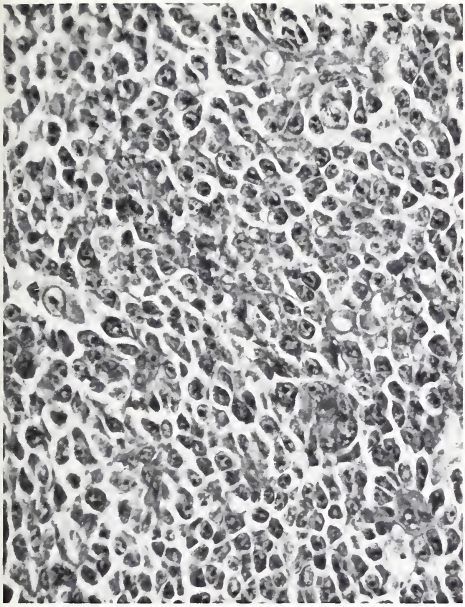

Fig. 241

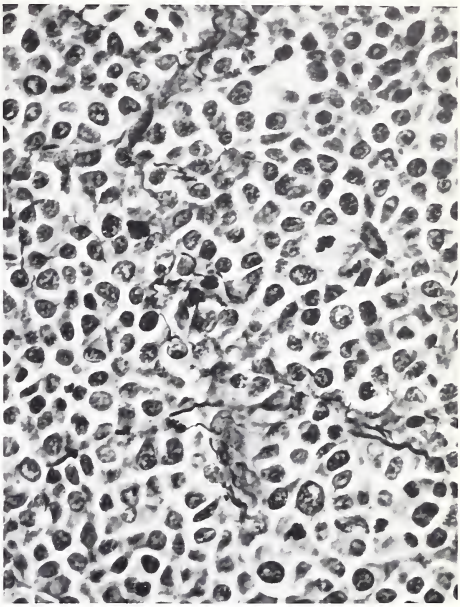

Fig. 242

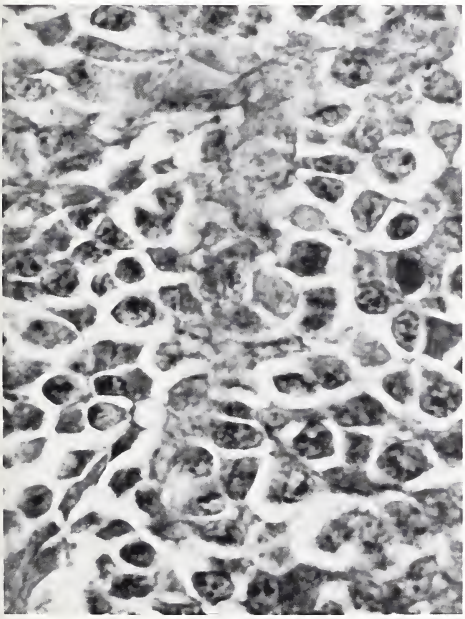

Fig. 243

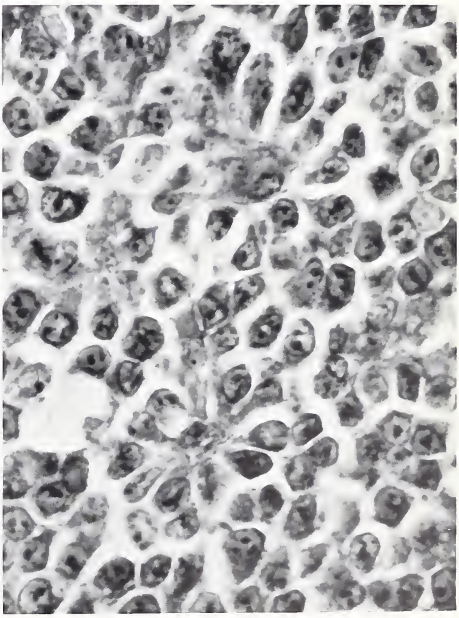

Fig. 244

References

Zimmerman, H. M. (Moderator): Panel on tumors of the nervous system. In: Proceedings of the First National Cancer Conference, pp. 227–243. A publication of the American Cancer Society and the National Cancer Institute, 1949.

_____. The nature of gliomas as revealed by animal experimentation. Am. J. Path., 31:1–29, 1955.

_____, and Arnold, H. Experimental brain tumors. I. Tumors produced with methylcholanthrene. Cancer Research, 1:919–938, 1941.

_____, and Maier, N. The transplantation of experimentally induced brain tumors. Am. J. Path., 25:801–802, 1949.

TUMORS OF UNDETERMINED SITE OF ORIGIN AND UNDIFFERENTIATED HISTOLOGIC PATTERN

Ehrlich Tumor (Solid and Ascites Forms). Mouse

DEFINITION. An undifferentiated tumor that originated spontaneously as a carcinoma of the mammary gland of a stock mouse.

HISTORY, DESCRIPTION OF ORIGINAL TUMOR, AND TRANSPLANTATION STUDIES. The present transplantable Ehrlich Tumor cannot be traced to a single primary neoplasm as its source. Although most of the tumors of the group from which the Ehrlich could have been derived probably arose in the mammary gland, some may have been primary in other sites. A number of references have been consulted, and these, together with a personal communication from T. S. Hauschka of the Roswell Park Memorial Institute, Buffalo, New York, form the basis for the historical account of the Ehrlich Tumor. Hauschka states: *

"As long ago as 1907, Paul Ehrlich in Frankfurt reported on his various strains of transplantable tumors of the mouse, of which he possessed nine at the time of his publication. Several of these tumors were adenocarcinomas, and at least two were pure sarcomas that derived from the carcinomatous tumors during serial transfer. Another one of them was an experimental mixture of carcinoma and sarcoma designated as 'mischka,' but the 'mischka' reverted to sarcoma upon subsequent transplantation. Another of these tumors was a chondroma.

"The various Ehrlich tumors being carried in transplantation at the present time as the Ehrlich ascites tumors were derived undoubtedly from one or another of the original lines of Ehrlich's carcinomata. The 'Frankfurt' tumor of the Ehrlich series, referred to by K. Freytag of Düsseldorf, Germany, was the most virulent of them all. Freytag had received the 'Frankfurt' tumor from Ehrlich after it had been carried through many serial transfer generations that grew successfully in 80 to 100 percent of the host mice. This line of the Ehrlich tumor was considered to be extraordinarily virulent both in Frankfurt and in Düsseldorf. In fact, it was Ehrlich's aim to enhance the virulence of all of his various transplantable lines of tumors by successively selecting only the most rapidly growing transplants that were palpable earliest. Hence, the highly virulent 'Frankfurt' tumor was in great demand in the German and other European laboratories. It is very possible that the ascites carcinoma was derived from the 'Frankfurt' line of Ehrlich's tumor in 1932 (Loewenthal and Jahn).

---

*Hauschka, T. S. Personal communication.

"The authentic Ehrlich ascites tumors differ considerably. Klein's Ehrlich ascites cannot be traced to the tumor of Loewenthal and Jahn, but was started anew from a solid Ehrlich carcinoma obtained from one of A. Fischer's tissue cultures in Copenhagen in 1948. Dr. Klein's Ehrlich ascites tumor at Stockholm has a modal chromosome number of 80. Our branch of this tumor which we have carried in Philadelphia and Buffalo has drifted to a hypotetraploid major mode of 75. A hyperdiploid line of Ehrlich ascites carcinoma has been used in Lettré's laboratory in Heidelberg for the past twelve years. This line of the tumor has a chromosome number mode at 45 and 46, first described by Bayreuther in 1952. In recent descriptions of the same tumor, which we also carry at our Buffalo laboratory, Kaziwara has emphasized one advantageous feature of Lettré's Heidelberg Ehrlich ascites: it is regularly free of blood, whereas Klein's tetraploid Stockholm line of the Ehrlich tumor always contains blood. We have designated the hyperdiploid Lettré line of the Ehrlich ascites tumor as 'EL,' and a hypertetraploid subline of EL as 'EL88.'

"From my own experience with variations within tumor cell populations regarding both cytologic and immunogenic criteria, I would gather that it makes very little difference in 1955 from which one of Ehrlich's strains the present-day sublines are derived; for even one and the same subline may be experimentally subdivided into clonal components which differ from one another in chromosome number, chromosome morphology, and in physiological properties. In December 1950, at which time I obtained the Ehrlich ascites from Dr. Klein, the tumor had passed over 150 transplant generations in the ascites form and has been carried by us through 208 weekly transfers (about 2,500 cell-generations) since then. Genetic drift in a malignant cell population propagated for so long a period is probably considerable; the direction of this drift is unpredictable, so that Ehrlich ascites material available in various laboratories may still be similar, but far from identical."

Santesson, writing from his experience with the solid form of the Ehrlich Tumor, stated that he considered it to be a carcinoma and further classified it as an adenocarcinoma. He noted, however, that the cells were irregular and were usually arranged in no definite histologic pattern. Only rarely was there an indication of the formation of acini. To judge from its behavior on transplantation (e. g., high percentage of takes, and rapid and infiltrative mode of growth), the tumor was highly malignant. When of any considerable size, it consisted of a mass of necrotic tissue with a thin peripheral margin of viable neoplastic cells. The transplant tumors propagated at Radiumhemmet, where Santesson carried out his studies, grew successfully in 75 percent of hosts (216 transplants). These tumors grew rapidly and killed the animals within about 45 days. Santesson never observed regression of the tumor in his laboratory.

The ascites variant of the Ehrlich Tumor was developed by Loewenthal and Jahn in 1932 by selective serial transplantation of ascitic fluids of mice

inoculated intraperitoneally with suspensions of Ehrlich tumor cells. The technic of transplantation and the behavior of the ascites form of the Ehrlich Tumor have been described by various other investigators. According to Klein and associates (1950), when 0.2 cc. of freshly drawn ascitic fluid containing about 20 million tumor cells was inoculated intraperitoneally into mice, the animals developed ascites within 4 to 6 days and all were dead within 10 days. By varying the technics of intraperitoneal inoculation, intermediate forms between a relatively pure ascites tumor and solid intraperitoneal growth, with few or no free tumor cells in the peritoneal effusion, were produced. The influence of cell dosage on the development of solid intraperitoneal growth was observed only during the early passages of the Ehrlich Ascites Tumor. Since then, Hauschka has obtained pure ascites tumors after transfer of a single cell into newborn as well as into adult mice. Successful transfer in the former was as high as 30 percent; in the latter, only 2 percent. All successful transfers were manifested as pure ascites tumors. This finding has since been confirmed by Klein and is considered an expression of continuous selection of cells optimally adapted to free growth and suspension.

DESCRIPTION OF THE SOLID FORM OF THE CURRENT EHRLICH TUMOR. For the present study, a BALB/c mouse is killed six days after receiving a subcutaneous inoculation of ascitic fluid containing Ehrlich tumor cells. A well circumscribed pink to gray tumor, 1 cm. in diameter, is present at the site of inoculation. Approximately one third of the tumor is necrotic. There are no metastases.

This solid Ehrlich Tumor consists of sheets of cells supported by a small amount of connective tissue stroma (fig. 245). The tumor cell is spheroid or polygonal and has a diameter ranging from 20 to 30 microns. The cell membrane is poorly defined, and the cytoplasm is homogeneous and slightly basophilic. The nucleus is large and lobated. Clumps of intranuclear chromatin are associated with linin threads and are most numerous near the well defined nuclear membrane. One to four nucleoli, usually acidophilic, are generally present. An average of three mitotic figures may be found in every oil immersion field, and these are sometimes abnormal in appearance. A few areas of the tumor are free of argentophilic reticulum although as a general rule, a fine to moderately heavy reticular network surrounds individual cells and small groups of cells (figs. 246, 247). Very few collagenic fibers are present. Blood vessels are not numerous and they resemble capillaries. The tumor infiltrates the adjacent tissues of the host; and nerves, envelopes of fat cells, muscle fibers, and mammary ducts are recognized deep within the tumor. The cells of the Ehrlich Tumor are primitive in appearance, and the histologic pattern is not diagnostic of carcinoma or sarcoma; hence the growth is classified as an undifferentiated neoplasm.

DESCRIPTION OF THE ASCITES FORM OF THE CURRENT EHRLICH TUMOR. A BALB/c mouse inoculated intraperitoneally with ascitic fluid con-

taining Ehrlich tumor cells is killed seven days later. At necropsy, the abdomen is distended with 5 cc. of cloudy red fluid containing flakes of gray material. The visceral and parietal layers of the peritoneum are dull and granular. No large solid areas of tumor are observed.

Smear preparations from the ascitic fluid are fixed and stained. Histologic sections of the various tissues and organs are also prepared. The tumor cells in smears of the ascitic fluid appear slightly larger, but in other respects they appear similar to those of the solid neoplasm previously described. The cells in the ascitic fluid are round, possess a distinct cell membrane, and measure from 30 to 40 microns in diameter (fig. 248). The cytoplasm is granular and vacuolated, and the peripheral cytoplasm is more deeply basophilic than the perinuclear cytoplasm. The hyperchromatic nuclei are round, oval, or lobate and vary somewhat in size. Mitotic figures are numerous.

The omentum, mesentery, genital omentum, parietal peritoneum, and the serous membranes of the liver, spleen, epididymis, spermatic cords and testes are covered with a sheet of neoplastic tissue with which is intermingled an inflammatory exudate. At several points, the tissues are invaded by neoplastic cells. A few discrete tumor nodules, 1 to 2 mm. in diameter, are present in the mesentery, omentum, and perirenal and periureteral fat. The pancreas is extensively infiltrated by neoplastic tissue, and many acini are degenerated. The evidence is not sufficient to rule out the possibility that some of the neoplastic cells are occupying blood vessels or lymphatic vessels. A mesenteric lymph node shows no evidence of neoplasm. There are a few small foci of necrosis in the liver. The spleen shows pronounced erythromyelopoiesis.

On the serosal surface of the heart and lungs there are patchy foci of inflammation containing a few neoplastic cells. Many such focalized areas are observed around nerves in the mediastinum. A red thrombus containing neoplastic cells is found between the musculi pectinati of the left cardiac atrium.

THE ASCITES TUMOR AS AN EXPERIMENTAL TOOL. In clinical medicine, the phenomenon of exfoliation of tumor cells into a body cavity and the presence of free tumor cells in transudates has long been recognized. As a direct outgrowth of such observations in patients, Hesse and also Koch in 1927 conceived the idea of duplicating this process experimentally and developed the technic for producing the so-called "experimental ascites tumor." The introduction of cells of the Flexner-Jobling Carcinosarcoma into the peritoneal cavity of rats was followed by the development of ascites. Large numbers of tumor cells were present in the ascitic fluid. Hesse and Koch both found that transplantation of the Flexner-Jobling Tumor was more successful by the intraperitoneal than by the subcutaneous route.

In recent years, Yoshida, Goldie and Felix, Klein, Hauschka, and others have made important contributions to the study of ascites tumors. At the present time, the ascites variant of many tumors of the mouse, rat, and chicken

are in existence. The term ascites tumor has come to denote a process in which, following inoculation of tumor cells into a body cavity, the tumor cells multiply, and there is effusion of fluid containing a suspension of neoplastic cells. Since results are essentially the same whether the inoculation is made into the peritoneal or other serous lined cavities, it has been suggested that the term "effusion tumor" or "free cell tumor" be substituted for ascites tumor. These suggestions have not been generally accepted. The ascites tumor technic has become a useful experimental tool for many reasons: known numbers of tumor cells can be inoculated, the growth and regression of tumor can be quantitated, and the neoplastic cells can be studied by methods developed for the examination of the leukocytes of the circulating blood. The ascites tumor is used extensively as an experimental tool in the present expanded research program on the chemotherapy of cancer.

References

Baillif, R. N. The solid phase of the Ehrlich ascites tumor in mice. Cancer Research, 14:554–558, 1954.

Bather, R. Growth characteristics of the Rous No. 1 sarcoma grown in the peritoneal cavity of chickens. Brit. J. Cancer, 8:535–544, 1954.

Bayreuther, K. Der Chromosomenbestand des Ehrlich-Ascites-Tumors der Maus. Ztschr. Naturforsch., 7:554–557, 1952.

Ehrlich, P., and Apolant, H. Beobachtungen über maligne Mäusetumoren. Berl. klin. Wchnschr., 42:871–874, 1905.

Freytag, K. Ueber das Mäusecarcinom. Ztschr. f. Krebsforsch., 10:155–167, 1911.

Goldie, H., and Felix, M. Growth characteristics of free tumor cells transferred serially in the peritoneal fluid of the mouse. Cancer Research, 11:73–80, 1951.

Hauschka, T. S. Methods of conditioning the graft in tumor transplantation. J. Nat. Cancer Inst., 14:723–739, 1953.

Hesse, F. Uber experimentellen Bauchfellkrebs bei Ratten. Mit Angabe eines einfachen und bequmen Weges der Krebsübertragung. Nach Versuchen mit dem Flexner-Jobling-Tumor. Centralbl. f. Bakt., 1. Abt., 102:367–374, 1927.

Kaziwara, K. Derivation of stable polypoid sublines from a hyperdiploid Ehrlich ascites carcinoma. Cancer Research, 14:795–801, 1954.

Klein, G. Comparative studies of mouse tumors with respect to their capacity for growth as "ascites tumors" and their average nucleic acid content per cell. Exper. Cell Research, 2:518–573, 1951.

———, and Klein; E. Conversion of solid neoplasms into ascites tumors. In: Ascites Tumors as Tools in Quantitative Oncology. Ann. New York Acad. Sc., 63 (art. 5): 640–661, 1956.

Klein, E., Kunrick, N. B., and Klein, G. The effect of storage on the nucleic acid content and virulence of mouse ascites tumor. Exper. Cell Research, 1:127–134, 1950.

Koch, J. Welche Tatsachen und Schlussfolgerungen ergeben sich aus der Infektiosität des Aszites beim Bauchfellkrebs der Ratte? Centralbl. f. Bakt., 1. Abt., 107:332–357, 1928.

Koprowski, H. Ascites tumors as culture media in quantitative growth studies of viral agents. In: Ascites Tumors as Tools in Quantitative Oncology. Ann. New York Acad. Sc., 63 (art. 5): 895–914, 1956.

Levan, A., and Hauschka, T. S. Chromosome numbers of three mouse ascites tumours. Hereditas, 38:251–255, 1952.

EHRLICH TUMOR (Ascites and Solid Forms). MOUSE

(Tumor-bearing animal courtesy of Dr. A. L. Schade, National Institute of Allergy and Infectious Diseases, Bethesda, Md.)

Figure 245. Photomicrograph of solid form of transplant tumor. Note the arrangement and appearance of the cells and numerous mitotic figures. Hematoxylin and eosin stain. X 360. N. C. I. 7880; A. F. I. P. Acc. No. 219934–246.

Figure 246. Photomicrograph of solid form of transplant tumor. In this area there are very few reticular fibers. Note numerous mitotic figures in this field. Wilder's silver preparation. X 420. N. C. I. 8945; A. F. I. P. Acc. No. 219934–247.

Figure 247. Photomicrograph of solid form of transplant tumor showing a field in which many individual cells are surrounded by reticular fibers. Only a few mitotic figures are present. A few envelopes of fat cells lie deep within the tumor tissue. Wilder's silver preparation. X 460. N. C. I. 8946; A. F. I. P. Acc. No. 219934–248.

Figure 248. Photomicrograph of a stained smear of the peritoneal fluid of a mouse bearing a transplant of ascites tumor. Viable and degenerating cells and several mitotic figures are seen. Giemsa stain. X 920. N. C. I. 7889; A. F. I. P. Acc. No. 219934–249.

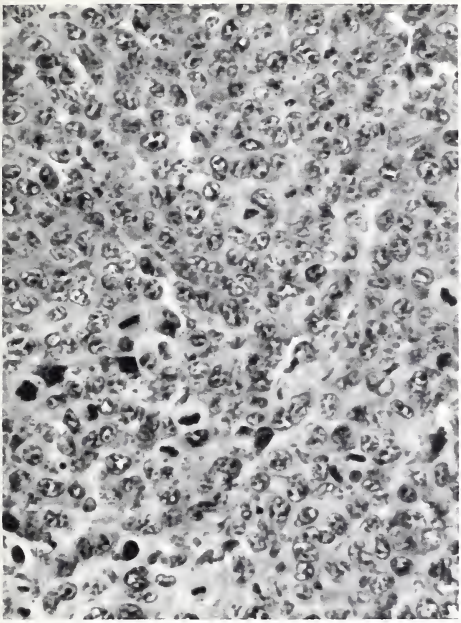

Fig. 245

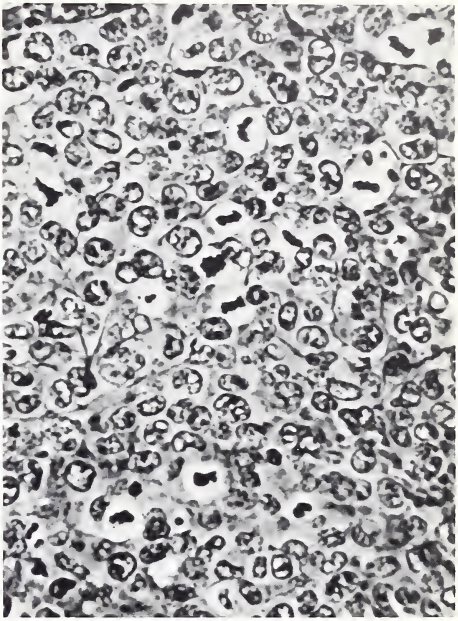

Fig. 246

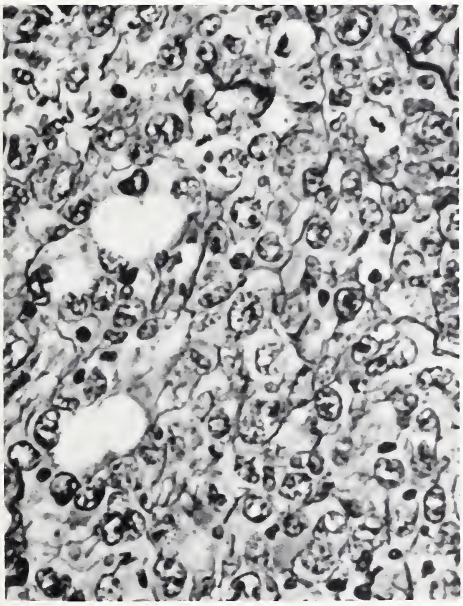

Fig. 247

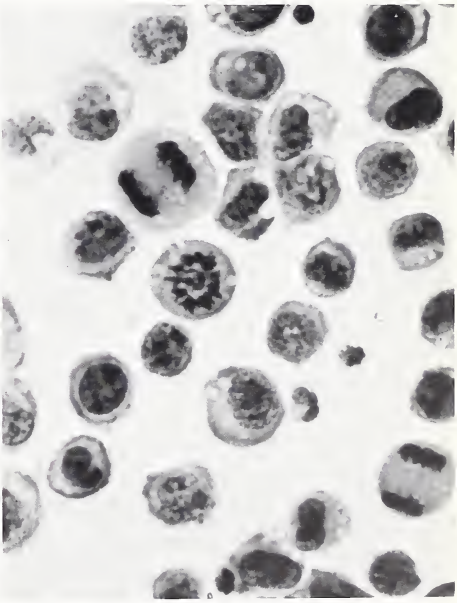

Fig. 248

Loewenthal, H., and Jahn, G. Übertragungsversuche mit carcinomatöser Mäuse-Ascitesflüssigkeit und ihr Verhalten gegen physikalische und chemische Einwirkungen. Ztschr. f. Krebsforsch., 37:439–447, 1932.

Love, R., Orsi, E. V., and Koprowski, H. Cytological and cytochemical properties of ten ascites tumors. J. Biophys. Cytol., 2:1–14, 1956.

Santesson, L. Characteristics of epithelial mouse tumour cells in vitro and tumour structures in vivo; a comparative study. Acta path. et microbiol. Scandinav., Supplement 24:1–237, 1935.

Seeger, P. G. Die Unterschiede zwischen normalen Exsudatzellen und Tumoraszitezellen der Maus hinsichtlich ihresvitalfärberischen und mikrochemischen Verhaltens. Arch. f. Zellforsch., 22: 356–366, 1939.

Sugiura, K., and Creech, H. J. Merits of ascites tumors for chemotherapeutic screening. In: Ascites Tumors as Tools in Quantitative Oncology. Ann. New York Acad. Sc., 63 (art. 5):962–976 1956.

Yoshida, T. Studies on an ascites (reticuloendothelial cell?) sarcoma of the rat. J. Nat. Cancer Inst., 12:947–969, 1952.

Crocker Tumor 180. Mouse

SYNONYMS: Mouse Sarcoma 180; Crocker Sarcoma 180; Sarcoma 180.

DEFINITION. An undifferentiated tumor that arose spontaneously as a carcinoma in the axilla of a white male mouse.

HISTORY OF ORIGINAL TUMOR. The primary tumor was found in the right axillary region of a white male mouse necropsied on October 26, 1914, in the laboratory of the late W. H. Woglom of the Crocker Laboratory in New York City. The tumor was diagnosed as a carcinoma, but the tissue of origin was not stated. Following serial subcutaneous transplantation, the histologic pattern of this carcinomatous tumor was altered so as to resemble that of a sarcoma. This transformation occurred at some time before 1919. Since that time, Crocker Tumor 180 has been continuously grown by transplantation in mice of various strains at the Memorial Hospital in New York City, without further change in histologic appearance.

Several years ago, the Crocker Laboratory, now the Cancer Institute of Columbia University, was moved from 116th Street to the College of Physicians and Surgeons at 168th Street in New York. At that time, the slides and records of Sarcoma 180 were left behind, and the staff has not been able to find them for restudy. It is therefore not possible to confirm the original impression that the primary tumor was a carcinoma.

TRANSPLANTATION STUDIES. Crocker Tumor 180 is not strain specific. It grows rapidly in 90 to 100 percent of the host animals into which it is inoculated, but it regresses in about 8 to 10 percent of them. The tumor-bearing host dies within 18 to 28 days after inoculation. The tumor can be transplanted by subcutaneous, intramuscular, or intraperitoneal inoculation. The transplant tumor tissue commonly invades the surrounding tissues of the host. Metastatic growths in the lungs have been observed by some investigators. Patti and

Moore found that Crocker Tumor 180 could be transplanted successfully by inoculation into the peritoneum of a newborn rat, an entirely different murine species. In adult rats, however, the tumor failed to grow. Furthermore, it failed to grow by subcutaneous inoculation into newborn rats. The newborn rats inoculated intraperitoneally with the tumor usually died within a week, often with widespread metastases.

DESCRIPTION OF CURRENT TUMOR. A 7-day-old subcutaneous transplant of Crocker Tumor 180 in an albino stock mouse consists of a round, firm, grayish tan tumor, 1 cm. in diameter. A large portion of the central area of the tumor is hemorrhagic and necrotic.

The tumor has an alveolar pattern. Relatively large sheets of tumor cells are partially surrounded by thin strands of connective tissue stroma containing blood vessels. The central two thirds of the tumor is necrotic and hemorrhagic, and this area is demarcated from the surrounding viable tumor by dilated vessels (fig. 249). The tumor cells, nearly all of the same size, vary somewhat in shape. They may be round, polygonal, or sometimes elongated at one or both poles (fig. 250). The cell possesses a large amount of basophilic cytoplasm which often contains fine vacuoles. The nuclei are deeply hyperchromatic and fairly uniform in size, but they vary in shape. A heavily stained nuclear membrane encloses fine dustlike particles of chromatin and usually three large basophilic nucleoli. Two mitotic figures may be found in each high power field, and they are usually normal in form. Fine argentophilic reticular fibers may surround a group of 3 to 10 cells, or occasionally only one cell may be enmeshed in such a reticulum (figs. 251, 252). There are not many collagenic fibers, and these are largely confined to the stroma which divides the tumor into coarse alveoli. The blood vessels are thin walled and dilated. The tumor does not have a definite capsule. It invades skeletal muscle, adipose tissue, nerve trunks, and blood vessels, degenerated remnants of which may be found within the tumor.

The undeveloped appearance of the cells and lack of any specific histologic pattern seem to us to place this neoplasm in the category of an undifferentiated tumor not definitely classifiable as either sarcoma or carcinoma. The original tumor was said to be a carcinoma, but the exact site of origin, whether from skin or breast or other structure, was never made clear.

References

Patti, J., and Moore, A. E. Heterologous growth of Sarcoma 180 with progression to death of hosts. Cancer Research, 10:674–678, 1950.

Sugiura, K., and Stock, C. C. Studies in a tumor spectrum. I. Comparison of the action of methylbis (2-chloroethyl)amine and 3-bis(2-chloroethyl)aminomethyl-4-methoxymethyl-5-hydroxy-6-methylpyridine on the growth of a variety of mouse and rat tumors. Cancer, 5:382–402, 1952.

CROCKER TUMOR 180. MOUSE

(Tumor-bearing animal courtesy of Dr. Kanematsu Sugiura, Sloan-Kettering Institute for Cancer Research, New York City)

Figure 249. Photomicrograph of transplant tumor. This portion of the growth shows the border between viable and necrotic tissue. Remnants of invaded skeletal muscle fibers are present within the tumor. Hematoxylin and eosin stain. X 100. N. C. I. 8263; A. F. I. P. Acc. No. 219934–250.

Figure 250. Photomicrograph of transplant tumor showing the cytological characteristics. Note several mitotic figures. Remnants of skeletal muscle fibers of the host are present in the lower right corner. Hematoxylin and eosin stain. X 490. N. C. I. 8245; A. F. I. P. Acc. No. 219934–251.

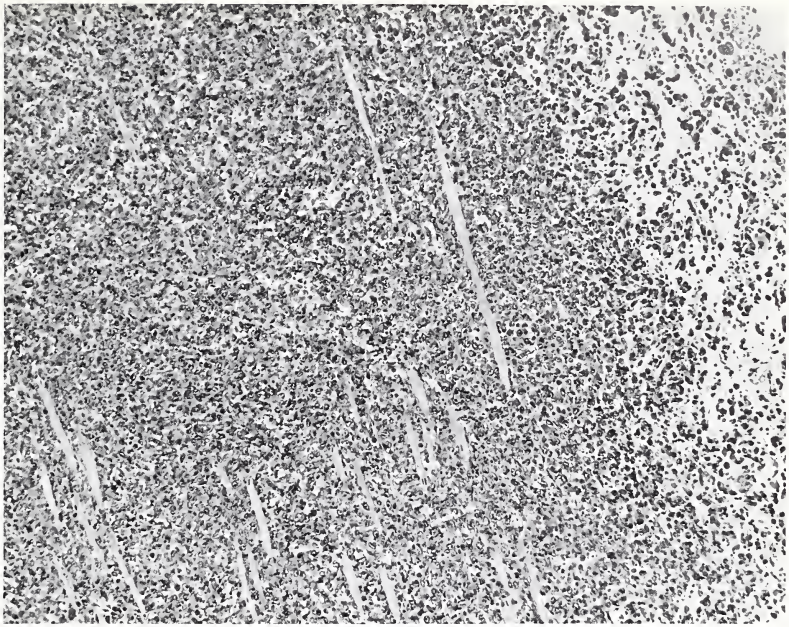

Fig. 249

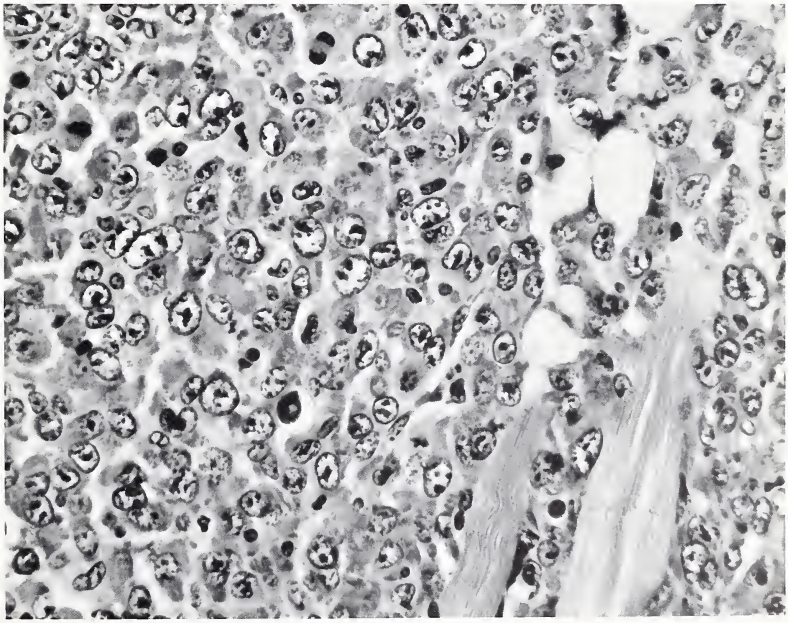

Fig. 250

CROCKER TUMOR 180. MOUSE

Figure 251. Photomicrograph of transplant tumor. Almost every cell in this field is surrounded by reticular fibrils. The pattern of this portion of the tumor is that of a sarcoma. Wilder's silver preparation. X 725. N. C. I. 8253; A. F. I. P. Acc. No. 219934–252.

Figure 252. Photomicrograph of transplant tumor. The distribution of the reticular fibrils in this field is compatible with the pattern of a carcinoma. Wilder's silver preparation. X 725. N. C. I. 8254; A. F. I. P. Acc. No. 219934–253.

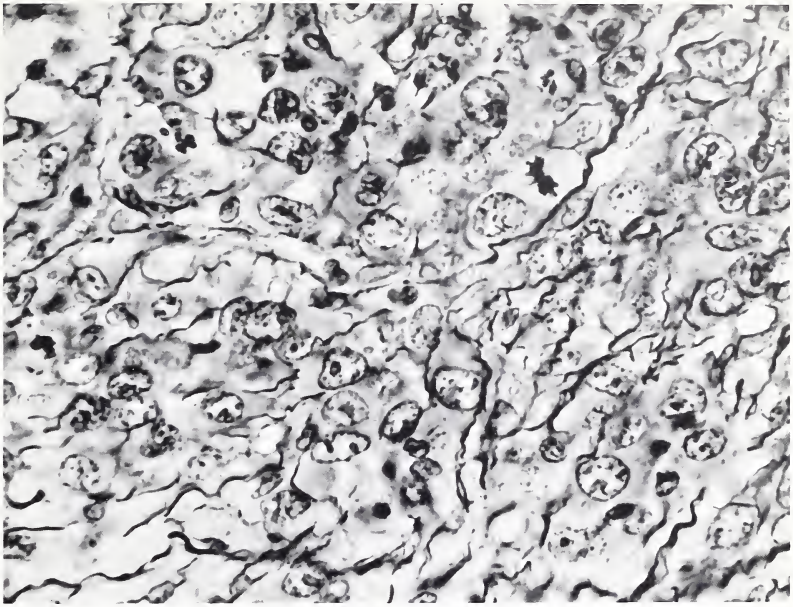

Fig. 251

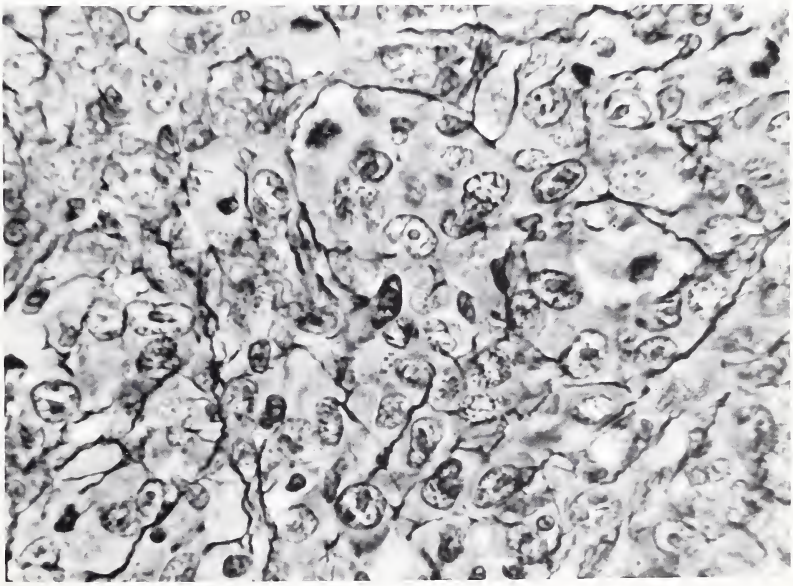

Fig. 252

Krebs 2 Tumor (Solid and Ascites Forms). Mouse

SYNONYMS: Carcinoma, Krebs 2; Krebs 2 Carcinoma.

DEFINITION. A rapidly growing undifferentiated neoplasm that originated spontaneously as a carcinoma, probably of mammary gland origin, in a stock mouse.

HISTORY AND DESCRIPTION OF ORIGINAL TUMOR. In 1932 Krebs found a spontaneous carcinoma in the inguinal-scrotal fold at the root of the tail of an untreated male mouse of a stock maintained in his laboratory in Copenhagen. The primary tumor was said to be about as large as the kernel of a hazelnut. Wagner, in 1933, described the histology of the primary tumor and of the first tumor transplants. Unfortunately, these two tumors are not always kept separate in Wagner's account, but the following description apparently applies to the primary tumor:

It was a solid carcinoma composed of anastomosing cords of cells. The center of such cords was composed of cells arranged in an irregular pattern, whereas cells of the periphery were palisaded. There was no evidence of cornification. The individual cells were usually round or oval in shape and varied considerably in size. The cells possessed very little cytoplasm, and their nuclei were round or oval and contained only a few chromatin granules. The chromatin granules formed a meshwork in the nucleus, with large clumps at the peripheral nuclear membrane. The tumor cell usually contained one central nucleolus. Mitotic figures were numerous. The extensive stroma was sharply delimited from the neoplastic cells and revealed an inflammatory reaction.

The tumor was believed to have been derived from either the mammary gland or the skin. Wagner reasoned that the skin was not the site of origin, for there was no apparent anatomic connection between the tumor and the epidermis, and the tumor exhibited no evidence of cornification. He concluded that the Krebs 2 Carcinoma represents the rare finding of a mammary tumor in a male mouse.

TRANSPLANTATION STUDIES. The tumor in the early transplant generations was described as having a nodular surface resembling a mulberry, and a soft consistency due to central necrosis and hemorrhage. The surrounding host tissues were infiltrated by the tumor. In some hosts, the transplant tumor metastasized to the lungs; in later generations it metastasized also to lymph nodes. Suspensions of ground tumor pulp or small pieces of tumor tissue were transplanted subcutaneously into the axillary region of Krebs' stock mice. At first, the transplanted tumor grew successfully in only 10 to 25 percent of the mice inoculated. However, in later transplant generations, 70 to 80 percent, and eventually 100 percent, of the transplants grew. The tumor rarely regressed. Mice bearing subcutaneous transplant tumors died about four

weeks after inoculation. The tumor could be transplanted to host mice of almost any genetic strain.

In 1950 Klein and Klein developed an ascites form of the tumor by successive transplantation of it into the peritoneal cavity of albino host mice (strain A and Swiss mice). They designated this line of the tumor as Krebs 2 Ascites Tumor. Following intraperitoneal inoculation of ascitic fluid containing cells of the Krebs 2 Tumor, the ascitic fluid that forms in the peritoneal cavity of the host mouse contains a heavy suspension of tumor cells. Subcutaneous or intramuscular inoculation of such ascitic fluid produces a solid tumor at the site of inoculation. The ascites tumor kills Swiss female host mice about 11 days following inoculation with the stock tumor. However, some of the clones derived from this tumor kill the host mouse in six days.

DESCRIPTION OF THE CURRENT SOLID TUMOR. A BALB/c mouse that had received an intramuscular inoculation of ascitic fluid containing cells of the Krebs 2 Tumor was killed 12 days after inoculation. A tumor nodule, measuring 10 x 5 x 5 mm., was found at the site of inoculation. This friable grayish yellow mass shows a central area of necrosis with little or no evidence of hemorrhage. The skeletal muscle in the region of the transplanted tumor is extensively infiltrated by tumor tissue. No metastases are observed.

Microscopically, there are, in addition to the central necrotic areas, individual necrotic cells and multiple small foci of necrosis in the peripheral third of the tumor. A zone of granulation tissue surrounds portions of the tumor transplant. The tumor has a medullary appearance and possesses no specific histologic pattern. The cells are closely approximated to each other, are round, oval, or polygonal, and vary in size (fig. 253). The cell membrane is usually distinct, and the cytoplasm is homogeneous and eosinophilic. Ninety percent of the cells have one round or oval nucleus. The remaining cells have multilobated or multiple nuclei that vary in size and shape. The nuclear membrane stains heavily, and chromatin granules are concentrated on its inner aspect or scattered throughout the nucleus. The majority of the nuclei possess from 2 to 5 round or rod-shaped nucleoli. As many as seven mitotic figures, many of which are atypical in form, can be found in an oil immersion field. Hauschka and Levan (unpublished observations) have found that the mean mitotic index for the tumor is between 2 and 3 percent and reaches a peak of 7 percent during the early part of the growth phase.

There is only a small amount of connective tissue within the tumor, and this is largely confined to the region of the small thin-walled blood vessels. The tumor cells do not survive more advantageously in the perivascular region, as they do in some other types of tumor. In large areas of the Krebs 2 Tumor, almost every tumor cell is surrounded by delicate wavy reticular fibers (fig. 254). In other areas, reticular fibers surround groups of 8 or 10 neoplastic cells. A few small areas of the tumor contain no reticular fibers. Collagenic

KREBS 2 TUMOR. MOUSE

(Tumor-bearing animal courtesy of Dr. Dean Burk, National Cancer Institute, Bethesda, Md.)

Figure 253. Photomicrograph of intramuscular transplant tumor showing the morphology of the tumor cell and several mitotic figures. Hematoxylin and eosin stain. X 915. N. C. I. 8234; A. F. I. P. Acc. No. 219934-254.

Figure 254. Photomicrograph of intramuscular transplant tumor. Almost every viable tumor cell is surrounded by delicate reticular fibers. Wilder's silver preparation. X 930. N. C. I. 8237; A. F. I. P. Acc. No. 219934-255.

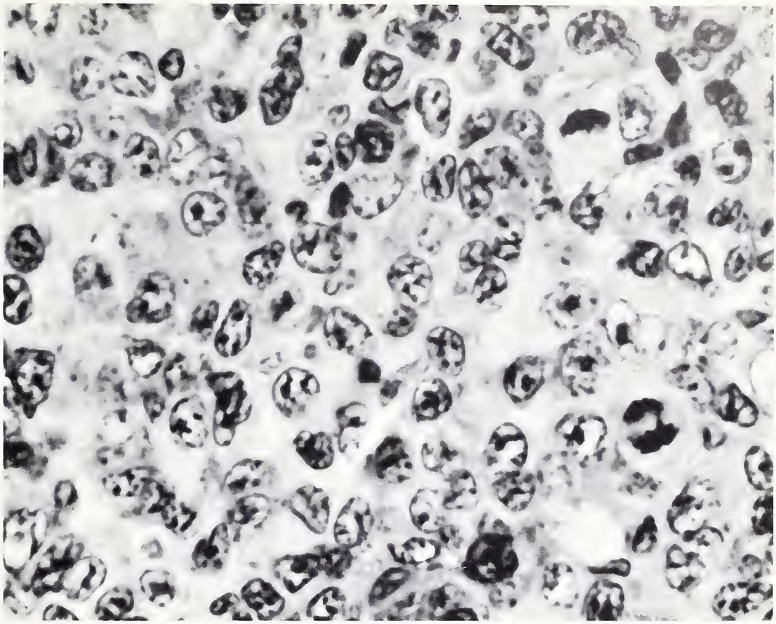

Fig. 253

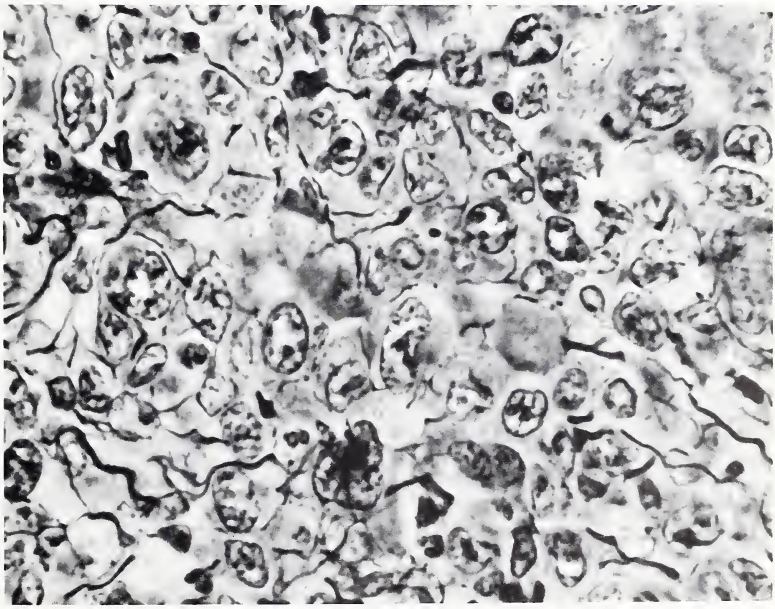

Fig. 254

KREBS 2 TUMOR. MOUSE

Figure 255. Photomicrograph of intramuscular transplant tumor showing a cross section of a nerve fiber situated deep within the tumor tissue. Hematoxylin and eosin stain. X 460. N. C. I. 8232; A. F. I. P. Acc. No. 219934–256.

Figure 256. Photomicrograph of intramuscular transplant tumor showing a skeletal muscle fiber deep within the tumor. Hematoxylin and eosin stain. X 445. N. C. I. 8233; A. F. I. P. Acc. No. 219934–257.

Figure 257. Photomicrograph of ascites tumor showing the cells of the ascites form of the tumor invading the subperitoneal musculature. Hematoxylin and eosin stain. X 87. N. C. I. 8229; A. F. I. P. Acc. No. 219934–258.

Figure 258. Photomicrograph of a stained smear of the peritoneal fluid of a mouse bearing ascites tumor showing the morphology of the cells in the ascitic fluid. Giemsa stain. X 1250. N. C. I. 8247; A. F. I. P. Acc. No. 219934–259.

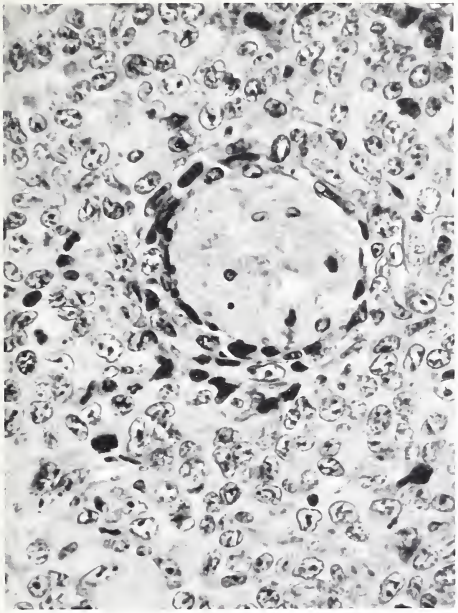

Fig. 255

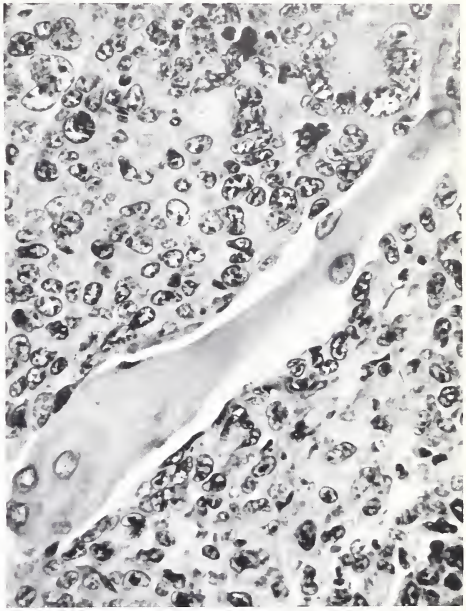

Fig. 256

Fig. 257

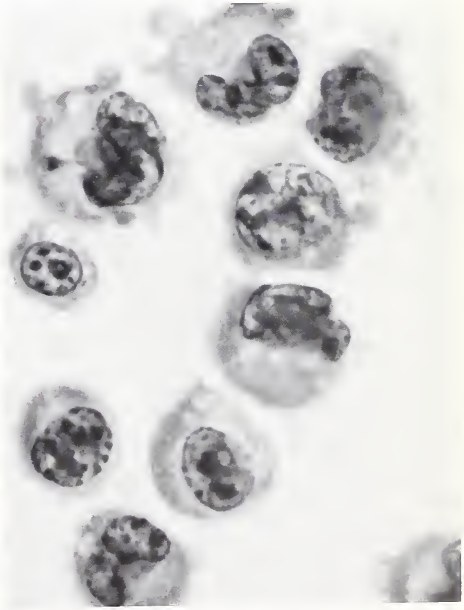

Fig. 258

fibers are numerous around the periphery of the tumor transplant but are scanty within the tumor proper. Nerves (fig. 255), blood vessels, adipose tissue, and skeletal muscle of the host (fig. 256) are present deep within the tumor. This leads to the belief that the collagenic fibers within the tumor are also preformed.

It is clear that the present transplanted Krebs 2 Tumor is a highly undifferentiated neoplasm that cannot be classified with certainty either as carcinoma or sarcoma. Its undifferentiated state is attested by the undeveloped form of its cells and its primitive architectural pattern. The tumor has probably undergone profound changes in histologic pattern during its 23 years of transplantation. Our preference for a name is the Krebs 2 Tumor.

DESCRIPTION OF THE KREBS 2 ASCITES TUMOR. A BALB/c mouse that had been inoculated intraperitoneally with the Krebs 2 Ascites Tumor was killed 12 days later. At necropsy, the peritoneal cavity contains about 5 cc. of cloudy yellow ascitic fluid. The surface of the entire peritoneum appears dull and hyperemic, and friable yellow tumor nodules are found on it.

The histologic characteristics of the tumor nodules on the peritoneum (fig. 257) are the same as those of the intramuscular tumor transplant. Both the parietal and visceral peritoneal surfaces are covered with a sheet of loosely arranged neoplastic cells. These tumor cells infiltrate the subperitoneal connective tissue, muscle, and pancreas at numerous sites. Except for the pancreas, none of the viscera is infiltrated with tumor tissue. The spleen shows erythropoiesis, myelopoiesis, and follicular hyperplasia. The alveolar septa of the lungs contain numerous neutrophilic leukocytes. Histologic smears of the ascitic fluid reveal many tumor cells, with few cells of other types (fig. 258). These cells rarely form solid aggregates of tumor tissue. Many of the cells have one or more cytoplasmic vacuoles. The neoplastic cells of the ascitic fluid resemble closely those of the solid tumor.

References

Hauschka, T. S., and Levan, A. Inverse relationship between chromosome ploidy and host-specificity of sixteen transplantable tumors. Exper. Cell Research, 4:457–467, 1953.

————, and Levan, A. Personal communication.

Klein, G., and Klein, E. The transformation of a solid transplantable mouse carcinoma into an "ascites tumor." Cancer Research, 11:466–469, 1951.

Levan, A., and Hauschka, T. S. Endomitotic reduplication mechanisms in ascites tumors of the mouse. J. Nat. Cancer Inst., 14:1–43, 1953.

Poulson, P. R. Studie over Tidsfaktorn ved Rontgenbestraaling of Cancereller, pp. 31–34. Aarhus: Universitetsforlaget, 1944.

Wagner, A. Undersogelser over cancerresistensen hos hvide mus. Aarhus, Stiftsbogtrykkerie A/S, pp. 17–19, 1933.

Tumor C–1300. Mouse

SYNONYMS: Neuroblastoma C1300; C–1300.

DEFINITION. An undifferentiated tumor described as primary in the region of the spinal cord of an A/Jax mouse.

HISTORY AND DESCRIPTION OF ORIGINAL TUMOR. Tumor C-1300 was found in a 4-month-old male A/Jax strain mouse in 1940 at the Roscoe B. Jackson Memorial Laboratory, Bar Harbor, Maine. It was described as originating spontaneously in the region of the spinal cord and projecting into the abdomen as an irregular, red and white tumor, measuring 1.8 x 2.5 x 3.0 cm. In 1947 Gorer identified it histologically as a round cell tumor and added that it might possibly be a neuroblastoma.

TRANSPLANTATION STUDIES. The tumor was transplanted to A/Jax mice and to hybrids of this strain. More recently, the tumor has been transplanted by subcutaneous, intramuscular, and intraocular inoculation into mice of strains A and C57 brown, and into A backcross mice. A subcutaneous transplant becomes palpable within four days and kills the host within 21 to 30 days. The tumor grows in almost 100 percent of the hosts and is usually transplanted every 10 days. On July 23, 1954, C-1300 was in its 448th transplant generation at the Jackson Memorial Laboratory.

DESCRIPTION OF CURRENT TUMOR. The subcutaneous transplant tumor is soft, nodular, and pink, and it elevates the skin to form a mushroom shaped lesion. It invades the adjacent tissues and metastasizes to the regional lymph nodes. Eichwald and his associates described large metastatic tumors beneath the skin of the neck that were derived from transplants growing in the anterior chamber of the eye.

Microscopically, the periphery of the tumor is demarcated by an incomplete capsule of connective tissue and by the compressed dermis, both of which, although infiltrated by tumor cells, show little inflammatory reaction. The blood vessels, which are of capillary size, are not numerous and are confined to the small amount of connective tissue stroma present in the tumor. Hemorrhage is absent, and degeneration and necrosis are minimal. There are two types of cell in the tumor: the principal cell and the stromal cell. The prevailing histologic pattern, which resembles that of a carcinoma, consists of round sheetlike collections of the so-called "principal cells" surrounded by collagenic or reticular fibers or both, among which are found the so-called "stromal cells" (fig. 259).

The principal cell varies from 25 to 40 microns in diameter, but it is otherwise uniform in appearance (fig. 260). The cell membrane is often indistinct except in mitotically dividing cells. The cytoplasm has a washed-out appearance, being pale and granular. The nuclei are round or oval, and much of the nuclear chromatin is concentrated as punctate granules around the nuclear membrane. There are 1 to 3 small nucleoli.

The stromal cell is closely associated with the reticulum and collagen. It varies widely in size and shape and is generally deeply stained (fig. 261). The structure of this cell is best revealed in the silver preparation in which, although the entire cell body is dark, its component parts are distinguishable.

TUMOR C–1300. MOUSE

(Fixed tissue and paraffin blocks containing the transplant tumor courtesy of Dr. E. J. Eichwald, Laboratory for Experimental Medicine, Montana Deaconess Hospital, Great Falls, Mont.)

Figure 259. Photomicrograph of subcutaneous transplant tumor. The principal cells are collected into small round areas that are more or less surrounded by thin strands of the dark staining, so-called stromal type of cell. Hematoxylin and eosin stain. X 160. N. C. I. 9727; A. F. I. P. Acc. No. 219934–260.

Figure 260. Photomicrograph of subcutaneous transplant tumor showing the contrast between the principal cell and the stromal cell. Hematoxylin and eosin stain. X 820. N. C. I. 8325; A. F. I. P. Acc. No. 219934–261.

Figure 261. Photomicrograph of subcutaneous transplant tumor showing the intimate association between the reticular fibers and the stromal cell. Wilder's silver preparation. X 565. N. C. I. 8304; A. F. I. P. Acc. No. 219934–262.

Figure 262. Photomicrograph of subcutaneous transplant tumor. A large stromal cell is heavily impregnated with silver, and its processes partially embrace a principal cell. Wilder's silver preparation. X 970. N. C. I. 8303; A. F. I. P. Acc. No. 219934–263.

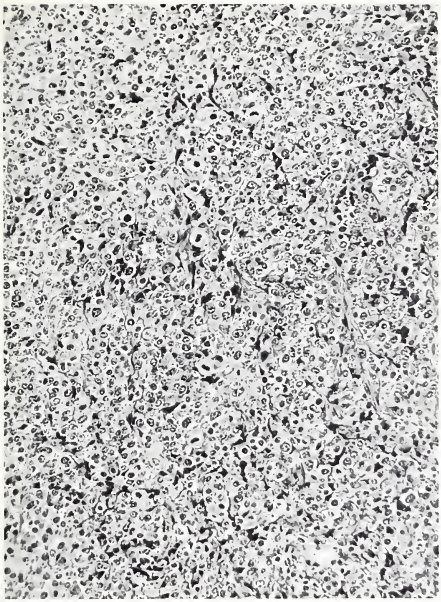

Fig. 259

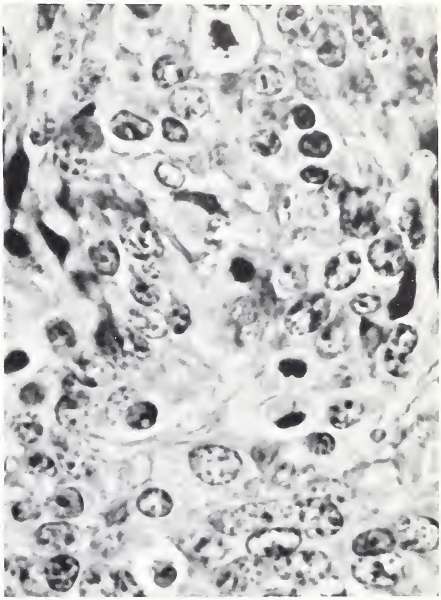

Fig. 260

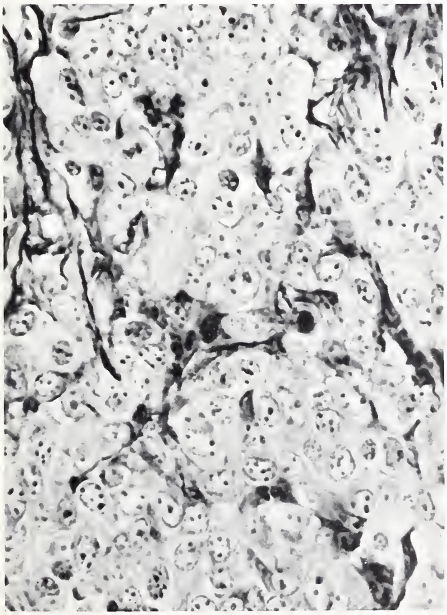

Fig. 261

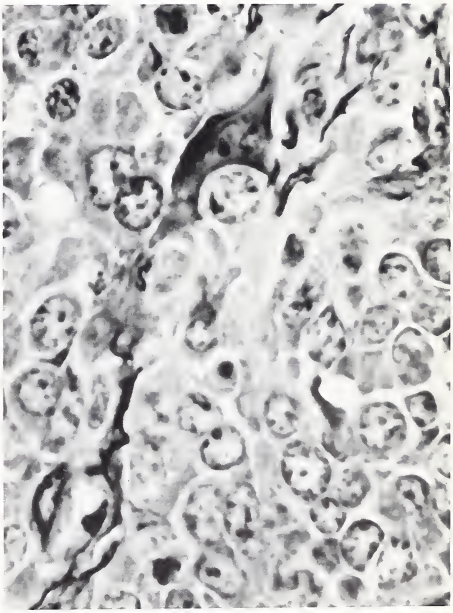

Fig. 262

The nucleus and cytoplasm of some of the cells contain precipitated granules of silver of the same black intensity as that of reticulum. The cell may be small and appear as an almost bare nucleus, or it may be large, with abundant cytoplasm and spider-like processes. The large cell with its processes may measure 50 microns in length. Various cell forms fall between these two extremes. Some nuclei are round, oval, or elongated; others are still more irregular and many resemble in outline crenated red blood cells. The nucleus contains innumerable irregular clumps of chromatin and sometimes 1 to 3 nucleoli. A few mitotic figures can be found. The cytoplasm is heavily impregnated with silver, and the cell processes, which are intimately related to the reticular fibrils, seem to be continuous with those of adjacent cells, suggesting a syncytial arrangement. Sometimes processes which emanate from a single stromal cell partially or completely surround an adjacent principal neoplastic cell (fig. 262). The entire stromal cell is stained black in iron alum hematoxylin preparations, but its processes are somewhat lighter in color than the remainder of the cell. With hematoxylin and eosin, the entire cell stains darkly, but generally the nucleus can be distinguished from the cytoplasm by its more basophilic quality, although its internal structure is less well delineated than in the silver or iron alum hematoxylin preparations. From a study of the hematoxylin and eosin preparation, consideration was given to the possibility that the stromal cell may simply represent a degenerated and necrotic principal cell. However, the structural components of the stromal cell are so well preserved in the other coloring procedures that we believe this cell is viable and represents an independent cell type.

Intraocular as well as subcutaneous transplants have been examined. Although in most respects the characteristics of the two transplant tumors are similar, in the anterior chamber transplant there are not nearly so many stromal cells, and there is a suggestion of palisading. Since the exact site of origin of C–1300 is unknown and its present histologic classification in doubt, the tumor is grouped along with the other undifferentiated neoplasms. We are not able to classify it as a neuroblastoma.

References

Eichwald, E. J., Evans, R. G., and Browning, G. B. The significance of the anterior chamber in tumor transplantation. I. Transplantation of mouse neuroblastoma C1300 to homologous hosts. Cancer Research, 10:483–485, 1950.

———, and Chang, H. Y. The significance of the anterior chamber in tumor transplantation. II. The nature of tumor growth beyond the anterior chamber. Cancer Research, 11:811–813, 1951.

———, Chang, H. Y., and Landa, M. The significance of the anterior chamber in tumor transplantation. III. Natural resistance and acquired immunity. Cancer Research, 12:490–494, 1952.

Gorer, P. A. Antibody response to tumor inoculation in mice. With special reference to partial antibodies. Cancer Research, 7:634–641, 1947.

Klein, G. Comparative studies of mouse tumors with respect to their capacity for growth as "ascites tumors" and their average nucleic acid content per cell. Exper. Cell Research, 2:518–573, 1951.

Flexner-Jobling Carcinosarcoma. Rat

SYNONYMS: Flexner-Jobling Carcinoma; Flexner-Jobling Tumor.

DEFINITION. A carcinosarcoma that arose spontaneously in an albino stock rat, possibly as a mixed tumor of the seminal vesicle.

HISTORY AND DESCRIPTION OF ORIGINAL TUMOR. The Flexner-Jobling Carcinosarcoma originated spontaneously in 1906 in a white male stock rat at the Rockefeller Institute in New York City. At necropsy, a firm, ovoid, nodular tumor the size of a walnut was found attached to the left seminal vesicle. The tumor, covered with peritoneum, projected into the abdominal cavity. It was white or yellowish white and cut with difficulty. No metastases were found.

Flexner and Jobling were in doubt as to the exact histologic classification of the tumor. They considered that it might be either a teratoma or a mixed tumor or even that the growth represented a collision tumor. They described three distinct histologic patterns, each existing in different areas of the neoplasm.

Distal to its attachment to the seminal vesicle, the tumor was composed of irregular whorls and bands of polymorphous and spindle-shaped cells giving it a sarcomatous appearance. Parts of the tumor attached to the seminal vesicle revealed this same pattern and also contained nests of epithelial cells, small acini, and papillary tubular structures. Another part of the tumor consisted of compound mucous or serous glands. These structures were adjacent to a large branched tube which was lined by tall epithelial cells arranged in fine papillary formation. A discontinuous wall of connective tissue and smooth muscle fibers surrounded the entire tumor.

TRANSPLANTATION STUDIES. In transplanted tumors of the early generations, two histologic types of tissue could be distinguished: carcinoma and carcinosarcoma. During succeeding generations the histologic pattern became stabilized as that of an undifferentiated carcinoma. In these subsequent transplant generations, the tumor became more virulent, as indicated by its successful growth in a progressively greater percentage of hosts. It regressed less often and metastasized more frequently than in its early transplant generations. The metastases were found in the lung, pancreas, and kidney.

Jobling discovered that many of the host rats in which regression of the tumor had occurred were resistant to a subsequent second inoculation with this tumor. On the other hand, he found that growth of the transplanted tumor could be enhanced by a heated emulsion of tumor cells injected subcutaneously or intraperitoneally into the host 10 days prior to inoculation with the

tumor. The transplanted tumor grew more successfully in these pretreated hosts and regressed less often than it did in untreated rats or in rats inoculated with an unheated emulsion of tumor cells.

At present, the Flexner-Jobling Tumor grows successfully in many different strains of rats. Although the transplant begins to grow in 100 percent of animals inoculated, it regresses in 25 percent of them. Following subcutaneous inoculation, the tumor becomes palpable in five days, measures approximately 3 cm. in diameter within 14 days, and kills the host within 17 to 70 days. The tumor invades the adjacent host tissues and occasionally metastasizes to the lung. In June 1951, it was in its 406th transplant generation.

DESCRIPTION OF CURRENT TUMOR. A 14-day-old subcutaneous transplant of the Flexner-Jobling Carcinosarcoma in the right groin of a host rat measures 2.3 cm. in average diameter and is surrounded by a well defined capsule. The tumor tissue is granular, soft, and gray. The histologic pattern consists of columns, cords, and sheets of epithelial-like cells with indistinct borders that merge with one another to form a kind of syncytium (figs. 263–265). Other cells, probably of connective tissue origin, are stellate and possess many processes. These stellate cells are intimately associated with the epithelial-like cells which are sometimes surrounded by the processes of the former.

The carcinoma cell is fairly uniform in size. It may be polygonal or occasionally cuboidal or columnar. The cell membrane is indistinct except when stained by phosphotungstic acid—hematoxylin. The cytoplasm is slightly granular, acidophilic, and homogeneous in preparations fixed by Helly's formol-Zenker method (fig. 266). By contrast, when fixed in formalin, the cytoplasm generally contains vacuoles of various sizes that are often traversed by thin strands of cytoplasm (fig. 267). The cytoplasm contains no inclusion bodies or material that is periodic acid—Schiff-positive. The nucleus of this carcinoma cell is generally ovoid, rarely lobate, and its diameter varies from 20 to 35 microns. The well stained nuclear membrane encloses a few fine chromatin granules and usually one large deeply basophilic nucleolus. Two mitotic figures may be found in every high power field. They are of normal form.

The stroma is composed of mature connective tissue, and within it are many of the stellate tumor cells already mentioned. The stroma is most conspicuous in perivascular regions. From the periphery of the blood vessels short strands of stroma containing reticular and a few collagenic fibrils extend into the tumor, where they surround individual tumor cells or groups of cells. In many areas, the pattern of the reticulum resembles that of a carcinoma (fig. 268).

The stellate cells bear no fixed relationship to the reticulum or to the blood vessels. They generally stain more deeply than the epithelial cells in hema-

toxylin—eosin preparations. Often several stellate cells form a short continuous chain. In formalin fixed tissue, this chainlike arrangement is especially evident where the stellate cells are in close relationship to the vacuolated epithelial cells. The stellate cell contains basophilic cytoplasm and one or several elongated, ovoid, or triangular nuclei. The nucleoli of the stellate cell often resemble those of the epithelial cell.

The tumor is surrounded by a capsule of loose edematous fibrous tissue containing a few inflammatory cells, most of which are lymphocytes. Although the tumor is well circumscribed, there may be neoplastic invasion of the capsule. The blood vessels of the tumor are numerous. They are almost all thick walled and of capillary or venule diameter.

Regressive changes occur early, and by the seventh day following transplantation the central three fourths of the transplant tumor may be necrotic except for the cuffs of viable tumor cells that surround blood vessels. Coincident with tumor regression, fibroblasts invade the areas of necrosis, and the lesion is converted into a soft fibrous mass that ultimately becomes contracted and scarred.

The tumor possesses certain characteristics that resemble those of a carcinoma. However, the carcinoma-like cells are associated with other neoplastic cells that are stellate in shape and may have originated from connective tissue, thus raising the question as to whether the tumor is not of mixed type. The original tumor was considered to be a mixed tumor, a collision tumor, or a teratoma. The early generation transplants resembled either a carcinoma or a carcinosarcoma. In succeeding generations, the pattern was thought to be more like that of an undifferentiated carcinoma. On the basis of our study of the present tumor, we are inclined to classify it as a carcinosarcoma and to use the name Flexner-Jobling Carcinosarcoma.

References

Flexner, S., and Jobling, J. W. Infiltrating and metastasising sarcoma of the rat. J. A. M. A., 48:420, 1907.

———, and Jobling, J. W. Studies Upon a Transplantable Rat Tumor. Originally Regarded as a Sarcoma; Probably a Teratoma from which an Adeno-Carcinoma Developed. Monograph 1, The Rockefeller Institute for Medical Research, 1910.

Jobling, J. W. The Biology of a Mixed Tumor of the Rat. Monograph 1, The Rockefeller Institute for Medical Research, 1910.

Schrek, R. A quantitative study of the growth of the Walker rat tumor and the Flexner-Jobling rat carcinoma. Am. J. Cancer, 24:807–822, 1935.

Sugiura, K., and Stock, C. C. Studies in a tumor spectrum. I. Comparison of the action of methyl-bis (2-chloroethyl) amine and 3-bis (2-chloroethyl) aminomethyl-4-methoxymethyl-5-hydroxy-6-methylpyridine on the growth of a variety of mouse and rat tumors. Cancer, 5:382–402, 1952.

FLEXNER-JOBLING CARCINOSARCOMA. RAT

(Tumor-bearing animal courtesy of Dr. Kanematsu Sugiura, Sloan-Kettering Institute for Cancer Research, New York City)

Figure 263. Photomicrograph of transplant tumor. Low power view showing a thin border of viable tumor tissue in the periphery of the mass. Deep within the tumor the tissue is necrotic except for periadventitial cells. (Helly's formol-Zenker fixation). Hematoxylin and eosin stain. X 24. N. C. I. 8513; A. F. I. P. Acc. No. 219934–264.

Figure 264. Photomicrograph of transplant tumor. An area of the tumor in which the stroma is more abundant than in the area illustrated in figure 265. Some of the cells are cuboidal and columnar, and others are polygonal. (Helly's formol-Zenker fixation). Hematoxylin and eosin stain. X 385. N. C. I. 8527; A. F. I. P. Acc. No. 219934–265.

Figure 265. Photomicrograph of transplant tumor showing the arrangement of the tumor cells in relation to the stroma and collagenic fibers. The epithelial cells of the tumor are fairly uniform in appearance. A few stellate cells can be identified in the stroma. (Helly's formol-Zenker fixation). Van Gieson stain. X 325. N. C. I. 8531; A. F. I. P. Acc. No. 219934–266.

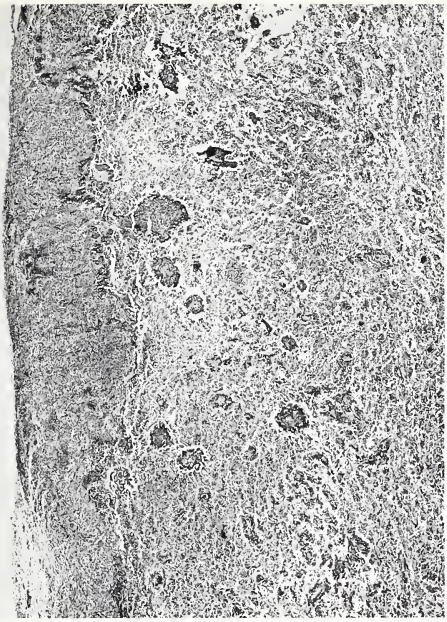

Fig. 263

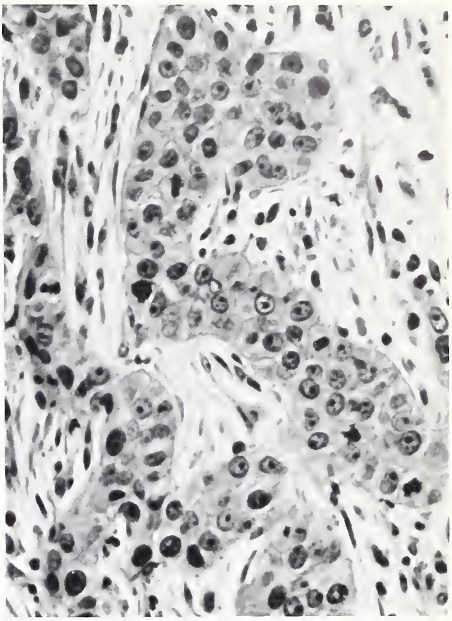

Fig. 264

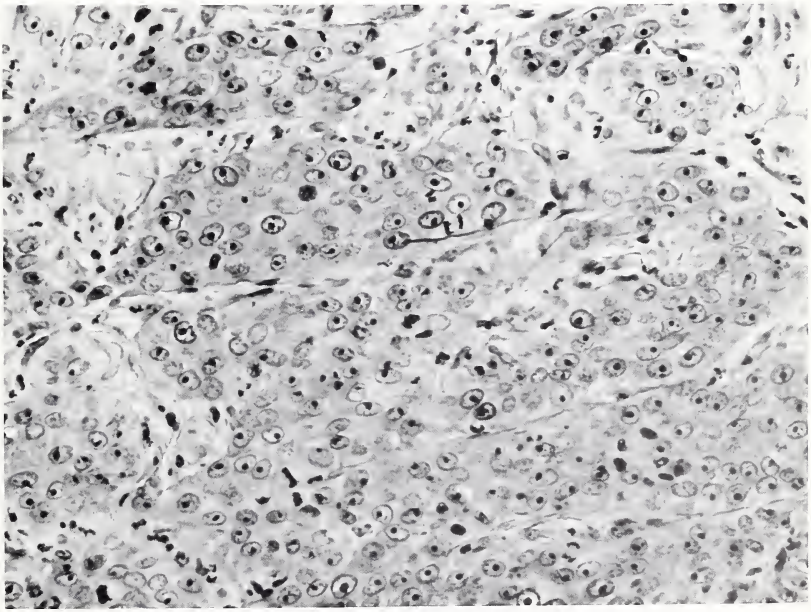

Fig. 265

FLEXNER-JOBLING CARCINOSARCOMA. RAT

Figure 266. Photomicrograph of transplant tumor showing the fine details of the epithelial cells when fixed in Helly's formol-Zenker. Note the intermingled spindle-shaped cells. Hematoxylin and eosin stain. X 900. N. C. I. 8538; A. F. I. P. Acc. No. 219934–267.

Figure 267. Photomicrograph of transplant tumor showing groups of stellate cells and epithelial cells. Note the marked vacuolization of the epithelial cells when fixed in 10% formalin. Hematoxylin and eosin stain. X 900. N. C. I. 8537; A. F. I. P. Acc. No. 219934–268.

Figure 268. Photomicrograph of transplant tumor. The distribution of the reticular fibers suggests a carcinomatous pattern. (Helly's formol-Zenker fixation). Wilder's silver preparation. X 385. N. C. I. 8529; A. F. I. P. Acc. No. 219934–269.

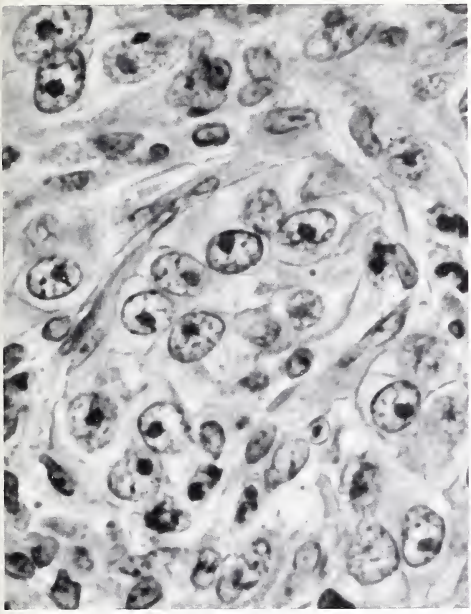

Fig. 266

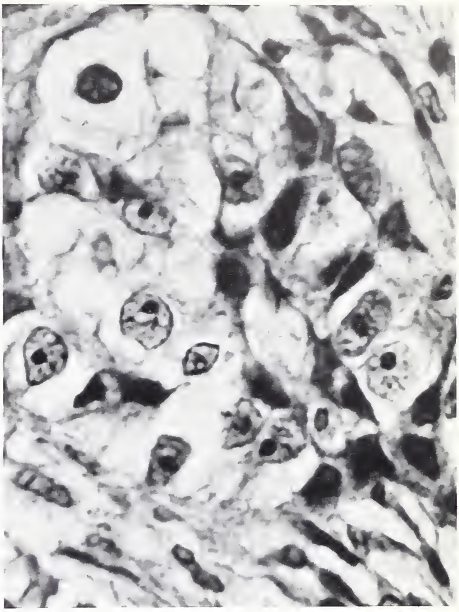

Fig. 267

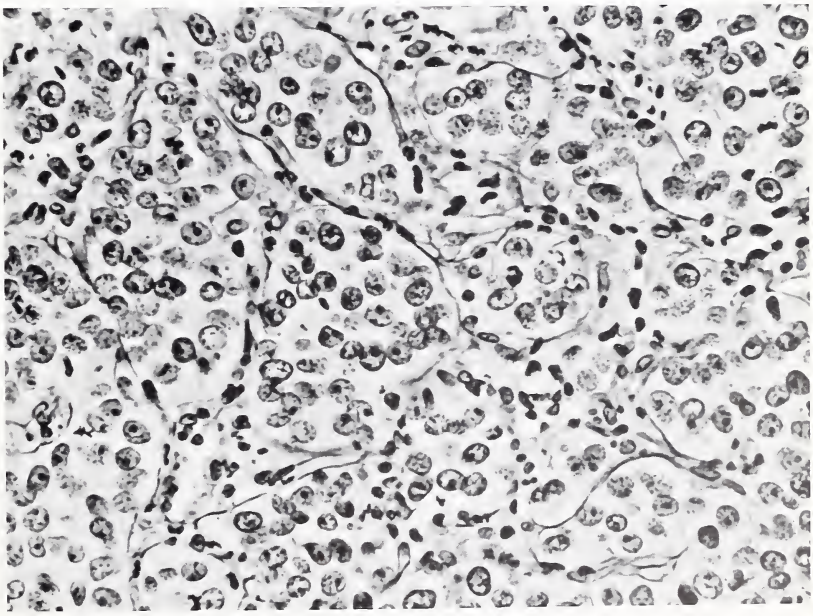

Fig. 268

Jensen Sarcoma. Rat

SYNONYMS: Jensen Rat Sarcoma; Jensen Tumor; "JRS."

DEFINITION. A rapidly growing undifferentiated pleomorphous-cell tumor that arose in a gray rat inoculated with acid-fast bacilli isolated from the lesions of pseudotuberculous enteritis of a cow.

HISTORY AND DESCRIPTION OF ORIGINAL TUMOR. On January 29, 1907, C. O. Jensen, in his laboratory in Copenhagen, necropsied two gray, spotted rats that Bernhard Bang had inoculated some time previously with acid-fast bacilli derived from the lesions of pseudotuberculous enteritis of a cow. The bacteriologic results of the inoculation were negative, but both rats, which were cage mates, were found to have lesions diagnosed as sarcoma. One rat had solitary and conglomerate neoplastic nodules on the peritoneum, mesentery, and omentum, and in the liver and the lungs. Only the lungs of the other rat were involved, and the lesions in this second animal consisted of many small nodules the size of a millet seed. Jensen described the tumors as being similar histologically in the two rats. They were composed almost exclusively of spindle-shaped cells with sparse fibrils and few blood vessels. There were only a few areas of necrosis.

TRANSPLANTATION STUDIES. Tumor tissue from each rat was transplanted in series. Careful study of the original report does not reveal which of the two tumors is the one now perpetuated as the Jensen Tumor. The neoplasms were morphologically similar in the two animals and biologically so nearly alike as to lead Jensen to state that he believed they were caused by the same etiologic factor. Pen-bred Copenhagen rats and wild rats secured from the streets of several large European cities were used as hosts for the first several transplant generations. The rats were inoculated subcutaneously and intraperitoneally with minced tumor tissue. The tumor transplants grew successfully in 87 percent of the hosts in the 3rd transplant generation. Thereafter they grew successfully in 100 percent of Jensen's rats. The transplant tumor of the 6th generation measured 8 to 10 cm. in diameter, 6 to 8 weeks following inoculation.

At present, the Jensen Sarcoma can be grown in rats of the Sherman, Wistar, and Sprague-Dawley strains. It grows successfully in 80 to 90 percent of the hosts but regresses in about 18 percent. The tumor transplant becomes palpable in 5 or 6 days and kills the host within 17 to 56 days after inoculation. The tumor invades the adjacent tissues of the host, but it rarely metastasizes. It may show extensive necrosis. According to Earle and Voegtlin, tumor growth is more regularly progressive following intramuscular inoculation than following subcutaneous inoculation. Sugiura, in correspondence with us, stated that he has found that the Jensen Sarcoma grows better in Sprague-Dawley rats than in rats of the Sherman or Wistar strains. During a period of 12 months in 1953–1954, he transplanted the Jensen Sarcoma sub-

cutaneously into 500 Sprague-Dawley rats. The transplants grew successfully in 100 percent of the hosts and regressed in 6 percent of them.

DESCRIPTION OF CURRENT TUMOR. The subcutaneous transplant tumor extends along fascial planes and invades the skin. It is surrounded by a capsule of connective tissue which may be incomplete. The peripheral portion of the tumor is firm and grayish white. The central part of the tumor is hemorrhagic and necrotic. The tumor cells grow in broad sheets forming large coalescent nodules (fig. 269) that may be surrounded by delicate connective tissue or separated from each other by areas of necrosis. The tumor cell varies from 15 to 35 microns in diameter (fig. 270) and is ovoid or polyhedral. Rarely some of the cells are found to be spindle shaped. The cell membrane is deeply stained. There is a large amount of faintly basophilic cytoplasm that may be coarsely granular but is free of vacuoles and inclusions. The nuclei vary in size, shape, and staining capacity. The nucleus may be ovoid, spheroid, umbilicate, or lobate. The small nuclei are deeply basophilic, having fine chromatin granules with little linin, and 1 to 3 deeply basophilic nucleoli. The large nuclei are vesicular and contain finely clumped chromatin granules with 1 to 4 irregularly shaped nucleoli that stain less intensely than those of the small nuclei. Mitotic figures generally appear in the form of a bar (metaphase), and about three of them may be found in every oil immersion field. The connective tissue stroma is largely confined to the septal and periadventitial areas. The smaller blood vessels are thin walled, irregular in shape, and not numerous. The reticulum is fine and not abundant. Sheets of tumor cells may be surrounded by a reticulum, presenting an alveolar pattern. In some areas that are rich in reticular fibers, an individual cell or a small group of cells may be enmeshed in an argentophilic reticulum (fig. 271).

The original Jensen Tumor came from 1 of 2 rats that had tumors said to be similar and composed of spindle-shaped cells but not further classified. We cannot definitely classify the growth as either a carcinoma or a sarcoma, and it would logically follow that neither of these terms should be used in the name of the tumor. However, since the tumor has been called the Jensen Sarcoma since 1907, we are retaining this name, although the designation "Jensen Tumor" seems preferable to us.

References

Earle, W. R., and Voegtlin, C. Experimental studies on cancer. IV. A comparison of the growth of the Jensen rat sarcoma in subcutaneous and intramuscular transplants. National Inst. Health Bull., 1935.

Jensen, C. O. Ubertragbare Rattensarkome. Ztschr. f. Krebsforsch., 7:45–54, 1909.

Sugiura, K., and Stock, C. C. Studies in a tumor spectrum. I. Comparison of the action of methyl-bis (2-chloroethyl) amine and 3-bis (2-chloroethyl) aminomethyl-4-methoxymethyl-5-hydroxy-6-methylpyridine on the growth of a variety of mouse and rat tumors. Cancer, 5:382–402, 1952.

————. Personal communication.

JENSEN SARCOMA. RAT

(Tumor-bearing animal courtesy of Dr. Kanematsu Sugiura, Sloan-Kettering Institute for Cancer Research, New York City)

Figure 269. Photomicrograph of transplant tumor. A viable area of the tumor showing the extremely cellular type of growth. Hematoxylin and eosin stain. X ·325. N. C. I. 8532; A. F. I. P. Acc. No. 219934-270.

Figure 270. Photomicrograph of transplant tumor. Based on the character of the nucleus, two types of cell are distinguishable. In one, the nucleus is small and hyperchromatic; in the other, the nucleus is 2 to 3 times larger and possesses a more open network than that of the small cell. Narrow strands of stroma are present in the lower right corner. Note numerous mitotic figures. Hematoxylin and eosin stain. X 650. N. C. I. 8535; A. F. I. P. Acc. No. 219934-271.

Figure 271. Photomicrograph of transplant tumor. Individual tumor cells or small groups of cells are enmeshed by an argentophilic reticulum. Wilder's silver preparation. X 330. N. C. I. 9216; A. F. I. P. Acc. No. 219934-272.

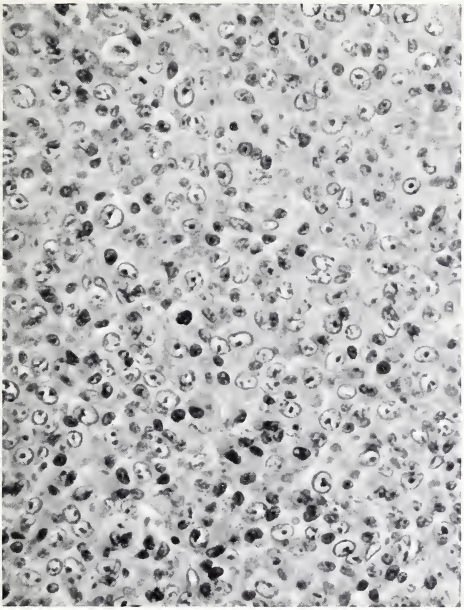

Fig. 269

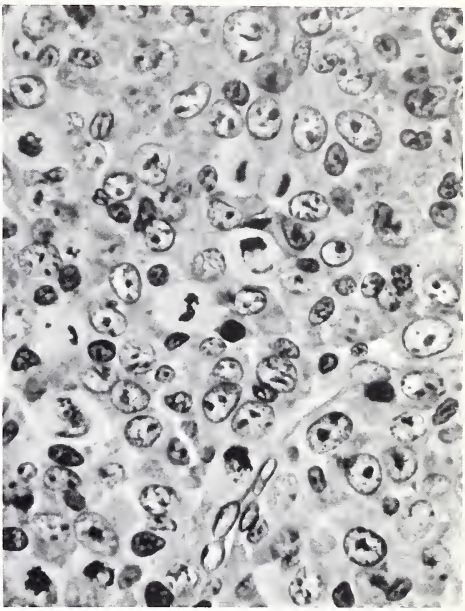

Fig. 270

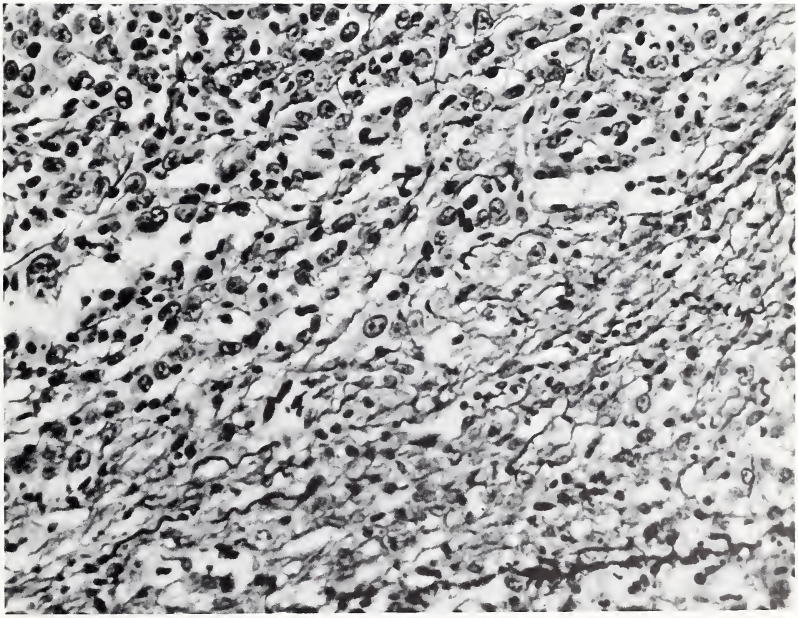

Fig. 271

Yoshida Tumor (Solid and Ascites Forms). Rat

SYNONYMS: Yoshida Ascites Tumor; Yoshida Ascites Sarcoma; Reticulum-Cell-Like Sarcoma, Yoshida; Yoshida Sarcoma.

DEFINITION. An undifferentiated tumor that arose in a pen-bred albino rat that was fed o-aminoazotoluol and painted with potassium arsenite.

HISTORY AND DESCRIPTION OF ORIGINAL TUMOR. The Yoshida Tumor originated in 1943 in a pen-bred albino rat in the laboratory of T. Yoshida in Nagasaki, Japan. The designation "Yoshida Sarcoma" was applied to this tumor in 1948 by the Japanese Cancer Research Association. The animal in which the Yoshida Tumor arose was one of a group of 20 rats fed o-aminoazotoluol for three months, followed by thrice weekly painting of the skin of the back with a solution of potassium arsenite. Toward the end of the third month of painting, a mass was observed in the scrotum of this animal. Several weeks later the rat was killed.

Necropsy revealed a thick milky ascitic fluid which was found to contain a suspension of tumor cells. There was a bilaterally symmetrical mass attached to the capsule and omentum of each testis, and the tumor had also invaded the peritoneum and retroperitoneal tissues. The testes, although atrophied, were not infiltrated by the neoplastic tissue. Yoshida described the pelvic tumor as a round cell sarcoma which in areas resembled a reticulum cell sarcoma, although no reticulum could be demonstrated in Wilder's silver preparations. The liver of this animal also contained a tumor which Yoshida called a hepatoma. It has never been clearly established whether the tumor in the genital omentum and pelvic peritoneum was a primary growth, as Yoshida first considered it to be, or whether it was metastatic from the tumor of the liver. However, Yoshida, temporarily at least, believed the pelvic tumor to be a reticulum cell sarcoma, possibly derived from the Kupffer cells of the liver. After Yoshida read this manuscript in July 1954, he stated that he was still in doubt about the site of origin and the histologic classification of the Yoshida Tumor.

TRANSPLANTATION STUDIES. The ascitic fluid from the original animal was inoculated intraperitoneally into two rats in Yoshida's laboratory. One of these died two days later, but the other survived to develop an ascites tumor. A piece of solid tumor tissue from the pelvic region of the original rat was transplanted subcutaneously to another rat in which a solid tumor developed at the site of inoculation. In subsequent transplant generations, when a fragment of the solid form of the Yoshida Tumor was transplanted intraperitoneally, a milky ascites form of the tumor developed. Conversely, ascitic fluid containing tumor cells introduced subcutaneously into a rat gave rise to a solid tumor at the site of inoculation.

The following technic was used to transplant the Yoshida Tumor. Approximately 0.1 cc. of fluid was withdrawn through a glass capillary tube from

the peritoneal cavity of a rat bearing the transplanted tumor. A portion of the fluid was used for microscopic examination and might contain between 500,000 and 1,000,000 tumor cells per cu. mm. of fluid. The remainder of the ascitic fluid, from 0.05 to 0.1 cc., was injected intraperitoneally into pen-bred albino host rats. Within two or three days, the inoculated host rats developed ascites, and most of them died within 12 days. Occasionally, an inoculated rat survived as long as 24 days. At necropsy, as much as 10 cc. of ascitic fluid and many peritoneal implants were found. The tumor was transplanted initially to pen-bred albino rats, and later to Wistar and Marshall 520 rats, and (Marshall 520 x AXC 9935)F_1 rats. For more than 400 transplant generations (March 1953) the Yoshida Tumor grew successfully in 90 percent of the pen-bred albino rats inoculated with it. The tumor has retained its morphologic pattern during this entire period of transplantation. This initial high percentage of successful transplants without subsequent increase or change in histologic pattern suggests that the intrinsic autonomy of the Yoshida Tumor had reached its end point in the animal in which it originated.

Yoshida ascertained the minimum number of cells required for successful transplantation of the ascites tumor by graduated dilution of ascitic fluid. He found that a droplet of fluid containing a single cell sucked into a micropipette and injected intraperitoneally into a host rat was sufficient to transplant the tumor in 55 percent of the inoculated hosts. However, such inoculation with a single tumor cell produced the ascites tumor within 12 or 13 days, whereas the usual technic, using a larger number of cells, required only two or three days.

DESCRIPTION OF CURRENT TUMOR, SOLID FORM. A transplanted solid tumor, produced by the intramuscular inoculation of ascitic fluid containing tumor cells, reached a diameter of 4 cm. seven days after inoculation. At necropsy, it is found to be composed of glistening, grayish pink, friable tissue. Metastasis to distant points, although occasionally encountered, is not seen in this case.

The solid form intramuscular transplant of the Yoshida Tumor is composed of sheets of round or polygonal cells 20 to 40 microns in greatest diameter (fig. 272). The cell membrane is distinct in the phosphotungstic acid—hematoxylin preparations. The cytoplasm is finely granular and faintly acidophilic. The nucleus occupies approximately one half of the volume of the cell, and it may be round, oval, lobate, or umbilicate in shape. Delicate linin threads beaded with heavy clumps of chromatin radiate from a large central nucleolus. Eight to 10 mitotic figures are found in each high power field and they are often bizarre.

The stroma of the Yoshida Tumor consists of single thin strands of connective tissue containing reticular and collagenic fibrils generally surrounding groups of cells (fig. 273). Blood vessels of capillary size are present in the stroma in viable areas of the tumor. Areas of necrosis may be large and

numerous, and the blood vessels in them are often dilated and thin walled. At the periphery, the tumor extensively invades muscle, bone, and the synovial membrane of the extremity in which it is growing.

Although the pattern of the reticulum is consistent with that of a carcinoma, the undifferentiated character of the tumor cells and the lack of any specific histologic pattern, together with the uncertainty regarding the site of origin of the tumor, have influenced our decision to classify the Yoshida Tumor with the group of undifferentiated neoplasms.

ASCITES TUMOR CELLS. The neoplastic cells of the Yoshida Ascites Tumor are readily distinguishable from leukocytes and from the mesothelial cells of the serosal surface of the peritoneum. The tumor cells are generally spherical or oval and have an average diameter of 30 microns. There is an indistinct cell membrane, and the cytoplasm is generally deeply basophilic, granular, or vacuolated. A large clear cytocentrum is often present. Fat droplets may be demonstrated with the Sudan stains. The nucleus, almost always eccentrically located, is generally oval, round, or umbilicate, with an indistinct nuclear membrane. It is colored reddish violet in Giemsa preparations and contains coarse granules and 1 to 3 large nucleoli. Four to 10 days following intraperitoneal inoculation, neutral red or azure granules in the form of rosettes may be present around a "hof" in the cytoplasm near the nucleus of the cell. Since these granules increase in direct proportion to the length of time following intraperitoneal inoculation, and since they are in inverse proportion to the intensity of nuclear staining, they have been interpreted as degeneration products of the nucleus. Degeneration and necrosis of cells in the ascitic fluid is common, especially eight days or more following inoculation. Mitotic figures are exceedingly numerous and sometimes bizarre. Sato has described V-shaped chromosomes in the mitotic figures.

Following intraperitoneal inoculation with ascitic fluid, deposits of solid tumor are often found on the peritoneum and the surface of abdominal viscera. Underlying structures may become extensively infiltrated with tumor cells. There may be periportal spread to the liver as a result of neoplastic thrombi in the branches of the portal vein. Large tumor masses may be present in the retroperitoneal areas where the tumor also invades blood vessels (fig. 274).

HOST-TUMOR RELATIONSHIP. An inflammatory reaction with effusion is induced by the intraperitoneal transplantation of cells of the Yoshida Tumor. The neutrophilic leukocyte appears in the ascitic fluid within 30 minutes after inoculation of the tumor. These neutrophils increase rapidly in number so that after two hours these cells constitute the major cell element of the inflammatory exudate. However, this preponderance persists only 12 hours. The eosinophilic leukocyte appears within three hours after inoculation and decreases numerically in the exudate as the neutrophils decrease. The number of mononuclear leukocytes increases slowly in the exudate during the first 12 hours following inoculation. Then these cells become numerous and ex-

hibit phagocytic activity by their ingestion of neutrophils. Coincident with this, the tumor cell reveals evidence of sudden multiplication, and from this time onward the tumor cells continue to increase in number and finally dominate the cell population of the ascitic fluid. Thus within 48 to 72 hours, the ascitic fluid contains a large number of tumor cells, relatively few inflammatory and mesothelial cells, and is considered to represent a so-called "pure culture of ascites tumor cells" (figs. 275, 276).

References

Sato, H. On the chromosomes of Yoshida sarcoma. Studies with tumor cells proliferated in the peritoneal cavity of the rat transplanted with a single cell. Gann, 43:1–16, 1952.

———. Intraperitoneal transplantation of the Yoshida ascites sarcoma and the ascites hepatoma to various American strains of rats. J. Nat. Cancer Inst., 15:1367–1378, 1955.

Yoshida, T. The Yoshida Sarcoma, an ascites tumor. Gann, 40:1–33, 1949.

———. Studies on an ascites (reticuloendothelial cell?) sarcoma of the rat. J. Nat. Cancer Inst., 12:947–969, 1952.

———, Muta, Y., and Sasaki, Z. Studien über das "Ascites-Sarcoma." Proc. Imp. Acad. (Tokyo), 20:611, 1944.

Brown-Pearce Tumor. Rabbit

SYNONYM: Epithelioma Brown-Pearce.

DEFINITION. An anaplastic carcinoma considered to have originated in the region of a scar of a syphilitic lesion of the scrotum of a rabbit.

HISTORY OF ORIGINAL TUMOR. In June 1916, Brown and Pearce, at the Rockefeller Institute in New York City, inoculated a full-grown albino rabbit in both scrota with bits of testicular tissue taken from a rabbit infected with Treponema pallidum. Local chancres developed at each inoculation site. The chancres regressed in a short time and were replaced by scars. Meanwhile both testes became fibrotic and atrophic. In April 1919, the rabbit developed late secondary generalized cutaneous lesions. By January 1920, a chronic eczematoid inflammatory process had developed in the skin of the left scrotum. This process persisted, with exacerbations and remissions. In October 1920, a nodule, which subsequently proved to be a malignant tumor, appeared at the site of the primary chancre in the left scrotum. It grew rapidly. Repeated dark field examinations of tissue from the nodule were negative for spirochetes, although these organisms had been found the previous month in a popliteal lymph node. The scrotal nodule was twice excised but recurred. Each recurrence was accompanied by enlargement of the inguinal lymph nodes, and there was extension of the previously noted inflammatory cutaneous process to the ventral abdomen. The animal was killed March 10, 1921.

At necropsy, tumor deposits were present in the liver, bone, bone marrow, spleen, lungs, kidneys, left testicle, inguinal adipose tissue and in the lymph nodes of the pelvis, inguinal region, and retroperitoneal tissues. Chronic in-

YOSHIDA TUMOR. RAT

(Tumor-bearing animal courtesy of Dr. Harou Sato, Fukushima City, Japan; formerly of National Cancer Institute, Bethesda, Md.)

Figure 272. Photomicrograph of solid form of transplant tumor. The tumor is composed of sheets of round or polygonal cells, many of which show sporadic degeneration and necrosis. Mitotic figures are numerous. Hematoxylin and eosin stain. X 400. N. C. I. 9058; A. F. I. P. Acc. No. 219934–273.

Figure 273. Photomicrograph of solid form of transplant tumor. Note the large number of reticular fibers surrounding groups of cells. Wilder's silver preparation. X 670. N. C. I. 9056; A. F. I. P. Acc. No. 219934–274.

Figure 274. Photomicrograph of ascites form of transplant tumor seven days after inoculation. Note the intravascular invasion of tumor cells. Hematoxylin and eosin stain. X 440. N. C. I. 7814; A. F. I. P. Acc. No. 219934–275.

Figure 275. Photomicrograph of cells from the ascitic fluid removed from an animal inoculated seven days previously with the ascites form of tumor. The cells show an eccentrically placed nucleus, near which is a clear area in the cytoplasm. Several cells are necrotic. One cell is in mitosis. Giemsa stain. X 475. N. C. I. 7828; A. F. I. P. Acc. No. 219934–276.

Figure 276. Higher power photomicrograph of one of the cells shown in figure 275. Note vacuoles and granules in the cytoplasm. Giemsa stain. X 1780. N. C. I. 7834; A. F. I. P. Acc. No. 219934–277.

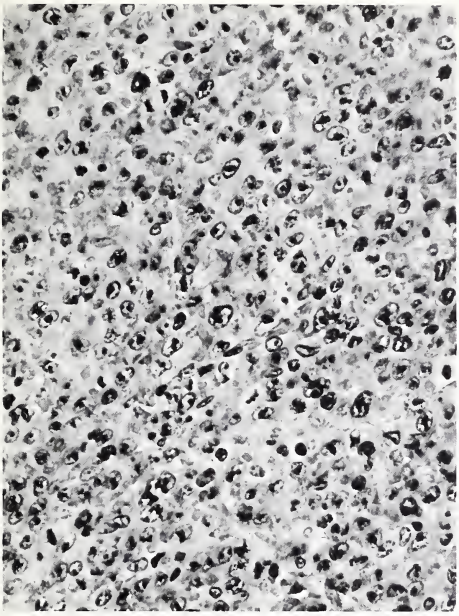

Fig. 272

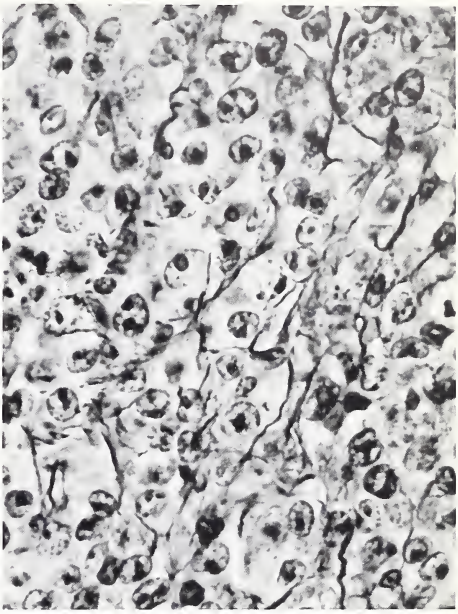

Fig. 273

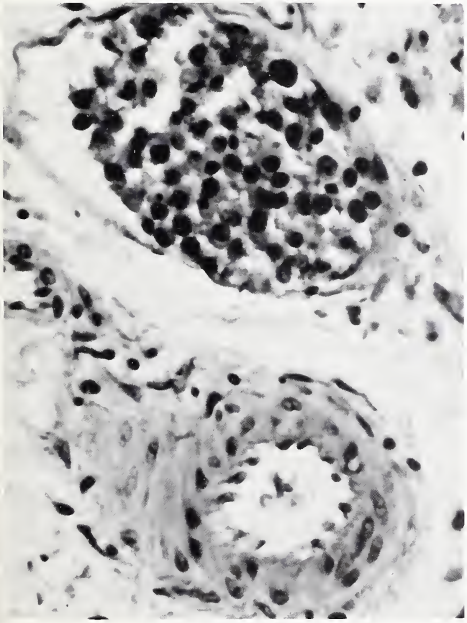

Fig. 274

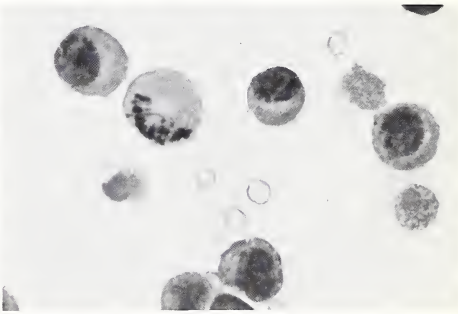

Fig. 275

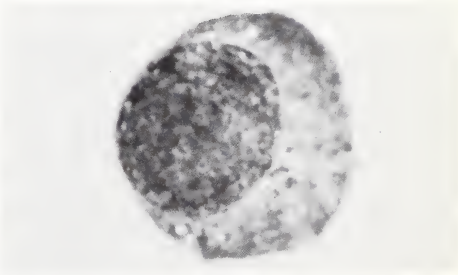

Fig. 276

flammatory and degenerative changes with atypical epithelial proliferation were found to involve the tongue, buccal mucosa, esophagus, and bronchi. There were fibrotic changes in the skin and subcutaneous tissues, with atypical cellular proliferation in the hair follicles. Alterations were described in the endocrine glands, and there was bilateral chronic orchitis. The animal from which the transplantable Brown-Pearce Tumor was derived thus presented a number of abnormal findings, some of which appeared to be significant with reference to the tumor, while others were attributable to syphilis.

Brown and Pearce believed that the tumor in this rabbit arose in the skin of the scrotum. However, their detailed description and illustrations of the scrotal tumor leave considerable doubt in our opinion that this was indeed the primary growth. Moreover, Brown and Pearce stated that because of the varied histologic and cytologic characteristics of the tumors found in the several different locations in this rabbit, they considered the possibility of two primary neoplasms, one in the testicle, the other in the skin of the scrotum. The distribution of the metastatic tumors in the inguinal, pelvic, and retroperitoneal lymph nodes and in the inguinal adipose tissue is consistent with a primary growth in the scrotum or the testicle, or in both of these sites. Substantial arguments can be advanced against a cutaneous origin for the various disseminated tumors observed in the rabbit necropsied by Brown and Pearce. The architectural pattern of the various growths was not uniform, since some had a sarcomatous appearance and others resembled carcinoma. The morphology of the tumor cells also varied, and in some tumors the cells even produced mucus. The widespread metastasis to bones, including the long bones of the upper and lower extremities and the vertebrae and pelvic bones, is very unusual in the case of a primary cutaneous tumor. For a detailed discussion the reader is referred to the original articles by Brown and Pearce which deal voluminously with the many controversial features pertaining to the histologic classification and site of origin of the Brown-Pearce Tumor.

TRANSPLANTATION STUDIES AND BIOLOGIC CHARACTERISTICS. Tumor tissue from a metastatic growth in a left inguinal lymph node of the original rabbit was transplanted to other animals. Brown and Pearce stated (p. 606), "Three attempts were made to transplant the growth to other rabbits. The first attempt was unsuccessful, but by the use of intratesticular inoculations a good growth was obtained in both the second and third series of animals, and subsequent transfers by this method have almost invariably given 100 percent takes." The concomitant syphilitic infection in the tumor-bearing animals was eradicated by arsphenamine therapy.

In a summary of their experience with growth and regression of this tumor, Brown and Pearce stated in 1923 (p. 810): "The ultimate fate of tumor animals is variable. Spontaneous regression is of frequent occurrence, and apparent recovery may take place even after extensive metastases have developed. More often, the disease terminates fatally. The course of the disease may be

fulminating in character with death occurring 6 to 7 weeks after inoculation, or it may be prolonged over a period of more than 6 months, but death usually occurs between 7 weeks and 3 months after inoculation." Distant metastatic growths commonly occurred in these tumor-bearing animals. Casey, in 1938, reported that the Brown-Pearce Tumor, during a period of 15 years of transplantation, had undergone no change in respect to the distribution of the metastases. Death was usually attributable to cachexia, to mechanical causes, or to the effects of neoplastic destruction of one or more of the glands of internal secretion. A tumor that had once begun to grow but later regressed provoked an immune response in its host that inhibited the growth of subsequent transplants.

Different results were reported by Brown and Pearce when they inoculated tumor tissue into sites other than the testicle. The transplant tumor grew in only 20 to 25 percent of animals inoculated by the subcutaneous, intravenous, and intraperitoneal routes. However, it grew in 80 to 90 percent of animals inoculated by the intracutaneous and intramuscular routes, and in nearly 100 percent of animals inoculated by the intracerebral and intraocular routes. The Brown-Pearce Tumor could be successfully transplanted into rabbits of various breeds. It could not be transplanted by inoculation of desiccated material or cell-free filtrates of tumor tissue.

Greene maintained the Brown-Pearce Tumor by serial transfer in the anterior chamber of the eye of rabbits, and he reported that the tumor grew progressively in 100 percent of the animals inoculated. Growth was rapid, and the chamber became filled with tumor tissue within 7 to 10 days. Metastatic growths appeared within 4 to 6 weeks during cold weather, while regression without metastasis was the rule during hot weather. Greene also reported growth following transplantation of the tumor to the eye, testicle, and subcutaneous tissues of mice, hamsters, and rats, but all of these tumors eventually regressed. All attempts to transplant the tumor to guinea pigs were unsuccessful.

Consultation with various investigators working with the Brown-Pearce Tumor reveals that the biologic behavior of the tumor may vary in different laboratories. Thus, one cannot always anticipate its transplantability by various routes of inoculation, the latent period of growth, or the rate of regression. The tumor-bearing animal may die within 10 days after inoculation, or may survive for as long as 100 days.

Casey, in 1932, was able to enhance the susceptibility of the prospective host rabbit to growth of the Brown-Pearce Tumor by pretreating the animal with a saline emulsion of the tumor tissue that had been refrigerated for several weeks. Tumor tissue thus stored was found not to give rise to tumor when injected. Casey designated the active agent the XYZ factor. He later found that the susceptibility of the host was also enhanced, though to a lesser extent, if the material was passed through a Berkefeld filter before injecting it.

The saline emulsion or the cell-free filtrate was injected into one testicle of a rabbit two weeks before the tumor was inoculated into the other testicle. Rabbits thus sensitized by the XYZ factor subsequently developed tumors at the site of inoculation of the fresh tumor tissue more frequently than nonsensitized rabbits. These tumors and their metastases were larger, and the animals died earlier as compared with tumor-bearing animals not so sensitized. Casey believed that the XYZ factor inactivated or masked some hypothetical inhibitory factor that he believed to be present in the fresh tumor tissue of the inoculum. He found that the XYZ factor induced a greater susceptibility to tumor growth even in rabbits such as the Blue Cross and Lilac Cross breeds that possess a natural resistance to growth of the Brown-Pearce Tumor.

DESCRIPTION OF CURRENT TUMOR. A study of several rabbits inoculated with the Brown-Pearce Tumor was made at the National Cancer Institute. The tumor tissue is soft, friable, necrotic, and hemorrhagic. From the inoculation site in the testicle the tumor may spread along the spermatic cord into the peritoneal cavity, which usually becomes heavily seeded with implants. The tumor usually metastasizes to distant organs, although occasionally it may remain confined to the testis. Some of the transplants may regress.

Microscopically, the tumor has a medullary pattern and we consider it to be an anaplastic carcinoma. It is composed of thick cords of tumor cells supported by an inconspicuous stroma of connective tissue containing a few reticular fibers and blood vessels of small caliber (figs. 277–280). The neoplastic cell is round or oval. The cytoplasm is pale and slightly basophilic. The nucleus is hyperchromatic and located in the center of the cell (fig. 279). Occasionally, the nucleus is bilobed, indented, or elongated. The deeply-staining nuclear membrane encloses 2 to 4 pale or faintly acidophilic nucleoli, dense chromatin bars, and a fine linin meshwork. Ten to 20 mitotic figures, generally bizarre in form, may be found in every high power field. Many large areas of necrosis occur in the center as well as in the periphery of the tumor, but tumor cells seem to survive around the blood vessels in these areas. The tumor provokes little inflammatory reaction at its periphery.

A regressing Brown-Pearce Tumor is accompanied by a rather characteristic histologic picture in the tissues at the site of inoculation. This change was described by Appel and associates, who transplanted the tumor into the testis and then induced regression of this transplant by a second inoculation of tumor tissue into the skin at another site. Degeneration and necrosis were first noted in the central area of the tumor. Neoplastic cells apparently remained viable at the periphery of the tumor for a longer period of time. This outer marginal area became infiltrated with lymphocytes, granulocytes, endothelial cells, and foreign body giant cells. There was also formation of giant tumor cells. Calcareous deposits were found in the nuclei of these cells and also in other parts of the regressing transplant. These findings were confirmed in regressing tumors studied at the National Cancer Institute. A large amount of iron pig-

ment was found deposited in the marginal zone of the tumor. Accumulations of large lipoid-containing cells and foreign body giant cells with central calcification were also frequently observed.

IMMUNITY STUDIES. The use of the Brown-Pearce Tumor in studies relating to tumor immunity has been summarized by G. D. Snell. Kidd has shown that the Brown-Pearce Tumor tissue contains an antigen that induces an antibody in the blood of certain rabbits that have been inoculated with the tumor. This antibody can be demonstrated in complement fixation tests in which extracts of the tumor tissue are used as antigen. The antibody also suppressed the growth of Brown-Pearce Tumor cells under a variety of experimental conditions. Furthermore, in the presence of complement, the antibody brought about striking and distinctive morphologic changes and a rapid loss of viability in Brown-Pearce Tumor cells in vitro.

Antisera produced by growth or regression of the Brown-Pearce Tumor sometimes, though not always, reacted with extracts of various normal tissues of the rabbit as well as with extracts of the Brown-Pearce Tumor. By absorption of antisera with normal tissue and with Brown-Pearce Tumor tissue extracts, it was shown that either or both of two different antibodies could be present. These antibodies were: (1) an induced tissue antibody that reacted with both normal tissue and Brown-Pearce Tumor tissue extracts; and (2) a specific Brown-Pearce Tumor antibody that reacted with Brown-Pearce Tumor tissue extract only. There was some indication that the genetic constitution of the host was a factor in determining which antibodies were formed. Many Blue Cross rabbits and all of a small group of chocolate Dutch hybrid rabbits produced only the Brown-Pearce antibody. Other breeds of rabbits, if they produced antibody at all, regularly produced both types. In further tests, it was shown that the Brown-Pearce antibody could be induced in many Blue Cross rabbits by the intra-abdominal injection of cell-free extracts of the tumor. Occasionally, the induced normal tissue antibody was present also. Rabbits of other breeds were tested but failed to produce antibodies following injection of the extract. (Many of these data were kindly contributed by Dr. J. G. Kidd of Cornell Medical College, New York, N. Y.)

References

Appel, M., Saphir, O., and Strauss, A. A. Morphologic alterations in the regressing Brown-Pearce tumor and their relation to changes due to irradiation. Arch. Path., 31:317–325, 1941.

Brown, W. H., and Pearce, L. Studies based on a malignant tumor of the rabbit. I. The spontaneous tumor and associated abnormalities. J. Exper. Med., 37:601–629, 1923.

_____, and Pearce, L. Studies based on a malignant tumor of the rabbit. III. Intratesticular transplantation and clinical course of the disease. J. Exper. Med., 37:799–810, 1923.

Casey, A. E. Experimental enhancement of malignancy in the Brown-Pearce rabbit tumor. Proc. Soc. Exper. Biol. & Med., 29:816–818, 1932.

_____. Distribution of metastases in the Brown-Pearce tumor. I. In standard breeds of rabbits. Proc. Soc. Exper. Biol. & Med., 40:223–228, 1939.

BROWN-PEARCE TUMOR. RABBIT

(Histologic sections courtesy of Dr. T. B. Dunn, National Cancer Institute, Bethesda, Md.)

Figure 277. Photomicrograph of transplant tumor. The peripheral aspect of the tumor shows the medullary character of the growth and the incomplete encapsulation. Hematoxylin and eosin stain. X 92. N. C. I. 8983; A. F. I. P. Acc. No. 219934–278.

Figure 278. Photomicrograph of transplant tumor. A section of the viable portion of the tumor. The neoplastic cells are closely packed in thick cords that are separated from each other by a small amount of connective tissue stroma. Hematoxylin and eosin stain. X 240. N. C. I. 8949; A. F. I. P. Acc. No. 219934–279.

Figure 279. Photomicrograph of transplant tumor. The cells of the tumor are round or oval with a large centrally located basophilic nucleus. Note the mitotic figures. Hematoxylin and eosin stain. X 740. N. C. I. 8990; A. F. I. P. Acc. No. 219934–280.

Figure 280. Photomicrograph of transplant tumor. Only a few reticular fibers are present, and these are confined to the sparse connective tissue stroma. Wilder's silver preparation. X 375. N. C. I. 8953; A. F. I. P. Acc. No. 219934–281.

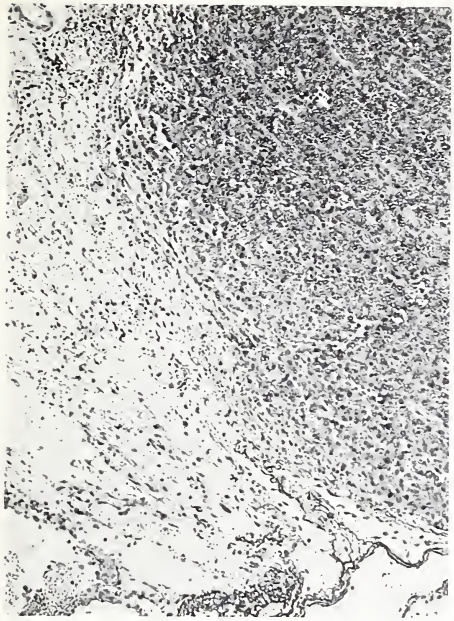

Fig. 277

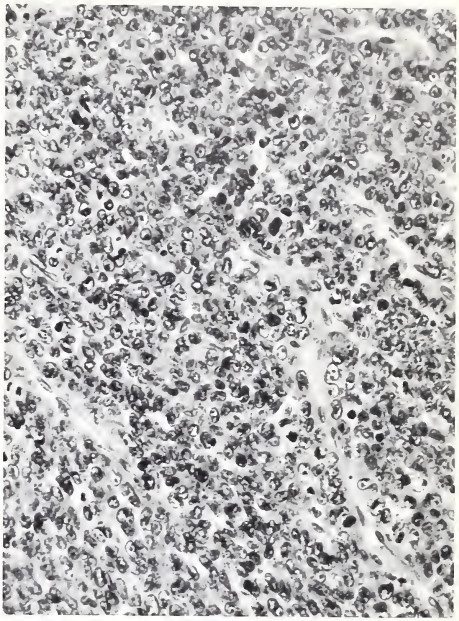

Fig. 278

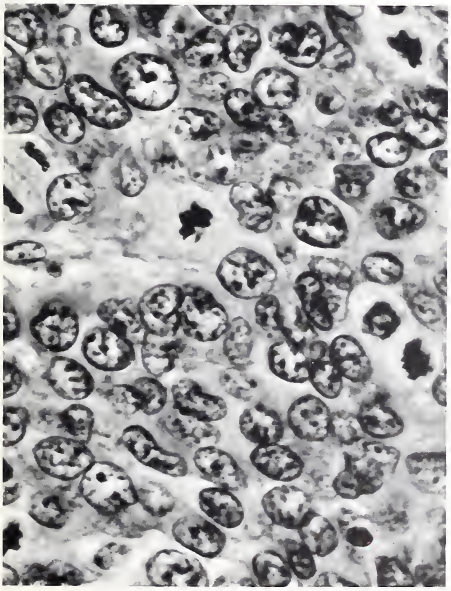

Fig. 279

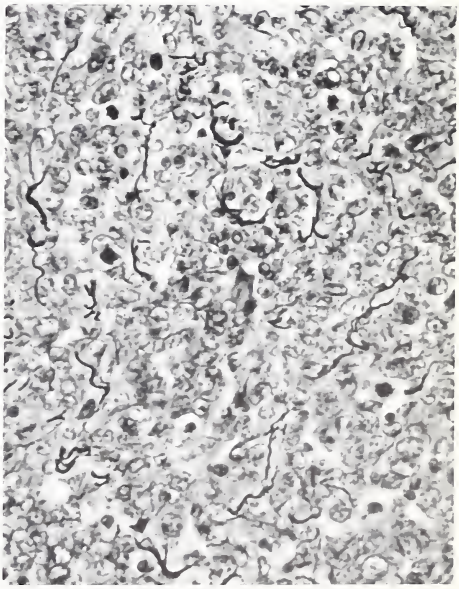

Fig. 280

———. Distribution of metastases in the Brown-Pearce tumor. II. Effect of fifteen years of transplantation. Proc. Soc. Exper. Biol. & Med., 40:228–230, 1939.

Friedewald, W. F., and Kidd, J. G. Induced antibodies that react in vitro with sedimentable constituents of normal and neoplastic tissue cells. Presence of the antibodies in the blood of rabbits carrying various transplanted cancers. J. Exper. Med., 82:21–39, 1945.

Greene, H. S. N. Heterologous transplantation of the Brown-Pearce tumor. Cancer Research, 9: 728–735, 1949.

Kalfayan, B., and Kidd, J. G. Structural changes produced in Brown-Pearce carcinoma cells by means of a specific antibody and complement. J. Exper. Med., 97:145–162, 1953.

Kidd, J. G. Suppression of growth of Brown-Pearce tumor cells by a specific antibody. With a consideration of the nature of the reacting cell constituent. J. Exper. Med., 83:227–250, 1946.

Pearce, L., and Brown, W. H. Studies based on a malignant tumor of the rabbit. II. Primary transplantation and elimination of a coexisting syphilitic infection. J. Exper. Med., 37:631–645, 1923.

———, and Brown, W. H. Studies based on a malignant tumor of the rabbit. IV. The results of miscellaneous methods of transplantation, with a discussion of factors influencing transplantation in general. J. Exper. Med., 37:811–828, 1923.

———, and Brown, W. H. Studies based on a malignant tumor of the rabbit. V. Metastases. Part 1. Description of the lesions with especial reference to their occurrence and distribution. Part 2. Description of the lesions with especial reference to their occurrence and distribution. Part 3. Factors that influence occurrence and distribution. J. Exper. Med., 38:347–366; 367–383; 385–405, 1923.

Snell, G. D. Transplantable tumors. In: Homburger, F., and Fishman, W. H., (eds.). The Physiopathology of Cancer, pp. 338–391. New York: Paul B. Hoeber, Inc., 1953.

Venereal Tumor. Dog

SYNONYMS: Infectious sarcoma; infectious lymphosarcoma; transmissible lymphosarcoma; venereal lymphosarcoma; canine condyloma; histiocytoma; Sticker's sarcoma; myxosarcoma.

DEFINITION. An undifferentiated neoplasm of the dog usually acquired in nature by coitus and transferable by means of living cells only.

INCIDENCE. The Venereal Tumor of the dog appears to have a worldwide distribution. As reported by Karlson and Mann, there is a variation in the incidence in different parts of the United States. A veterinarian in Texas stated that 11 percent of 100 consecutive canine tumors were of this type, and in a veterinary clinic in Evanston, Illinois, the venereal tumor was found to be second in incidence to the mammary tumor. It is apparently rare in Iowa, Ohio, Kansas, Michigan, and Minnesota, and the number of cases in New York City and Philadelphia has decreased since the early part of the century. The naturally occurring disease is more frequent in female dogs and reaches its peak incidence during the years of greatest sexual activity.

HISTORY AND TRANSPLANTATION STUDIES. The Venereal Tumor of the dog is the oldest transplantable tumor known. It is disseminated under natural conditions through physical contact, usually during coitus, but occasionally by licking the genitalia or through open wounds. Since no microbiological agent has been demonstrated as the causative factor, its dissemination

in nature and its transplantation in the laboratory apparently depend upon the inoculation of viable tumor cells.

The first successful experimental transplantation of this tumor was accomplished by M. A. Novinsky (fig. 281), a veterinarian who obtained his degree from the Medical-Surgical Academy in St. Petersburg in 1877. Novinsky's work represents the first recorded successful experimental transplantation of tumors from animal to animal in the laboratory, and on the basis of this priority, Shabad has referred to him as the "Forefather of Experimental Oncology." Novinsky stressed the importance of selecting bits of viable tumor for inoculation through a short skin incision into a host closely related to the donor animal. These conditions were determined as a result of two successes and 44 failures to transplant cancer from dog to dog and horse to horse. In the second of the two successful experiments, the cancer transplanted was undoubtedly the Venereal Tumor of the dog. In the first experiment, however, Novinsky may not have been dealing with an extragenital venereal tumor as has often been assumed, but instead with an anaplastic cancer of the nose of a dog. This first experiment details the passage of a malignant neoplasm through two generations of transplantation, and it was the subject of preliminary reports published in 1876. A full account of the two experiments was published the following year in a thesis entitled "On the Question of the Inoculation of Malignant Neoplasms" (fig. 282). Shimkin has recently studied Novinsky's thesis and brings to light many facts hitherto inaccurately recorded by writers who had consulted only the preliminary reports. In view of the historical importance of Novinsky's work, it seems desirable to quote directly from Shimkin's review (p. 653) in which details of both successful experiments are given.

"On December 14, 1875, a 4-year-old female dog was obtained with an invasive tumor of the nose that histologically was considered to be a small-celled carcinoma ('carcinoma medullare parvicellulare'). The animal died two months later, and autopsy revealed extensive local invasion, with destruction of bone and multiple pulmonary metastases.

"Small (2 to 5 mm.) fragments of the tumor from the nose were inoculated on December 19, 1875, into bilateral skin incisions over the chest wall of a month-old puppy. The wounds healed in a few days. A nodule in the left scar grew slowly until February 25, 1876, when it ulcerated. Fragments of the mass were inoculated into three puppies. The mass grew progressively to the size of a walnut and became fixed. The animal was killed on May 4. Autopsy revealed that the tumor was locally invasive and that an unmistakable metastasis was present in an enlarged left axillary lymph node. The histological appearance of the transplant and of the metastasis was the same as that of the original neoplasm.

"Two of the three puppies inoculated with this transplanted tumor on February 25 had the fragments removed at five-day intervals for histological

studies. One puppy was left for longer observation. After healing of the initial incision, a nodule appeared in the scar in three weeks, which grew slowly but progressively to a size of a hazel nut and ulcerated a few days before the dog's death from distemper on April 9. The histological appearance of the tumor . . . was the same as of the original neoplasm. Invasion was limited to the subcutaneous tissue and there were no metastases. . . .

"The second successful series starts on September 20, 1876, when a 6-year-old female dog was obtained with a sloughing tumor of the uterus and vaginal vault. The histological diagnosis of the tumor was 'medullary myxosarcoma.' Novinsky stresses the point that this tumor was entirely distinct in appearance from the neoplasm of the previous series.

"Fresh fragments of the tumor were inoculated into bilateral skin incisions of two puppies on September 23 and September 29. A month later nodules appeared at the site of inoculation, which grew slowly but progressively. One tumor site sloughed out after two months, but each animal had a tumor, one the size of a hen's egg, when they were killed four to five months after transplantation. The histological structure resembled the original tumor, although the cells of the transplants displayed considerably more 'fatty metamorphosis.' An illustration of one of these transplants . . . shows areolar tissue being invaded by cells that are hard to distinguish from those of the first neoplasm.

"Biopsy was done on one of the first-passage tumors two months after inoculation, and the tissue reinoculated into two skin incisions of a 2-month-old dog. The wounds healed, and two months later a nodule appeared in each scar. These grew to the size of large hazel nuts during the next six weeks, and one then ulcerated. The dog was killed four months after transplantation. The tumors were of the same histological appearance as the first transplant. No metastases were detected." (Our figures 283A and 283B are also from Novinsky's original thesis.)

Wehr, in 1888, reported the successful transplantation of seven venereal tumors in a series of 24 dogs. In one animal, necropsied at the end of a year, the tumor had metastasized to the abdominal organs. Since that time the transplantability of this tumor has been repeatedly confirmed. It has been transplanted by the subcutaneous, intraperitoneal, and intravenous routes. The naturally occurring tumor and that established by artificial transfer both tend to regress. After a tumor has regressed spontaneously or has been removed surgically, the animal is resistant to subsequent inoculation with tumor tissue. The fox is the only animal other than the dog into which the tumor has been successfully transplanted. Attempts by Sticker to transplant it to cats, guinea pigs, rats, mice, and rabbits failed.

In 1934 Stubbs and Furth found that inoculation was successful in 72 percent of dogs receiving a subcutaneous injection of an emulsion of tumor cells. With one exception, the transplanted tumor began to regress after reaching a diameter of about 10 cm. However, the tumor of one dog metasta-

sized widely. Intravenous inoculation of tumor cells produced sarcomatosis in 2 of 7 animals. Transmission was also successful when tumor tissue was rubbed into the scarified surface of the glans penis. Attempts to transmit the disease through the intact mucous membrane of the conjunctiva were unsuccessful.

Karlson and Mann described an experiment in which the neoplasm was passed through 40 tumor transplant generations using 62 groups of recipient dogs totaling 601 animals. Thirty-seven dogs (6 percent) died during the latent period with no detectable tumors. Of the remaining 564 inoculated dogs, 385 (68 percent) developed palpable tumors at the site of inoculation. The percentage of successful transplants varied widely from generation to generation. In some transplant generations the tumor grew in only 30 percent of the host dogs, while in other generations it grew successfully in 95 percent. The earliest appearance of palpable tumors, noted in two dogs, was 15 days after inoculation. Thirty-seven percent of the dogs developed palpable tumors within 30 days, and 88.7 percent within 60 days after inoculation. More than half of the host dogs that had developed tumors recovered spontaneously within 80 days, and only 13 percent of the dogs retained their transplant tumor longer than six months. Seventeen percent of tumors persisted less than 41 days. Only five animals of the entire group had any evidence of metastatic growths.

CLINICAL DESCRIPTION. In the male dog, the clinical manifestations of the disease vary depending upon the extent of involvement of the penis, the presence of metastases in the inguinal lymph nodes, and the age of the tumor. Early in the disease, there may be signs of local cutaneous irritation with serous or sanguineous discharge. The glans penis reveals one or more small, firm, red nodules. As these enlarge, necrosis, ulceration, and bleeding occur. The tumor often has a cauliflower appearance and may attain a diameter of 5 cm. (fig. 284). In the female, one or more small reddish nodules may appear on the mucosa of the vagina. Such nodules vary in diameter from a few millimeters to large, irregularly shaped, ulcerated masses that protrude from the vulva. It is the observation of most veterinarians that the health of the affected animal is not seriously impaired unless the tumor has become necrotic and infected or has occluded the urethral orifice. Metastases are rare, but if present, they are usually confined to the regional lymph nodes.

PATHOLOGIC DESCRIPTION. The tumor in the naturally acquired disease is composed of rather soft, elastic, confluent nodules that, upon section, are light pink and exude viscous fluid. Old regressing lesions are firmer and contain more fibrous tissue. The majority of the tumors are surrounded by a capsule of connective tissue; others invade the surrounding areolar tissue and muscle.

When the tumor is transplanted to other dogs by inoculating them subcutaneously with tissue fragments, the growth may remain as a solitary nodule.

More rarely it may spread to form other subcutaneous tumors and may metastasize to the regional lymph nodes or to distant sites. With intraperitoneal inoculation, multiple small tumors develop within two months. These may coalesce to form a confluent mass, 10 to 15 cm. in diameter, and there may be spread to the pleura and the tunica vaginalis.

The histopathologic characteristics of the naturally acquired and the experimentally induced disease are similar. The tumor tissue is composed of fairly uniform round or polygonal cells, 9 to 12 microns in diameter, closely packed together, or arranged in sheets or cords (fig. 285). The peripheral limits of the cell are indistinct when stained with hematoxylin and eosin, but they are sharply outlined when colored by phosphotungstic acid—hematoxylin or by the periodic acid—Schiff method (fig. 286). The large amount of cytoplasm is clear, smooth, or granular, and may be faintly basophilic. The cell usually possesses one large, round or oval, eccentrically placed nucleus, containing clumps of chromatin, a delicate linin network, and a faintly acidophilic ovoid nucleolus. Two to 10 mitotic figures are found in every high power field, and they are regular in form. The tumor cells are supported by very little stroma, consisting of thin strands of connective tissue, that in many instances surround a blood vessel of capillary size. A rather vascular stroma may form trabeculae, producing in some cases an alveolar pattern. Thin fibrils of reticulum surround groups of cells (fig. 287). A few inflammatory cells of different types are present throughout the tumor. Necrosis is common even in small tumors and may be extensive in large growths.

References

Bloom, F., Paff, G. H., and Noback, C. R. The transmissible venereal tumor of the dog. Studies indicating that the tumor cells are mature end cells of reticulo-endothelial origin. Am. J. Path., 27:119–139, 1951.

Feldman, W. H. Neoplasms of Domesticated Animals, chap. 20, p. 356. Philadelphia: W. B. Saunders Co., 1932.

Karlson, A. G., and Mann, F. C. The transmissible venereal tumors of dogs: observations of forty generations of experimental transfers. In: Viruses as Causative Agents in Cancer. Ann. New York Acad. Sc., 54 (art. 6):1197–1213, 1952.

Novinsky, M. K voprosu o privivanii zlokachestvennich novoobrazovanii (experimentalnoi issledovanie). [On the question of the inoculation of malignant neoplasms (experimental investigations).] [Thesis.] St. Petersburg, 1877.

_____. Zur Frage über die Impfung der krebsigen Geschwülste. Centralbl. f. d. med. Wissensch., 14:790–791, 1876.

Shabad, L. M. M. A. Novinsky, rodonachal nik experimentalnoi onkologii. [M. A. Novinsky, forefather of experimental oncology.] Moscow Acad. Med. Nauk USSR, 1950.

Shimkin, M. B. M. A. Novinsky: A note on the history of transplantation of tumors. Cancer, 8: 653–655, 1955.

Sticker, A. Transplantables Lymphosarkom des Hundes. Ein Beitrag zur Lehre der Krebsübertragbarkeit. Ztsch. f. Krebsforsch., 1:413–444, 1904.

Stubbs, E. L., and Furth, J. Experimental studies on venereal sarcoma of the dog. Am. J. Path., 10:275–286, 1934.

Wehr. Demonstration der durch Impfung von Hund auf Hund erzeugten Carcinominknötchen. Zentralbl. f. Chir., 15 (suppl. to No. 24):8, 1888.

_____. Weitere Mittheilungen über die positiven Ergebnisse der Carcinom-Ueberimpfungen von Hund auf Hund. Arch. f. klin. Chir., 39:226–228, 1889.

HISTORICAL DATA FROM RECORD OF FIRST TRANSPLANTATION OF VENEREAL TUMOR OF THE DOG

Figure 281. M. A. Novinsky, 1841–1914. (Courtesy of Dr. M. B. Shimkin). A. F. I. P. Acc. No. 219934-282.

Figure 282. Title page of Novinsky's 1877 thesis: "On the Question of the Inoculation of Malignant Neoplasms." (Courtesy of Dr. M. B. Shimkin). A. F. I. P. Acc. No. 219934-283.

Figure 283.* Drawings of transplanted tumors from Novinsky's thesis. Figure A, diagnosed as medullary carcinoma, is of the 2nd generation transplant in the first series. Figure B, diagnosed as myxosarcoma, is of the 1st transplant of the second series. A. F. I. P. Acc. Nos. 219934-284 and 285.

---

*From Shimkin, M. B. M. A. Novinsky: A note on the history of transplantation of tumors. Cancer, 8:653-655, 1955. Figure 1 is our figure 283 (A and B).

Fig. 281

КЪ ВОПРОСУ

О ПРИВИВАНІИ

ЗЛОКАЧЕСТВЕННЫХЪ НОВООБРАЗОВАНІЙ.

(ЭКСПЕРИМЕНТАЛЬНОЕ ИЗСЛѢДОВАНІЕ).

ДИССЕРТАЦІЯ

НА СТЕПЕНЬ МАГИСТРА ВЕТЕРИНАРНЫХЪ НАУКЪ

Мстислава Новинскаго.

САНКТПЕТЕРБУРГЪ.
ТИПОГРАФІЯ ЯКОВА ТРЕЯ.
Разъѣзжая, № 51.
1877.

Fig. 282

Fig. 283 A

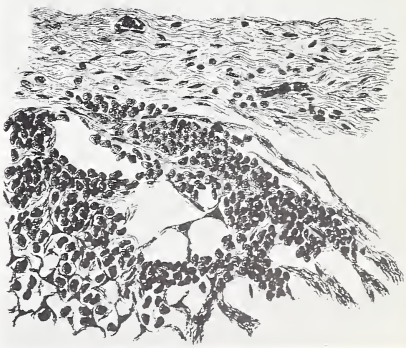

Fig. 283 B

VENEREAL TUMOR. DOG

(Histologic sections courtesy of Dr. W. H. Eyestone, National Cancer Institute, Bethesda, Md.)

Figure 284. Gross photograph of a naturally acquired venereal tumor on the penis of an 8-year-old cocker spaniel. A left inguinal lymph node was enlarged. The large mass at the end of the penis was firm and red and measured 2 cm. in diameter. Two small firm red nodules, one of which is shown, were present on the shaft of the penis. (This is figure 1 in Karlson, A. G., and Mann, F. C. The transmissible venereal tumor of dogs: observations of forty generations of experimental transfers. Ann. New York Acad. Sc., 54 [art. 6]:1197–1213, 1952.) N. C. I. 9352; A. F. I. P. Acc. No. 219934–286.

Figure 285. Photomicrograph of naturally acquired lesion showing the uniform character of the tumor cells, paucity of stroma, and occasional mitotic figures. Hematoxylin and eosin stain. X 610. N. C. I. 7850; A. F. I. P. Acc. No. 219934–287.

Figure 286. Photomicrograph of naturally acquired lesion. The cytoplasm is abundant, clear, smooth or granular. In this stain, the peripheral limits of the cell are sharply outlined. Phosphotungstic acid—hematoxylin stain. X 670. N. C. I. 9055; A. F. I. P. Acc. No. 219934–288.

Figure 287. Photomicrograph of naturally acquired lesion. Thin reticular fibrils surround groups of tumor cells. Wilder's silver preparation. X 430. N. C. I. 9052; A. F. I. P. Acc. No. 219934–289.

Fig. 284

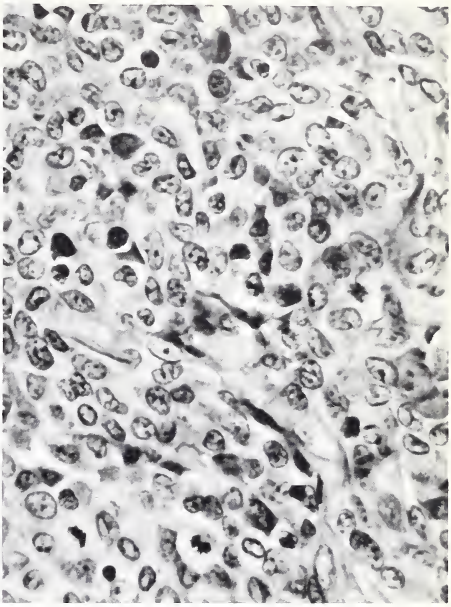

Fig. 285

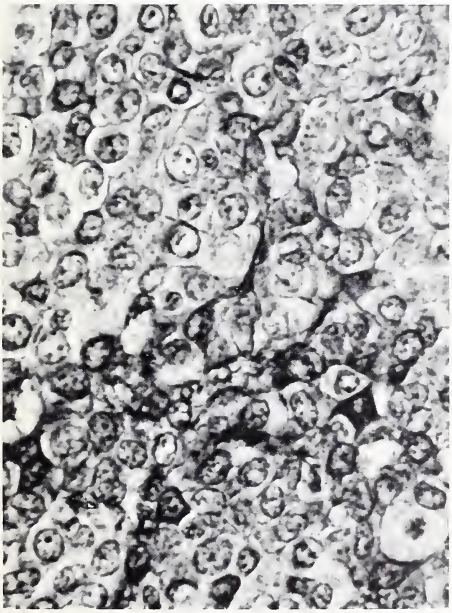

Fig. 286

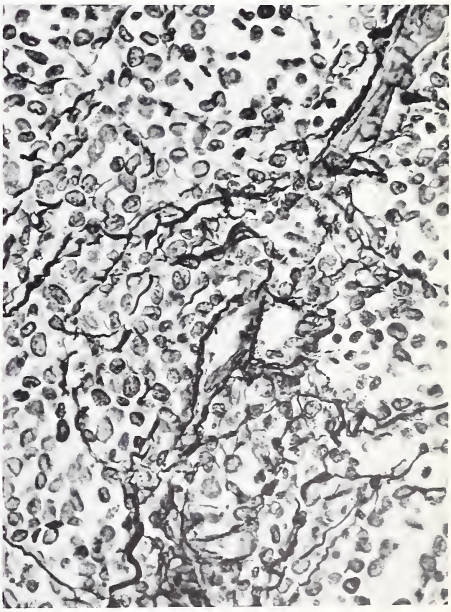

Fig. 287

SUPPLEMENTARY CLASSIFICATIONS

A classification of animal tumors was published in 1953 by Dunham and Stewart.* With minor changes, that classification is repeated, and the tumors described in this fascicle are placed in their appropriate places. Representatives of all the various types of animal tumors provided for in the classification are not, however, to be found in the 50 tumors of this fascicle. Forty-two of the 50 tumors have been arranged in this table according to the histologic appearance and tissue of origin of the primary growth. Tumors that have become anaplastic upon repeated transplantation have been classified on the basis of the histologic pattern and site of origin of the primary tumor regardless of the appearance of the tumor of the current transplant generation. We have added category VII, because after studying all information available to us we have found that there are eight tumors which cannot be definitely classified as to site or tissue of origin. A detailed description of the histologic characteristics and site of origin of the primary Ehrlich Tumor of the mouse, for example, was never made. A careful necropsy was made on the rabbit bearing the primary growth of the Brown-Pearce Tumor and a detailed protocol was published, but it has not been possible for us to assign the tumor to a specific site of origin or to a specific histologic category. The Crocker Tumor 180 has been included in group VII because there is no published description of the primary growth, and we have not had access to histologic sections and the necropsy protocol. For similar reasons the other five tumors are listed in group VII.

CLASSIFICATION OF TUMORS OF ANIMALS ACCORDING TO SITE OF ORIGIN AND HISTOLOGY

I. TUMORS OF EPITHELIAL TISSUE

A. Tumors presumably of glandular origin with presumptive sites of origin in mammary gland, glandular stomach, salivary gland, liver, pancreas, kidney, adrenal gland, thyroid gland, pituitary gland, ovary, seminal vesicle, sebaceous gland, and harderian gland.

Page

Adrenal Cortical Carcinoma WK1546. Mouse 272

Bashford Carcinoma 63 (mammary gland). Mouse 239

Carcinoma #1 (thyroid gland). Dog 293

*Dunham, L. J., and Stewart, H. L. A survey of transplantable and transmissible animal tumors. J. Nat. Cancer Inst., 13:1299–1377, 1953.

I. TUMORS OF EPITHELIAL TISSUE—Continued

A. Tumors presumably of glandular origin, etc.—Continued — Page

Gastric Adenocarcinoma 303. Mouse 167
Gastric Adenocarcinoma 328. Mouse 171
Gastric Carcinoma 342. Rat 179
Hepatoma 98/15. Mouse 200
Mammary Adenocarcinoma R2426. Rat 260
Mammary Adenocarcinoma C3HBA. Mouse 238
Furth Pituitary Tumor. Mouse 275
Renal Adenocarcinoma. Frog 208
Sarcoma 37 (mammary gland). Mouse 243

B. Tumors of a postulated but unconfirmed glandular origin. These are pulmonary, ovarian granulosa-cell and lutein-cell, and testicular interstitial-cell tumors.

Leydig-cell Tumor. Mouse 218
Granulosa-cell Tumor XIV. Mouse 222
Luteoma IX. Mouse 236
Pulmonary Adenocarcinoma C4461. Mouse 139

C. Tumors of nonglandular epithelial origin, with presumptive site of origin in the skin, the forestomach, and the uterine cervix.

Shope Papilloma (skin). Rabbit 30
Squamous-cell Carcinoma G8755 (forestomach). Mouse 161
V2 Carcinoma (skin). Rabbit 38

II. LYMPHOMAS AND LEUKEMIAS

A. Lymphosarcoma or lymphocytic leukemia, or both, with neoplastic involvement of organs and tissues, or leukemic blood, or both, in most instances.

Leukemia Line I. Mouse 103
Murphy-Sturm Lymphosarcoma. Rat 113

B. Myelocytic leukemia (including chloroleukemia)

Chloroleukemia 123, Shay. Rat 101

C. Reticulum-cell Sarcoma

Reticulum-cell Sarcoma 8469. Mouse 131

D. Plasma-cell Tumor

E. Lymphoid tumors and erythrogranuloblastosis of fowls

Lymphoid Tumor RPL–16. Chicken 121

III. TUMORS OF CONNECTIVE TISSUES

A. Tumors presumably of connective tissue origin and of specific cell type such as fibrous tissue, fat, muscle, bone, and vascular tissue.

Earle L Fibrosarcoma (subcutaneous tissue). Mouse 57
Hemangioendothelioma H6221 (epididymis). Mouse 301

III. TUMORS OF CONNECTIVE TISSUES—Continued

A. Tumors presumably of connective tissue origin, etc.—Continued — Page

Liposarcoma D4888 (subcutaneous tissue). Guinea Pig 65
Osteogenic Sarcoma EM2 (sternum). Mouse 92
Osteogenic Sarcoma 344 (glandular stomach). Rat 187
Rhabdomyosarcoma H6668 (chest wall). Mouse 83
Rous Sarcoma (pectoral muscles). Chicken 74

B. Tumors presumably of connective tissue origin and of cell type not specified otherwise than as "mixed cell," "pleomorphic," "round cell," "fusiform cell," "spindle cell," "anaplastic," "undifferentiated," or "sarcoma."

IV. TUMORS OF MELANIN-FORMING TISSUE

Cloudman Melanoma S91 (base of tail). Mouse 43
Harding-Passey Melanoma (ear). Mouse 51

V. TUMORS OF NEURAL TISSUE

Astrocytoma C3H(18) (brain). Mouse 308
Ependymoma A(22) (brain). Mouse 312

VI. TUMORS COMPOSED OF MIXED TISSUES

A. Tumors composed of mixed epithelial tissues or mixed connective tissues or both.

Flexner-Jobling Carcinosarcoma (seminal vesicle). Rat 341
Mammary Fibroadenoma R2737. Rat 249
Myoepithelioma HD (parotid gland). Mouse 143
Myofibrosarcoma HS–6 (subcutaneous tissue). Hamster 62
Parotid Gland Tumor L7205. Mouse 145
Walker Carcinosarcoma 256 (mammary gland). Rat 261

B. Teratomas

Teratoma E6496 (ovary). Mouse 230

VII. TUMORS NOT CLASSIFIED ELSEWHERE

Tumors that have unestablished sites of origin and that may be undifferentiated, pleomorphic, or anaplastic.

Brown-Pearce Tumor. Rabbit 355
Crocker Tumor 180. Mouse 324
Ehrlich Tumor. Mouse 317
Jensen Sarcoma. Rat 348
Krebs 2 Tumor. Mouse 330
Tumor C–1300. Mouse 336
Venereal Tumor. Dog 364
Yoshida Tumor. Rat 352

CLASSIFICATION OF TUMORS ACCORDING TO ANIMAL HOST

I. TUMORS OF THE MOUSE

	Page
Adrenal Cortical Carcinoma WK1546	272
Astrocytoma C3H(18)	308
Bashford Carcinoma 63	239
Cloudman Melanoma S91	43
Crocker Tumor 180	324
Earle L Fibrosarcoma	57
Ehrlich Tumor	317
Ependymoma A(22)	312
Furth Pituitary Tumor	275
Gastric Adenocarcinoma 303	167
Gastric Adenocarcinoma 328	171
Granulosa-cell Tumor XIV	222
Harding-Passey Melanoma	51
Hemangioendothelioma H6221	301
Hepatoma 98/15	200
Krebs 2 Tumor	330
Leukemia Line I	103
Leydig-cell Tumor	218
Luteoma IX	226
Mammary Adenocarcinoma C3HBA	238
Myoepithelioma HD	143
Osteogenic Sarcoma EM2	92
Parotid Gland Tumor L7205	145
Pulmonary Adenocarcinoma C4461	139
Reticulum-cell Sarcoma 8469	131
Rhabdomyosarcoma H6668	83
Sarcoma 37	243
Squamous-cell Carcinoma G8755	161
Teratoma E6496	230
Tumor C–1300	336

II. TUMORS OF THE RAT

Chloroleukemia 123, Shay	101
Flexner-Jobling Carcinosarcoma	341
Gastric Carcinoma 342	179
Jensen Sarcoma	348
Mammary Adenocarcinoma R2426	260
Mammary Fibroadenoma R2737	249
Murphy-Sturm Lymphosarcoma	113
Osteogenic Sarcoma 344	187
Walker Carcinosarcoma 256	261
Yoshida Tumor	352

	Page
III. TUMORS OF THE THE RABBIT	
Brown-Pearce Tumor	355
Shope Papilloma	30
V2 Carcinoma	38
IV. TUMORS OF THE DOG	
Carcinoma #1	293
Venereal Tumor	364
V. TUMORS OF THE CHICKEN	
Lymphoid Tumor RPL–16	121
Rous Sarcoma	74
VI. TUMOR OF THE HAMSTER	
Myofibrosarcoma HS–6	62
VII. TUMOR OF THE GUINEA PIG	
Liposarcoma D4888	65
VIII. TUMOR OF THE FROG	
Renal Adenocarcinoma	208

Army – AFIP – Washington, D. C.

PROFESSIONAL NOTES AND FINDINGS

PROFESSIONAL NOTES AND FINDINGS

AUG 3 1 1960
JAN 24 '61
JAN 25 '61

Library
National Institutes of Health
Bethesda 14, Maryland

DATE DUE

NIH LIB SEP 3 1974
AUG 15 1977

GAYLORD PRINTED IN U.S.A.

LIB
Amazin
Amazin
http://nihlibrary.nih.gov

10 Center Drive
Bethesda, MD 20892-1150
301-496-1080

NIH LIBRARY
6 4 0087 8439

BOUND BY HNM

NIH LIBRARY
3 1496 00198 2605

OCT 2 1967

DEC 28 2005